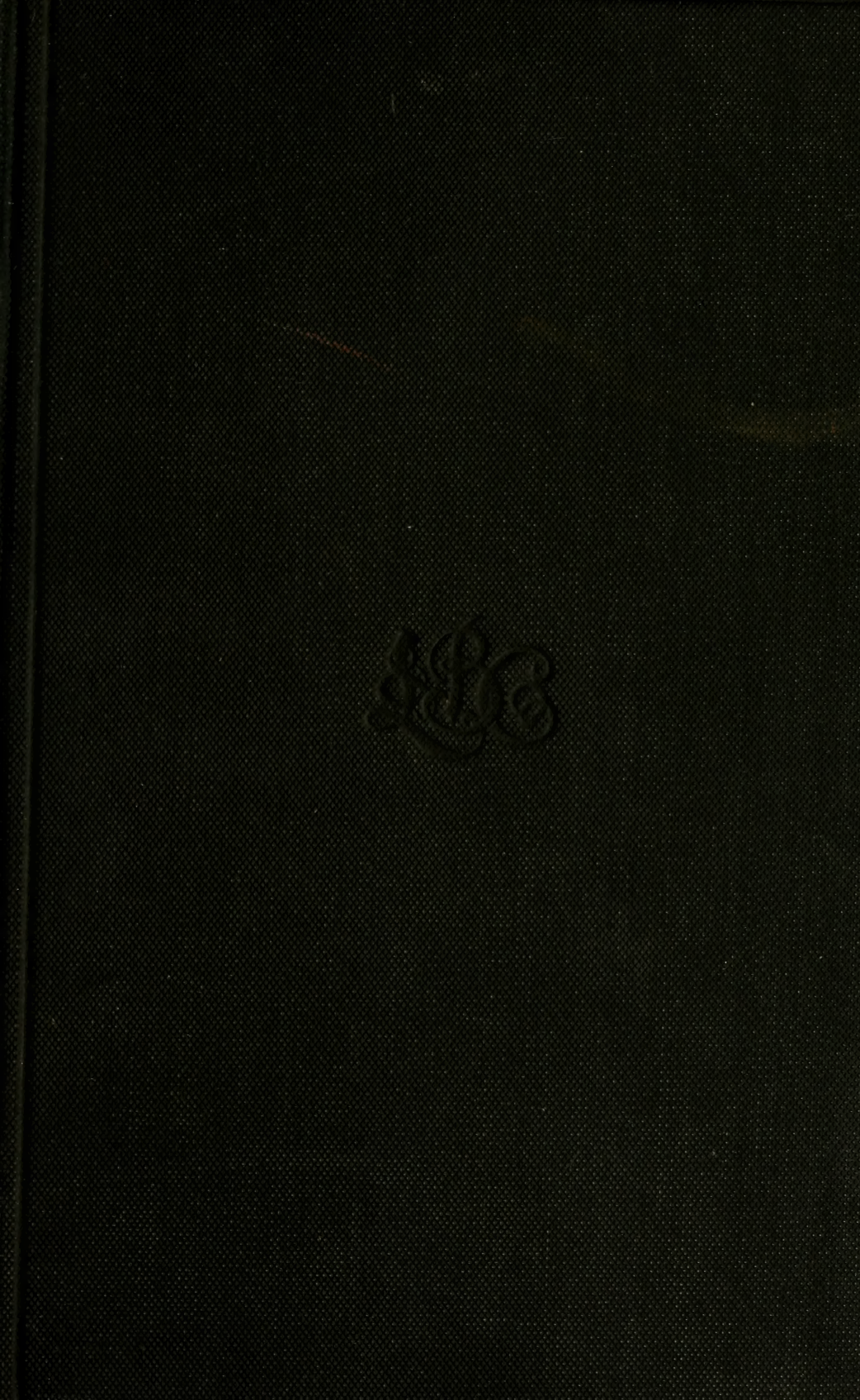

THE LIBRARY OF CONGRESS

THE LIBRARY OF CONGRESS

THE

DIAGNOSIS

OF

DISEASES OF WOMEN.

A TREATISE FOR STUDENTS AND PRACTITIONERS.

BY

PALMER FINDLEY, B.S., M.D.,

INSTRUCTOR IN OBSTETRICS AND GYNECOLOGY, RUSH MEDICAL COLLEGE IN AFFILIATION WITH THE UNIVERSITY OF CHICAGO; ASSISTANT ATTENDING GYNECOLOGIST TO THE PRESBYTERIAN HOSPITAL, CHICAGO.

ILLUSTRATED WITH 210 ENGRAVINGS IN THE TEXT AND 45 PLATES IN COLORS AND MONOCHROME.

LEA BROTHERS & CO.,

PHILADELPHIA AND NEW YORK.

1903.

THE LIBRARY OF
CONGRESS,
Two Copies Received
MAY 5 1903
Copyright Entry
May 5-1903
CLASS a XXc. No.
58938
COPY B.

RG106
.F48
RG107
.F48

Entered according to the Act of Congress, in the year 1903, by
LEA BROTHERS & CO.,
In the Office of the Librarian of Congress. All rights reserved.

10
4215

DORNAN, PRINTER.

IN

FILIAL AFFECTION

FOR

DAVID FINDLEY, M.D.,

AND AS A TRIBUTE TO THE ACHIEVEMENTS
IN GYNECOLOGY AND OBSTETRICS

OF

J. CLARENCE WEBSTER, A.M., M.D., F.R.S.E., F.R.C.P.,

THIS BOOK IS

DEDICATED.

PREFACE.

It has been the endeavor of the author to write a work on the Diagnosis of Diseases of Women that will be equally adapted to the needs of student and practitioner, and in line with the most modern views. The recognition of the pathology of the pelvic organs in large measure constitutes a diagnosis. Because of this fundamental fact the author has deemed it desirable to incorporate a thorough discussion of the morbid anatomy, both macroscopic and microscopic, and to point out its clinical indications. Special stress has been placed upon the microscopic diagnosis of the various lesions, not alone on account of its scientific interest, but also, and more particularly, because of its great clinical importance. Without the microscope a diagnosis is not always possible.

Medical literature in the English language has not hitherto included a work on this subject. In the effort to supply this desideratum the author has aimed to satisfy the requirements of those who have felt the need of more comprehensive and practical information than can be given in the general text-books on gynecology. It is hoped that this work will be serviceable to those who do not have access to foreign literature.

The author desires to express appreciation of the services rendered in the writing of the book. Dr. D. P. Johnson gave invaluable assistance in the critical reading of the manuscript; Dr. Charles G. Farnum in the correction of the proof; Miss Mamie Findley and Dr. Carl Wahrer in the production of illustrations. Indebtedness is also acknowledged to Veit's *Handbuch für Gynäkologie*,

Winter's *Gynäkologische Diagnostik*, Webster's *Ectopic Pregnancy*, Cullen's *Cancer of the Uterus*, Kelly's *Operative Gynecology*, and Dudley's *Gynecology*. The author furthermore desires to express appreciation of his very cordial relations with the publishers, which have at all times been most gratifying.

PALMER FINDLEY.

100 State Street, Chicago, 1903.

CONTENTS.

PART I.

GENERAL DIAGNOSIS.

CHAPTER I.

PAGE

THE CLINICAL HISTORY 17

A Plea for an Early Diagnosis 17
Form of Case Record 19
Address 21
Age 21
Occupation 22
Nationality 22
Social State 22
Number of Children and Miscarriages 22
Family History 23
Previous Illnesses 23
Present Complaints 23
Menstrual History 23
Hemorrhage from the Genital Tract 23
Menstruation 24
Anatomy of Menstruation 26
Menstruating Fallopian Tube 28
Uterine Hemorrhage 28
Systemic Causes 29
Local Causes 29
Amenorrhœa 34
General Causes 34
Local Causes 35
Menstrual Molimena 36
Dysmenorrhœa 36
Idiopathic (Primary) 37
Secondary 37
Membranous 38
Sterility in Women 38
General Causes 40
Local Causes 41

PAGE
Menopause 44
Factors Influencing 44
Leucorrhœa 45
Normal Secretions 45
In Infants 45
In Virgins 45
In Period of Sexual Maturity 46
In Old Women 46

CHAPTER II.

PHYSICAL EXAMINATION 48

Preliminary Measures 48

CHAPTER III.

EXTERNAL ABDOMINAL EXAMINATION. INSPECTION OF THE ABDOMEN . 51

CHAPTER IV.

PALPATION OF THE ABDOMEN 52

CHAPTER V.

PERCUSSION OF THE ABDOMEN 55

CHAPTER VI.

AUSCULTATION AND MENSURATION OF THE ABDOMEN . . 56

CHAPTER VII.

EXAMINATION OF THE EXTERNAL GENITALS . . . 57

Digital Examination of the Internal Genitals 57
Vagina 57
Choice of Hand 59
One or Two Fingers Used? 60
Bimanual Examination 62
Abdomino-vaginal Examination 62
Examination under Narcosis 66
Digital Examination of the Rectum 66
Abdomino-rectal Examination 68
Abdomino-vagino-rectal Examination 69
Digital Examination of the Bladder 69
Pelvimetry 70

CHAPTER VIII.

PAGE

Vaginal Speculum 71

CHAPTER IX.

Vulsella 76

CHAPTER X.

Uterine Dilators 78

CHAPTER XI.

Uterine Sound 82

Preliminary Measures 82
Indications 82
Dangers Involved 84

CHAPTER XII.

Uterine Curette 86

In Diagnosis 86
Contraindications 88
Technic 89

CHAPTER XIII.

Microscopic Examination of Scrapings and Excised Pieces . 91

Removal of Scrapings 91
Test Excision from the Cervix 92
Test Curettage of the Uterus 92
Frozen Sections 92
Fixing the Specimens 95
Hardening and Embedding 95
Method of Staining and Mounting 97
Inspection of the Uterus after Removal 99

CHAPTER XIV.

Exploratory Punctures and Incisions 100

PART II.

SPECIAL DIAGNOSIS.

CHAPTER XV.

PAGE

THE DIAGNOSIS OF PREGNANCY 101

First Trimester 101
I. Subjective Signs 101
1. Cessation of Menstruation 101
2. Morning Sickness 103
3. Salivation 103
4. Nervous Phenomena 104
5. Irritable Bladder 104
II. Objective Signs 104
1. Mammary Glands 104
2. Discoloration of Vulva and Vagina 104
3. Softening of Cervix 104
4. Lower Uterine Segment 106
5. Leucorrhœa 106
6. Change in the Position, Size, Form, and Consistency of Uterus . 107
Second Trimester 107
I. Subjective Signs 107
II. Objective Signs 107
1. Active Fœtal Movements 107
2. Passive Fœtal Movements 107
3. Direct Palpation of the Fœtus 108
4. Intermittent Uterine Contractions 108
5. Auscultation 109
Fœtal Heart Tones 109
Fœtal Souffle 109
Placental Souffle 109
6. Rate of Growth of Uterus 109
7. Changes in Position, Size, Form, and Consistency of Uterus . 110
Third Trimester 110
I. Subjective Signs 110
II. Objective Signs 110
Diagnosis of the Life or Death of the Fœtus 111
Diagnosis of the Time of Pregnancy and Prediction of Date of Confinement . 112
Diagnosis of Multiple Pregnancy 113
Diagnosis of the Causes of Hemorrhage Occurring during Pregnancy . . 113
Diagnosis of Abortion 115
Anatomical Diagnosis of Pregnancy 116

CHAPTER XVI.

MICROSCOPIC DIAGNOSIS OF EXPELLED MEMBRANES FROM THE UTERUS . 120

CHAPTER XVII.

PAGE

The Diagnosis of Ectopic Pregnancy . . . 122

Etiology 122
Classification 123
Retrogressive Changes in the Fœtus 129
Anatomical Changes in the Tube 130
Clinical Diagnosis 132
Subjective Signs 133
Objective Signs 133
Differential Diagnosis 138

CHAPTER XVIII.

Diagnosis of Hydatiform Mole 142

Synonyms 142
History 142
Etiology 142
Microscopic Examination 146
Malignant Degeneration 151
Diagnosis 154

CHAPTER XIX.

Diagnosis of Chorio-epithelioma Malignum . . 160

Etiology 161
Diagnosis 161
Macroscopic Appearance 162

CHAPTER XX.

Diagnosis of Malformations of the Uterus . . 163

Uterus Deficiens 163
Uterus Rudimentarius 163
Uterus Fœtalis 164
Uterus Unicornis 166
Uterus Septus (Bilocularis) 168
Uterus Bicornis 168
Uterus Didelphys 169
Uterus Accessorius 169

CHAPTER XXI.

Diagnosis of Malposition of Uterus and its Neighboring Organs . 171

Pathological Mobility of the Uterus 171
Pathological Fixation of the Uterus 171

PAGE
Anteposition 173
Retroposition 173
Lateroposition 174
Elevatio Uteri 176
Torsion of the Uterus 177
Prolapsus Uteri 178
Inversion of the Uterus 187
Anteversion of the Uterus 193
Anteflexion of the Uterus 194
Retroversio-flexion of the Uterus 195
Hernia of the Uterus (Hysterocele) 203

CHAPTER XXII.

Diagnosis of Diseases of the Vulva 204

Anomalies in Development 204
Vulvitis 206
Circulatory Disturbances 208
Atrophy (Kraurosis Vulvæ) 211
New Formations 213
Ulcers 217
Pruritus Vulvæ 217
Hymen 218

CHAPTER XXIII.

Diagnosis of Diseases of the Vagina 221

Maldevelopments and Malformations 221
Vaginitis (Colpitis) 225
Paravaginitis 229
New Formations 229

CHAPTER XXIV.

Diagnosis of Endometritis 235

Clinical Classification 235
1. Acute Endometritis 235
2. Chronic Endometritis 236
Anatomical Classification 240
I. Macroscopic 240
II. Microscopic 241
Diagnosis of Uterine Scrapings in Endometritis 249
Endocervicitis 249
Erosions of the Cervix 250
Ulcers of the Cervix 254

PAGE
Tuberculosis of the Cervix 254
Chronic Metritis 255

CHAPTER XXV.

Diagnosis of Fibromyoma of the Uterus . . . 256

Etiology 256
Histogenesis 257
Anatomical Diagnosis 258
Microscopic Diagnosis 262
Adenofibromyoma Uteri 264
Degeneration of Fibroids 265
Changes in the Endometrium, Myometrium, Tubes, and Ovaries . . . 268
Clinical Characteristics 268
Clinical Diagnosis 269
Differential Diagnosis 275

CHAPTER XXVI.

The Diagnosis of Carcinoma of the Uterus . . 279

Topographical Classification 279
Etiology 279
Anatomical Diagnosis 281
Clinical Diagnosis 285
Microscopic Diagnosis 289
Differential Diagnosis 296
Diagnosis of Extension 301
Diagnosis of Recurrence 304
Endothelioma 304

CHAPTER XXVII.

The Diagnosis of Sarcoma of the Uterus . . 306

Etiology 306
Anatomical Diagnosis 306
Microscopic Diagnosis 307
Clinical Diagnosis 308

CHAPTER XXVIII.

The Diagnosis of Diseases of the Tubes . . . 310

Methods of Examination 310
Anomalies in the Structure 310
Changes in the Position 311
Circulatory Disturbances 312

PAGE
Inflammations and Infections 313
Granulomata 313
Classification of Salpingitis 314
Catarrhal Salpingitis 314
Salpingitis Isthmica Nodosa 316
Hydrosalpinx 316
Tubo-ovarian Cyst 318
Hæmatosalpinx 318
Purulent Salpingitis 321
Diagnosis of Sactosalpinx 327
Differential Diagnosis of Salpingitis 328
Tuberculous Salpingitis 330
Syphilis of the Fallopian Tube 334
Actinomycosis of the Fallopian Tube 334
Parasites of the Fallopian Tube 334
New Formations of the Fallopian Tube 334

CHAPTER XXIX.

The Diagnosis of the Diseases of the Ovary . . 338

Normal Anatomy 338
Histology 338
Methods of Examination 340
Anomalies in Development 341
Changes in Position 342
Descensus Ovarii 343
Hernia 344
Hypertrophy 345
Atrophy 345
Parasites and Foreign Bodies 346
Circulatory Disturbances 346
Inflammations (Ovaritis) 348
Acute Ovaritis 348
Chronic Ovaritis 349
Cystic Degeneration 350
Abscess 351
Clinical Diagnosis of Ovaritis 352
Differential Diagnosis 354
Simple Cysts 355
Infectious Granulomata 356
Tuberculosis 356
Syphilis 357
Actinomycosis 358
Leprosy 358
New Formations 358
Etiology 358
Classification 359
Carcinoma 364

PAGE

New Formations—
Dermoid Cysts 365
Fibroma 369
Myoma 370
Sarcoma 370
Endothelioma 371
Parovarian Cysts 371
Clinical Diagnosis of New Formations 373
Intraligamentary Development 384
Adherent Tumors 385
Torsion of the Pedicle 385
Rupture of an Ovarian Cyst 388
Leakage of an Ovarian Cyst 388
Hemorrhage into the Cyst 388
Suppuration of the Cyst 389
Malignant Degeneration of the Cyst 389
Ovarian Tumors Complicating Pregnancy 390
Diagnosis of the Variety 390
Fate of Ovarian Tumors 391

CHAPTER XXX.

The Diagnosis of Peritonitis 393

General Peritonitis 393
Tuberculous Peritonitis 395
Carcinomatous Peritonitis 395
Pelvic Peritonitis 395

CHAPTER XXXI.

The Diagnosis of Parametritis (Pelvic Cellulitis) . 402

Definition 402
Classification 402
Acute Parametritis 403
Chronic Parametritis 404
Differential Diagnosis 406

PART III.

DIAGNOSIS OF DISEASES OF THE URINARY SYSTEM.

CHAPTER XXXII.

The Diagnosis of the Diseases of the Urethra and Bladder . 409

Anatomy 409
Physiology 411

PAGE
Topography 411
Natural Landmarks 412
Methods of Examining 413
Percussion 414
Palpation 415
Catheter and Sound 415
Inspection 415
Urethroscopy 415
Cystoscopy 415
Segregator 430
Malformations and Diseases of the Urethra 432
Malformations and Diseases of the Bladder 437

CHAPTER XXXIII.

THE DIAGNOSIS OF THE DISEASES OF THE URETERS . . 453

Anatomy 453
Physiology 453
Methods of Examination 454
Congenital Anomalies 458
Ureteritis 459
Obstruction of 461
Fistula 464

CHAPTER XXXIV.

THE DIAGNOSIS OF THE DISEASES OF THE KIDNEY . . 465

Topography 465
Methods of Examination 465
Movable Kidney 465
Perinephritic Abscess 469
New Formations 469
Renal Calculi 471

CHAPTER XXXV.

DIAGNOSIS OF THE CAUSES OF TOO FREQUENT AND PAINFUL URINATION . 474

CHAPTER XXXVI.

DIAGNOSIS OF THE CAUSES OF INCONTINENCE AND RETENTION OF URINE . 476

GYNECOLOGICAL DIAGNOSIS.

PART I.

GENERAL DIAGNOSIS.

CHAPTER I.

THE CLINICAL HISTORY.

In the diagnosis of diseases peculiar to women we have not only to recognize the disorders as found in the genitalia, their character and extent, but we must take under consideration associated lesions and functional disturbances in all parts of the body. To this end a systematic general examination should precede the local examination, and careful inquiry should be made into the family history and into the personal history relative to the social state and previous illnesses.

In order to be successful in the treatment of diseases peculiar to women we must duly consider all conditions—physical, social, and moral—that influence her well-being.

A PLEA FOR AN EARLY DIAGNOSIS.

The importance of an early diagnosis cannot be too strongly emphasized. The deplorable mortality in malignant disease, the progressive and destructive course of pelvic infections, the remote results of traumatisms and displacements of the pelvic viscera speak more emphatically than can words for the importance of an early diagnosis in diseases of women. The insidious onset of many of the lesions, the existence of malignant growths long before

giving rise to a clinical sign, speak for the uncertainty of any procedure looking to the early recognition of pelvic disorders.

Physicians are too often dilatory in recognizing conditions for examinations and in impressing their patients with the importance of an immediate one when there is a suggestion of departure from the normal. More frequently, however, the patient is at fault through ignorance, indifference, sloth, and so-called modesty. Thus a delayed menstrual period is unheeded until the rupture of a tubal pregnancy; the supposed return of the menstrual flow proves to be the bleeding of an inoperable cancer; a leucorrhœal discharge goes unheeded until the infection has spread to the tubes; a pain in the back becomes an every-day complaint, yet awakens no suspicion of a uterine displacement or a new-growth. And so it is that lesions of the pelvic viscera go unrecognized until far advanced and ofttimes incurable.

THE CLINICAL HISTORY.

In the making of a diagnosis the first important step is the recording of a clinical history. A carefully recorded history has many advantages: it serves as a guide to a systematic examination, and places before the physician a detailed, logical record of the case for future reference.

It is manifestly impossible to always adhere to a set form in case-taking. Neither is it possible to always adhere to the very good general rule of taking the full history at the time of the first examination.

The nervous state of the patient, together with many other factors, may preclude the taking of a complete history at the time of the first consultation. But at all times certain definite items may be recorded, and the history completed at a subsequent visit.

It is good advice given to students in text-books to begin with permitting the patient to recite her complaints without interruption. The patient becomes self-possessed, while at the same time the physician is given an opportunity to observe her general appearance, temperament, complexion, nutrition, carriage, and many other points bearing upon her case. After a time direct questions may be put to her, and as the answers are given they may be concisely placed on record.

FORM OF CASE RECORD.

In all text-books students are given a blank form to be filled out in the taking of a history. Such forms are of great service to the inexperienced practitioner, but for one who through long experience has acquired the art of case-taking they are unnecessary and ill-adapted. The allotted space may be inadequate to suit individual requirements. For myself, I prefer my letter-head, upon which the answers to questions can be hurriedly jotted, and to which subsequent notations can be added. This is placed in an envelope on which is recorded the name and address. These envelopes can be filed away in alphabetical order. Notes from all subsequent examinations, copies of prescriptions, correspondence with patient and physician can all be placed in the envelope from time to time. When visiting the patient the envelope can be placed in the pocket and referred to on the way.

As a compromise between the elaborate printed forms and the blank letter-head, the following form is recommended for simplicity, accuracy, and liberal spacing:

Name	Address	Date
Patient of Dr.	Address	
Age	Occupation	Nationality
S. M. W.	Para	Miscarriages

Events following childbirths and miscarriages:

General appearance

Family history

Previous illnesses

Present complaints

Menstrual history	Menses began	Type
	Quantity	Duration
	Pain	Menopause

Intermenstrual pain

Leucorrhœa

General physical findings

Nervous system

Cardio-vascular system

Digestive system

Respiratory system

Urinary system

Urinalysis:

Amount in twenty-four hours	Color	Sp. gr.
Reaction	Albumin	Sugar
Total solids	Urea	Microscope

Physical findings in pelvis and abdomen:

Abdominal wall	
Tender on pressure	Swellings
Visceroptosis	

Vaginal outlet

Vagina

Cervix

Uterine body

Tubes

Ovaries

Bladder

Rectum

Extragenital structures

Diagnosis

Treatment

Termination

A brief discussion of the above items will be of interest.

1. **Address.** The place of residence is inquired into, not only as a matter of business, but also to determine the possible influence of the environment upon the general health of the individual. Malarial districts, congested portions of the city, extremely warm or cold climates, exercise a definite influence upon the general and local condition of a woman.

2. **Age.** The special disturbances found in the various stages of life—*i. e.*, infancy, puberty, sexual maturity, climacteric and post-climacteric—are at once suggested when the age of the patient is known.

In infancy malformations and inflammations of the lower genital tract are to be looked for; tumors, displacements, and traumatisms seldom appear.

At puberty malformations of the genital organs are commonly first noticed through failure of the menses to appear; congenital displacements first cause disturbance at this time, because of the increase in the size of the uterus and the establishment of the menstrual functions; inflammations are usually confined to the vulva, rarely extending above the hymen; new formations and traumatisms are seldom observed.

During the period of sexual maturity all lesions of the genital organs may be found. Congenital malformations may first be observed after marriage and in childbearing. Inflammatory

lesions, involving part or all of the genital tract, most often arise as the result of childbearing, specific infection, and instrumental and digital manipulations. New formations usually make their appearance in this period. Displacements and traumatisms occur as the result of childbearing.

At the climacteric and postclimacteric periods all disorders have a special clinical significance. The possibility of malignancy should always be borne in mind. After seventy years of age it is unusual for any disorder to arise.

3. **Occupation** is an important factor in the causation and aggravation of pelvic disorders. In young girls confined in workshops the menstrual functions are seldom perfectly established. Poor ventilation, long working hours, heavy lifting, poor food, all exercise an unfavorable influence upon the development of the pelvic viscera and tend to aggravate existing maladies. On the other hand, sedentary and indolent habits are equally injurious.

4. **Nationality.** The Jewish race is said to menstruate early and to early reach the menopause. The Caucasian race is more subject to carcinoma, the African to fibroids.

5. **Social State.** It is well to inquire into the social state of the patient—to learn whether she is single, married, or a widow. An early understanding may forestall an embarrassing question as to the sexual relations, and will especially suggest possible causes for her complaints. For example, a recently married woman complaining of a leucorrhœa and painful urination is suspected of being infected. The fact that the patient is single or a widow should never mislead the examiner in his diagnosis; the possibility of pregnancy and venereal infection must always be excluded by the usual methods of examination, uninfluenced by the social state of the patient. While the physician must be alert to these possibilities he should exercise great tact and caution in his inquiries.

6. **Number of Children and Miscarriages.** Frequent childbearing and miscarriages almost certainly result in some sort of pelvic ailment. It is exceptional for a woman to give birth to several children without acquiring a pelvic disturbance. Complaints dating back to a childbirth or miscarriage suggest the probable finding of an inflammatory lesion, a displacement, or laceration.

The condition of the bowels and bladder, the cardio-vascular, nervous, and respiratory systems should be carefully inquired into.

Not infrequently a pelvic lesion is dependent upon a disorder of

the abdominal or thoracic viscera. Dysmenorrhœa, leucorrhœa, uterine hemorrhage, and sterility may be directly referred to a general disturbance. An excitable and overwrought nervous system alone may be responsible for many of the functional disorders of the pelvic viscera. Regard for the general condition of the patient and a due appreciation of the influence of the general upon local conditions will do much toward eliminating so-called "meddlesome gynecology."

7. **Family History.** It is not probable that heredity plays an important rôle in the etiology of pelvic disorders. In tuberculosis and to a less degree with carcinoma the influence of heredity should not be underestimated; but with the benign tumor formations, displacements, and malformations, heredity has little or nothing to do.

8. **Previous Illnesses.** Acute infectious diseases, tuberculosis, and all chronic wasting diseases, anæmias, and long-standing lesions of the thoracic and abdominal viscera may both originate and aggravate disorder in the genital tract.

9. **Present Complaints.** The complaints of the patient will often serve as a suggestion, but a diagnosis can never be based upon the objective signs in the absence of a physical examination. Any and all of the pelvic lesions may exist without subjective symptoms. On the other hand, there may be serious complaints on the part of the patient in the absence of a pelvic lesion. The familiar group of symptoms—hemorrhage, pain, leucorrhœa, constipation, and backache—are common to many altogether dissimilar lesions in the pelvis. We can, therefore, place but little reliance upon the complaints of the patient, but must depend in great part upon the physical findings.

10. **Menstrual History.** So far, we have considered the patient from the standpoint of the general practitioner. We now come to consider more particularly the disorders of the genital organs.

HEMORRHAGE FROM THE GENITAL TRACT.

In diseases of women the most significant of all symptoms is **hemorrhage.** While not in itself diagnostic, it is of the greatest value as an indication for an immediate and searching physical examination, both general and local. Hemorrhage from the genitalia comes from the vulva, vagina, cervix, body of the uterus, and

occasionally from the tubes; never from the ovary except in the case of a tubo-ovarian hæmatoma discharging its contents into the uterus—a most unusual event.

From the *vulva* hemorrhage is the result of trauma, new formations, ulcerations, lupus, cancroid, and rupture of varicose veins complicating pregnancy. The origin of the bleeding is recognized by direct inspection.

From the *vagina* hemorrhage is the result of causes similar to those above enumerated. An exceptional cause lies in metastatic growths of syncytium (syncytioma malignum). The bleeding site is readily disclosed by the vaginal speculum.

From the *vaginal portion of the cervix* hemorrhage follows immediately upon the delivery of the child as the result of lacerations. At the end of the childbearing period the most common cause of hemorrhage is carcinoma. Less frequent causes are sarcoma, tuberculosis, and erosions.

Before considering the morbid conditions causing bleeding from the uterus, let us briefly consider what may be looked upon as a physiological uterine hemorrhage.

MENSTRUATION.

No organism loses so much blood from the uterus as does woman. Within certain ill-defined limits this loss of blood is physiological; hence it behooves us to consider first of all the character of the menstrual act before taking up the discussion of pathological bleeding. The time of the onset of the menstrual function varies widely among individuals. Climate has much to do with determining the onset, and heredity has some influence. In this country Engelmann found the average age to be fourteen, in cold climates sixteen, and in warm climates nine years. We are all familiar with instances of precocious menstruation. The earliest case occurred in Glasgow at four days of age. Irion records a case at seven days, and the literature abounds in cases a few weeks and months of age. In nearly all these cases the genitalia were abnormally developed; there was hair on the pubis, and the breasts were often enlarged. It is not probable that menstruation could occur without premature development of the menstrual organs, and where this development is not found the hemorrhage should not be regarded as catamenial unless it recurs at monthly intervals. The

PLATE I.

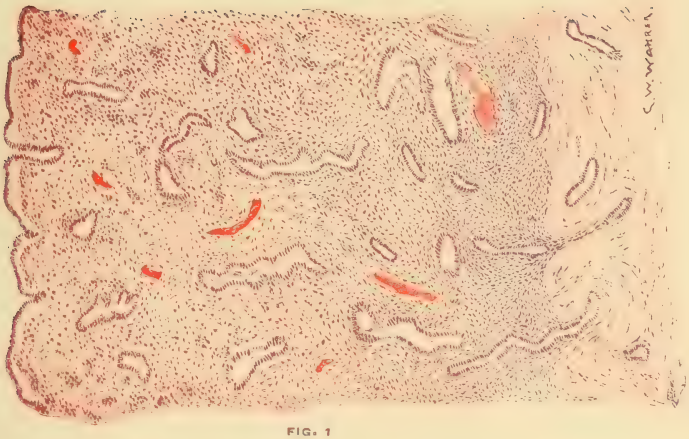

FIG. 1

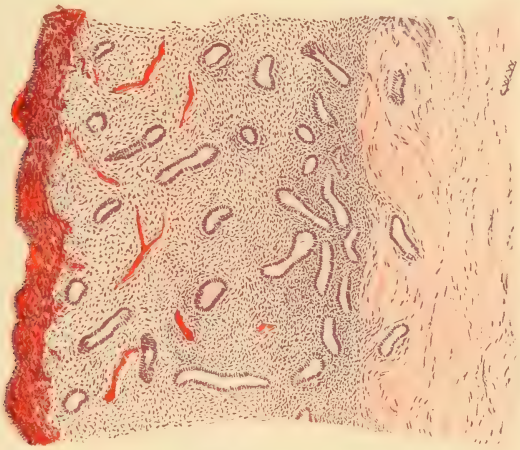

FIG. 2

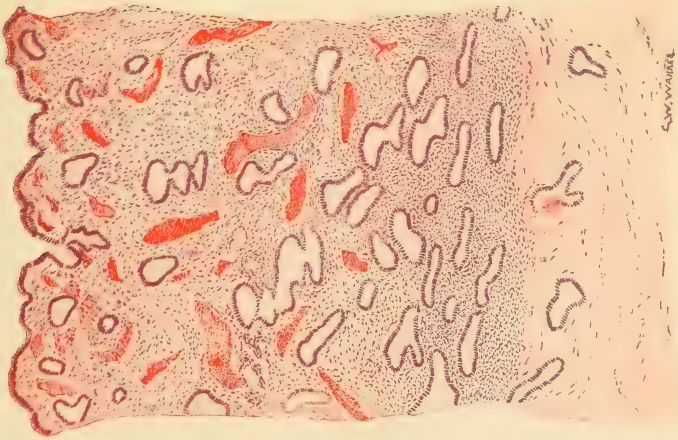

FIG 3.

Anatomy of the Menstruating Uterus.

mother will bring to the physician a napkin marked by a red stain, and will ask if it be possible that her child is menstruating. Such stains may be blood from a vulvovaginitis or urethritis, but are more often deposits of red urates or uric acid.

As to the frequency of the menstrual period, it is often stated that the normal type is twenty-eight days. But women are rarely so regular; there is usually a variation of one or more days. Regularity in the menstrual functions adds neither strength nor grace. Women menstruate at long or short intervals without ill-effect, providing the quantity of blood lost does not materially lessen their strength.

The average quantity of menstrual blood lost in a single period is estimated at six to eight ounces—the minimum two and the maximum ten. Obviously what may be regarded as a normal quantity for one may be abnormal for another. A plethoric, well-nourished woman may menstruate freely for eight days without harm, while the same loss of blood in an anæmic individual might seriously undermine her strength.

It is impractical to collect the menstrual blood. To estimate the amount of blood lost, the number of napkins soiled are counted. No exact information is gained by this procedure, because the size and quality of the napkins vary, and one woman will tolerate an over-saturated napkin, while another will scarcely permit staining. However, we have no better means at our command, and by estimating the usual number at fourteen napkins in the entire period we arrive at a fair estimate.

DESCRIPTION OF PLATE I.

Fig. 1 represents a specimen removed twenty-six hours after the onset of the menstrual flow. It corresponds to the first stage of Gebhard. The capillaries, which are rarely visible in the intermenstrual period of the normal uterus, are here shown to be widely dilated; a sero-sanguineous exudate permeates the stroma, widening the intercellular spaces; these changes are more marked near the surface. The glands are not affected, and the surface epithelium is intact and apparently normal.

Fig. 2 represents a specimen removed on the third day of menstruation, and corresponds to the second stage of Gebhard. The "subepithelial hæmatoma" is well-marked; the surface epithelium is lifted from its bed by the blood beneath; here and there the blood has burst through the epithelial covering and has carried away with it small bits of epithelium. Fatty degeneration of the mucosa is not in evidence.

Fig. 3 represents a specimen removed the day following the cessation of the menstrual flow; it corresponds to the third stage of Gebhard. The bloodvessels are less engorged than in the preceding specimen; the blood extravasated into the stroma is less in amount and does not give the appearance of fresh blood. The surface epithelium is intact and closely adherent to the stroma.

Anatomy of the Menstruating Uterus.

Kundrat and Engelmann were the first to record anatomical observations on the menstruating uterus. These observations were made on cadavers in which the endometrium of the uterine body had undergone fatty degeneration and the surface epithelium was exfoliated.

Later, Williams made postmortem examinations of twelve menstruating uteri. Nine of the twelve cases died of acute infectious diseases. He found fatty degeneration of the mucosa of the uterine body, as did Kundrat and Engelmann, and stated that the entire mucosa down to the musculature was exfoliated, that following menstruation the mucosa was regenerated from the musculature.

Leopold recognized the observations of Kundrat, Engelmann, and Williams as faulty, in that the changes in the endometrium as described by them might result from the acute infectious and chronic wasting diseases which were the causes of death. He carefully excluded all such, selecting those of normal menstrual type. He failed to observe fatty degeneration of the mucosa, but agreed that the surface epithelium was shed in the menstrual process. He does not state how long after death the sections were made, or the method of preparing the specimens. Within a few hours, certainly within twenty-four hours, after death or hysterectomy the surface epithelium undergoes degenerative changes and may be wholly lacking in microscopic sections.

It was Möricke who first excluded the possibility of postmortem and postoperative changes in the uterus by examining scrapings from the normal menstruating uterus. He curetted and made microscopic examinations of forty-five menstruating uteri in all stages of menstruation. In every instance the surface epithelium was found intact. In two additional cases Löhlein reported similar findings.

Westphalen also made a series of examinations of scrapings of the mucosa during the various stages of menstruation. In every case where the mucosa was normal the entire membrane was well preserved; in morbid conditions of the mucosa part or all of the surface epithelium was shed. Mandle confirmed these findings.

The most elaborate observations were carried out by Gebhard in Berlin. He not only examined scrapings, but also sections of uteri removed during the menstrual period for lesions not involv-

ing the endometrium. He classifies the anatomical changes into three stages:

1. *The stage of premenstrual congestion,* in which the capillaries of the mucosa are congested; a serous or serosanguineous exudate infiltrates the stroma of the mucosa, widening the intercellular spaces; later the blood leaves the capillaries and infiltrates the stroma, gravitating in the direction of least resistance—*i. e.,* toward the uterine cavity, and forming a collection of blood beneath the surface epithelium.

2. *The stage of active hemorrhage,* in which the blood is forced between the epithelial cells into the uterine cavity; here and there the epithelium is lifted from its bed, the continuity of the surface is broken, and bits of epithelium are accidentally broken off and are carried with the menstrual flow. Blood may also find its way into the gland lumina.

3. *The stage of postmenstrual involution,* in which the bloodvessels become less engorged; blood is no longer extravasated into the connective tissue spaces; the blood left in the stroma is slowly absorbed; the surface epithelium lifted from its bed resumes its former place, and lost epithelium is rapidly regenerated from adjacent epithelial surfaces.

These three stages are represented in Plate I. The sections here illustrated were taken from specimens removed by Dr. J. Clarence Webster in the Presbyterian Hospital, Chicago. Five hysterectomies were performed by Dr. Webster during the various stages of menstruation. In the three cases from which these specimens were taken the menstrual type was normal; in the other two there was an excessive menstrual flow resulting from endometritis associated with fibroids. Sections from the last two are not presented because of the morbid state of the endometrium; in them the surface epithelium was not seen.

Immediately upon removal the uterus was placed in salt solution, taken to the laboratory, and placed in Zenker's solution for twenty-four hours. Sections were then made from various parts of the endometrium, tubes, and cervix; they were then carried through the usual technic in preparing celloidin sections.

In all five cases the tubes show no changes, and the cervix is somewhat congested. The anatomical changes characterizing menstruation are confined to the mucosa of the uterine body.

While our knowledge of the physiology of menstruation is far

from exact, we are in possession of well-established facts relating to the anatomy of the menstruating uterus. Möricke, Mandle, Gebhard, Herzog, and others have demonstrated beyond dispute, as do these specimens here presented, that menstruation is not a shedding process, that the loss of epithelium is purely accidental and limited. Previous observations were at fault in the technic of preparing the sections, and in the selection of material which had undergone cadaveric changes and degenerative changes common to infectious and chronic wasting diseases.

The Menstruating Fallopian Tube.

It has been the consensus of opinion that the Fallopian tubes do not take part in the menstrual act. A few cases have been observed where blood collected in the tube during menstruation, and it is not proven that in these cases the blood came directly from the mucous membrane of the tube and not fom the uterus. (See Plate II.)

UTERINE HEMORRHAGE.

We read in text-books of menorrhagia and of metrorrhagia—the former term applied to an abnormal increase in the menstrual flow, and the latter to an intermenstrual flow. I would suggest that these terms be dropped from common usage because of the impossibility of distinguishing between the two in many cases. The one so often merges into the other in such a manner as to render impossible a distinction between a menstrual and an intermenstrual flow. Then, too, they are dependent upon the same general causes. For the sake of simplicity and exactness, we will include both under the general head of uterine hemorrhage.

DESCRIPTION OF PLATE II.

Plate II. represents a section of a Fallopian tube removed together with a menstruating uterus. A comparison of the section with those shown in Plate I. suggests a close analogy. The mucous membrane is engorged with blood, and free blood is found in the mucosa and in the lumen of the tube. The epithelium was found intact.

Since writing the above the author has examined the tubes removed, together with a menstruating uterus, finding, as shown in the accompanying plate, changes similar to those in the uterus.

PLATE II.

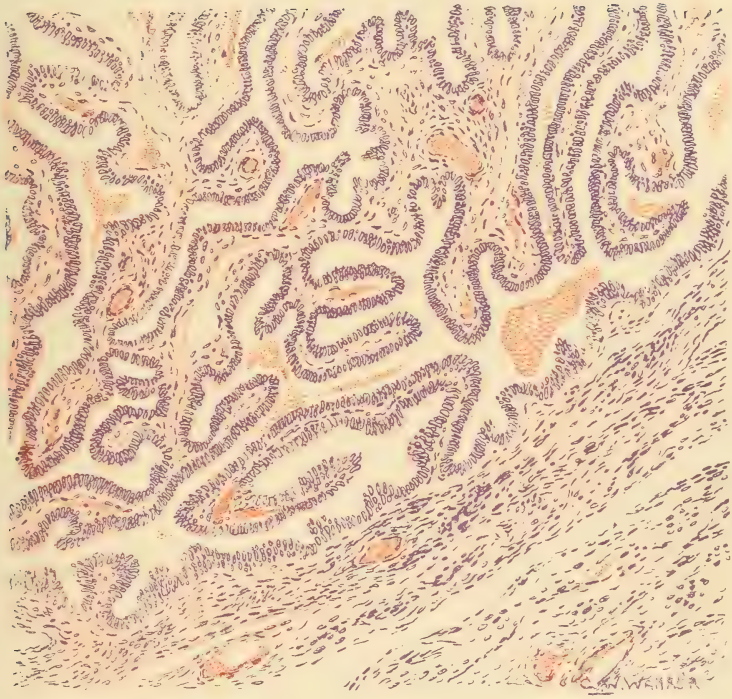

Systemic Causes of Uterine Hemorrhage.

Hemorrhage from the uterus may occur as the result of general systemic disturbances in the absence of a local lesion. We find that *anæmia* and *plethora* may cause hemorrhage—anæmia by reason of the low specific gravity of the blood and its diminished coagulability, and plethora from high vascular pressure. Chlorosis is the exception among the anæmias, in that the menstrual flow is lessened or absent. We commonly speak of anæmia as the result of uterine hemorrhage, when, as a matter of fact, it is not seldom the underlying cause.

All *puerpuric conditions* may be accompanied by hemorrhage from the uterus as well as from other parts of the body.

The *specific infectious diseases* may be complicated by hemorrhage from the uterus brought about by blood and vascular changes, and occasionally by endometritis, in which the cause was a specific infection. It is said that *emotion* will excite a hemorrhage from the uterus. I seriously question this statement, for in my own experience I have never seen the uterus bleed after a period of mental excitement in which there was not found a pathological lesion to account for the loss of blood. The mental disturbance serves only as an exciting cause of the hemorrhage, but without a pathological lesion there would be no hemorrhage.

Whatever impedes the return flow of blood from the uterus will bring about *passive congestion* in that organ, which in turn may result in hemorrhage. In this category may be mentioned displacements of the uterus, diseases of the heart, lungs, liver, kidney, and spleen, abdominal tumors, including ascites, and, lastly, chronic constipation.

Local Causes of Uterine Hemorrhage.

Subinvolution of the uterus, the result of postabortive infection, may be regarded as the most prolific source of pelvic disorders in the female. It is the starting-point of many displacements and inflammations which eventuate in uterine hemorrhage. The uterus is enlarged in all its diameters, and is deeply congested. Such an organ rarely maintains its position because of an increase in weight and a lack of support from the ligaments and pelvic floor, which have been stretched and torn in labor. The usual factors in the development of subinvolution are early rising from childbed,

traumatisms in labor, and infection following labor, and abortion. In this connection it is to be remembered that retained placental tissue will result in subinvolution of the uterus, and may remain organically attached to the uterus for days, months, and even years, keeping up irregular hemorrhages.

Endometritis is commonly recognized by the symptoms—hemorrhage, pain, and leucorrhœa. One or all of these symptoms may be absent, and the diagnosis must finally rest upon the microscopic examination of scrapings from the endometrium. *Indeed, a positive diagnosis of endometritis can be made only by the microscope.* When hemorrhage exists it is usually in the form of an increase in the menstrual flow—rarely an intermenstrual flow. Olshausen has described a lesion which he calls fungus endometritis, and bases his clinical diagnosis upon the presence of hemorrhage in the absence of pain and with little or no leucorrhœa. The endometrium is greatly thickened and thrown into folds and fungus-like masses, which, under the microscope, are seen to consist of a meshwork of enlarged and greatly distended glands, with but little interglandular connective tissue. Another variety of endometritis, usually resulting in a profuse menstrual flow, is the polypoid. Mucous polyps of the uterus are generally of inflammatory origin. Some authors believe them to be invariably of inflammatory origin, while all admit that they are in large part so. Hemorrhage is not an invariable symptom of polyps of the uterus, and their presence may be accidentally discovered by the curette or after the removal of the uterus for other reasons. In general, it may be said that uterine fibroids of whatever variety can only cause hemorrhage from the uterine cavity when the tumor involves the endometrium.

Fibroids rarely bleed; the hemorrhage comes from the endometrium. Furthermore, the hemorrhage is not proportionate to the size of the tumor. Submucous fibroids always cause bleeding. Intramural fibroids, if in any way influencing the endometrium, may cause bleeding, but subperitoneal fibroids cannot. We are, therefore, able to determine something of the position of the growth by the presence or absence of hemorrhage.

One of the earliest symptoms of cancer and sarcoma of the uterus is hemorrhage. Yet these growths may be far advanced before hemorrhage or any other symptom is manifest. It is for this reason that malignant diseases of the uterus are so rarely observed in time to effect a radical cure. When hemorrhage does make its appear-

ance it is too often looked upon as an irregularity of the menopause. *Our statistics in carcinoma of the uterus would be greatly bettered if all hemorrhages occurring at the time of the menopause and after this period were viewed with suspicion, and the cause sought for, rather than that all irregularities be ascribed to the menopause.*

There is a malignant growth which I will only refer to. It is usually called deciduoma, and is a malignant degeneration of the placental tissue. Hemorrhage is the earliest symptom, and it may be laid down as a rule that when an irregular hemorrhage follows late upon childbirth, hydatid mole, or abortion, the possibility of malignant degeneration of placental tissue must be borne in mind. The diagnosis can only be determined by an exploratory curettage and microscopic examination of the scrapings.

When hemorrhage occurs during or immediately after the third stage of labor, it is possible that placental tissue is retained in the uterus, or that the uterus is relaxed from fatigue and overstretching.

Improbable as it may seem, death from hemorrhage rarely follows rupture of the uterus; death is more likely to occur from subsequent infection.

I will only refer to placenta prævia, hydatid mole, premature detachment of the placenta, and ectopic pregnancy as causes of uterine hemorrhage.

Arterio-sclerosis alone has been charged with the responsibility of uncontrollable uterine hemorrhage by Herman, Martin, Reinecke, and Küstner. The charge cannot be wholly sustained, because in none of their cases is there a record of having excluded other possible causes lying beyond the uterus. Reinecke and Martin performed hysterectomy in thirteen cases for the control of hemorrhage, and in all the removed uteri the arteries were found sclerosed; but they did not exclude the possibility of obstruction to the return circulation from such causes as diseases of the heart and lungs, thrombosis of the venous trunks, and portal congestion from whatever cause. My point is that in the light of twelve cases reported by Von Kahlden, Popoff, Herxheimer, and Dietrich, and the one I reported, arterio-sclerosis *per se* may alone be insufficient to cause a hemorrhagic infarction of the uterine tissues or hemorrhage into the uterine cavity. In the eight cases reported by Von Kahlden the postmortem findings showed anatomical hinderances to the general circulation. There was pneumonia in two of the cases,

pulmonary emphysema and bronchitis in three cases, cancerous infiltration of the lungs and liver in one case, pulmonary infarcts in another, and in four of the eight cases there were cardiac lesions. In the case of Popoff there were granular nephritis and heart thrombi, pleural effusion, and infarction of the lung and brain. In Herxheimer's case there was an hypertrophied heart and thrombi in the left ventricle and right auricle, granular nephritis, and atheroma of the aorta. In my own case hemorrhage did not occur until there was an additional obstruction to the circulation caused by the plugging of the uterine artery. It is, therefore, not conclusively demonstrated that arterio-sclerosis can in itself be the cause of uterine hemorrhage. It would appear that there must be additional causes for obstruction, such as were found in the above recorded cases. (See Plate III.)

In the so-called "apoplexia uteri" it is probable that the hemorrhages are not caused by the rupture of the bloodvessels, but rather are due to capillary oozing. This would account for the hemorrhagic infiltration being so removed from the sclerosed vessels in the cases of Von Kahlden.

Respecting the etiology of arterio-sclerosis of the uterine vessels and hemorrhagic infarction of the uterus, little can be said. Age varies within the limits of fifty and eighty-seven years. Pregnancy, menstruation, and inflammation of the uterus have some bearing upon the etiology. The causes of arterio-sclerosis elsewhere in the body would obtain in the uterus—*i. e.*, alcoholism, chronic malaria, chronic lead poisoning, syphilis, etc.

Referring to the frequency of the lesion, it is not unlikely that arterio-sclerosis of the uterine arteries and hemorrhagic infarction of the uterus are often overlooked in clinical and postmortem examinations. It is probable that many cases of so-called "senile endometritis" and "hemorrhagic metritis of the menopause" are in reality hemorrhagic infarction of the uterus, and have as an underlying factor arterio-sclerosis and calcareous degeneration of the uterine vessels. The fact that these cases occur in advanced years may not be associated with leucorrhœa, and no cause may be found for the hemorrhages, either by clinical examination of the uterus and adnexa or microscopic examination of scrapings from the endometrium, would be strong evidence in favor of the view that these cases are not infrequently hemorrhagic infarcts of the uterus and that the primary lesion lies in the bloodvessels.

PLATE III.

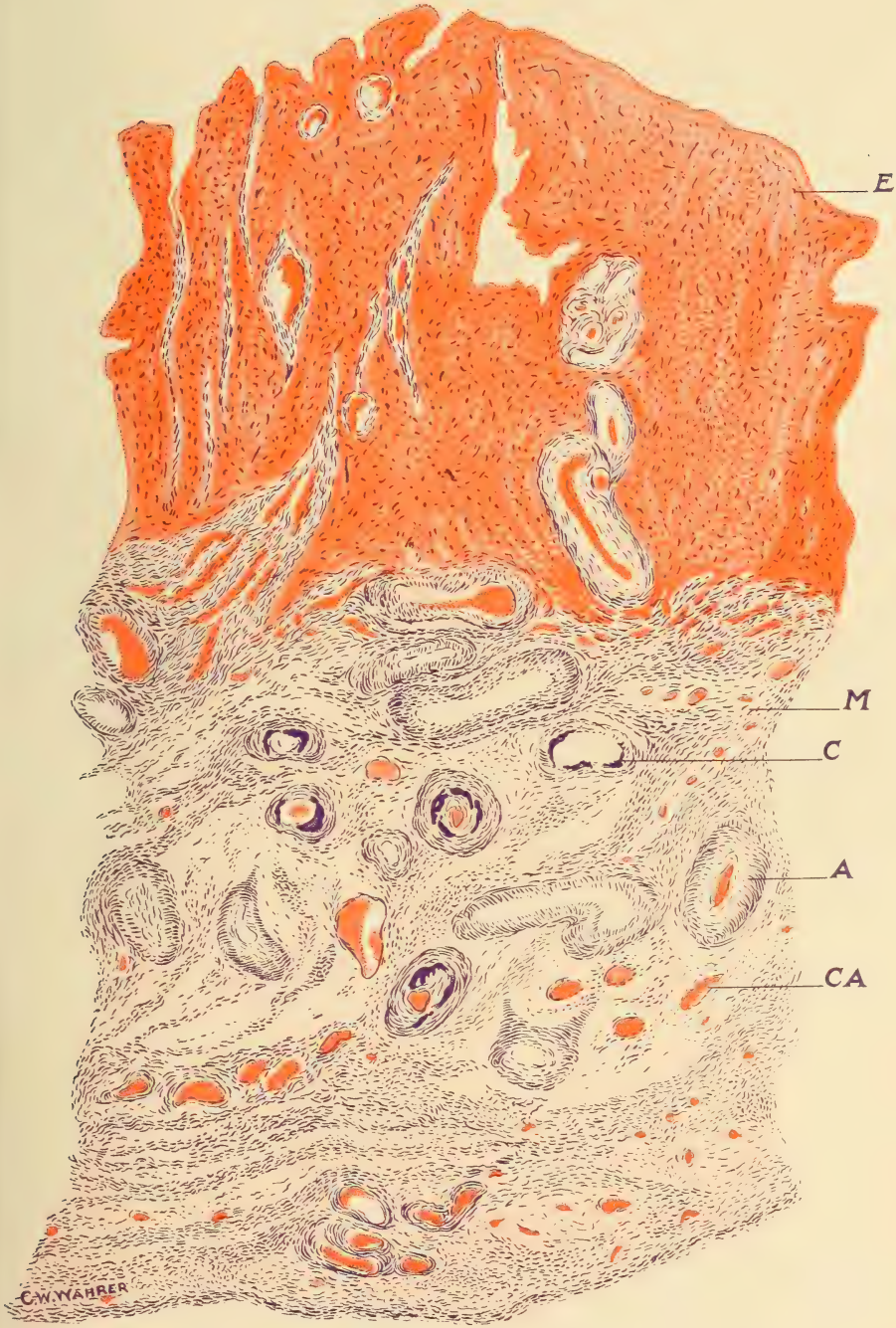

Arterio-sclerosis and Calcification of the Uterine Arteries.

M. Musculature.
E. Endometrium with effused blood.
C. Calcareous deposits in vessel wall.
CA. Congested vessels.

As to the diagnosis, we are usually content to call such cases endometritis when there is no demonstrable cause for the hemorrhage. If an exploratory curettage is made with negative findings, the indefinite diagnosis of metritis will probably be given, particularly when the uterus is of dense consistence and uniformly increased in size. It is possible that the increase in the connective tissue of the myometrium may interfere with the circulation, but it is altogether certain that in many cases the primary cause lies in the walls of the bloodvessels, and the hyperplasia of the uterus is secondary. It is altogether probable that arterio-sclerosis of the uterine vessels may exist without symptoms, and, as above stated, there probably must be some additional obstruction to the return circulation in order to cause hemorrhage, which event alone is suggestive of the lesion. The clinical diagnosis is then at best uncertain. If hemorrhage occurs in the climacterium or near the time of the menopause, and there can be found no local cause for the hemorrhage, either in the presence of new-growths of the uterus and adnexa, in the position of the uterus, or in the microscopic examination of the uterine scrapings, then it is fair to presume that arterio-sclerosis of the uterine arteries exists. If, in addition to this, there is found arterio-sclerosis of the peripheral arteries of the body, and there exists a disease of the viscera to account for an obstruction in the return circulation from the pelvis, then it is further fair to presume that a hemorrhagic infarction of the uterus is present, and that the uterine hemorrhages are due to a hemorrhage into the tissues and cavity of the uterus. It is not probable that the sclerosed vessels will be found in the scrapings, because they commonly lie in the outer half of the uterine musculature. Caution must be exercised in the liability of mistaking the compressed glands for cancer nests.

Finally, it may be said that the popular impression that the flow is increased in the climacteric leads to disastrous consequences. No increase in the menstrual flow at the time of the climacteric should be regarded as normal or of no clinical importance. A searching examination is imperative.

The character of the discharged blood varies not only in amount, but in color and consistency; and from these characteristics something may be inferred as to the origin of the hemorrhage. The menstrual blood is usually thin and of a bright red to a dark brown color. Coagulation is hindered by the alkaline reaction of the

uterine secretions. Coagulated menstrual blood is always abnormal.

Coagulation of the blood may occur in endometritis, uterine fibroids, carcinoma, polyps, and abortion. When of a dark, brownish-red color it is inferred that the passage of the blood has been obstructed, giving time for coagulation within the uterine cavity. When mucus is intimately mixed with the blood it indicates an involvement of the cervix from cervical catarrh, polyp, carcinoma, or sarcoma.

Blood of a syrupy consistency is supposed to have remained a long time in the uterine cavity. Tissue fibres mixed with the blood suggest the presence of degenerated new-growths.

AMENORRHŒA.

In determining the causes of amenorrhœa it is well to bear in mind the physiological conditions in which the menses fail to appear. **A physiological absence of menstruation occurs:**

1. Before puberty.
2. During irregular intervals at the time of the establishment of menstruation.
3. During pregnancy and lactation.
4. During the establishment of the climacteric—"dodging period."
5. After the menopause.

When the menstrual flow is retarded or when the quantity is less than normal we speak of the condition as *amenorrhœa.* The term may be further qualified by the words relative and absolute.

By *relative amenorrhœa* is meant a menstrual flow that is below the normal amount for the given individual. That which is abnormal for one may be normal for another, depending upon the general condition of the individual.

By *absolute amenorrhœa* is meant a total suppression of the menses.

The causes of amenorrhœa are both general and local.

General Causes of Amenorrhœa. 1. *Debilitating diseases,* such as primary anæmia, Bright's disease, tuberculosis, malaria, and nervous diseases. In determining the cause of amenorrhœa it is not enough to establish the fact of anæmia, but we must ascertain

the character of the anæmia by an analysis of the blood, and, if possible, demonstrate the underlying cause.

Among the general causes of secondary anæmias we find two groups—those caused by deficient nutrition and those caused by increased waste. Digestive and respiratory disorders limit the supply of blood and oxygen essential to the proper nourishment of the body, and, indirectly, to the performance of the menstrual functions.

Hemorrhage from any part of the body, chronic diarrhœa, continued suppuration, albuminuria, and the like results in excessive waste that will bring about amenorrhœa.

2. *Changes in environment* are often followed by amenorrhœa for a variable length of time. Girls coming from foreign countries to the United States commonly experience a delay in the appearance of the menses for a variable time.

3. *Mental shock and anxiety* may cause a suppression of the menses. The fear of conception may suppress the menstrual periods, and when the fears are allayed the menses may promptly return.

4. "*Catching cold*" is a term in ordinary usage, implying a congestion of the pelvic viscera. Part or all of the menses may be suppressed by exposure to cold during and immediately before the menstrual period.

Local Causes of Amenorrhœa. 1. *Congenital absence* of the organs essential to menstruation, namely, the uterus and ovaries.

2. *Hypoplasia and atrophy* of the organs essential to menstruation.

3. *Retention of the menses* from atresia of the cervix and vagina, imperforate hymen, and tumor formations obstructing the outflow of the menstrual blood.

4. *Removal of the uterus and ovaries*, doing away with the menstrual flow.

5. *Diseases of the genital organs*, disabling and destroying the tissues essential to menstruation—that is to say, metritis, endometritis, chronic ovaritis, cystic degeneration of the ovaries, and new formations in the uterus and ovaries.

Effects of Ovariotomy on Menstruation. In this relation it is interesting to note the effect upon menstruation of the removal of the ovaries. After both ovaries are removed menstruation stops abruptly in 66 per cent. of cases. In the remaining 33 per cent.

menstruation stops gradually throughout a period of one to six months.

The cause of uninterrupted menstruation after double ovariotomy is explained by the presence of a supernumerary ovary or by the accidental leaving of a bit of ovarian tissue adherent to the neighboring structures. A small portion of the ovary may have been constricted off from the parent ovary by contracting bands of adhesions, and may escape notice in the removal of the ovary. The law of persistence of habit may explain an occasional case. More often a flow persists as the result of a uterine tumor or an inflammatory lesion, and is not, strictly speaking, a menstrual flow.

Menstrual Molimena. The local and general disturbances which occur at the time when the menses should appear, but fail because of the above-named causes of amenorrhœa, are included in the term *menstrual molimena.* These disturbances are pain in the region of the ovaries, in the back, and radiating to the thighs ; also flushing of the face, dizziness, palpitation, and headache. The duration of these symptoms varies from a few hours to the entire month. The menstrual molimena generally begin about one month after the removal of the ovaries, and extend over a period of one or two years, sometimes much longer.

PAIN IN THE PELVIS DURING MENSTRUATION—DYSMENORRHŒA.

Pain in the pelvis is often referred to the uterus or ovaries. Of all pains in the abdomen the so-called "ovarian pain" is by far the most usual. Experience teaches us that pain is referred to the ovary of the left side three times as frequently as to the right. There is no satisfactory explanation for this. It is a matter of every-day clinical experience that the pain is often referred to the left ovary when there is no apparent disease in either ovary ; more than that, there may be no demonstrable lesion in the pelvis, yet more strange is the finding of the lesion in the right ovary and the pain referred to the left ovary. The author makes no attempt to explain these facts. Certain it is that reflex pains may be located in the ovary and the lesion confined to the uterus or opposite ovary. We are not to infer from complaints of pain in the ovary that this structure is diseased, but such pains may well suggest possible lesions in one or more of the pelvic viscera. Such pains are

particularly frequent and severe at the time of the menstrual period. This brings us to the discussion of dysmenorrhœa, a term often misused and little understood.

In determining the cause of dysmenorrhœa we must first consider the condition of the nervous system. A condition causing pain in one individual may be unnoticed in another of more stable equilibrium. When pain in the pelvis is complained of during and between the menstrual periods and a thorough examination reveals nothing abnormal in the pelvis, we are in the habit of concluding that the fault lies in a functional derangement of the nervous system, and we vaguely apply the terms hysteria, neurasthenia, and neuroses. A certain degree of pain during the menstrual period may be considered within normal limits, and in very nervous women such pains may become exaggerated to actual suffering.

The explanation of the "normal" menstrual pains is probably found in the engorgement of the endometrium, which, acting as a foreign body, excites the uterus to contract; and it is these uterine contractions which occasion the pain. In many of the pathological lesions involving the pelvic viscera the menstrual congestion is added to the already engorged tissues, and the pain is severe. It is exceptional for pathological lesions to exist in the uterus and adnexa without dysmenorrhœa, but knowing such to be possible, and, on the other hand, knowing that pain of equal intensity may exist in the absence of a pathological lesion, we are at a loss to know how much the pain is due to structural changes and how much to an excitable nervous system. We may speak of *idiopathic* or *primary dysmenorrhœa* when it is evident that the pain bears no relation to pathological lesions of the genitalia, and of *secondary dysmenorrhœa* when it is evident that the pain is the direct result of a morbid condition in the genital tract.

Secondary dysmenorrhœa may be caused by all lesions of the genital tract. These may be classified under:

1. *Maldevelopments* and *malformations*, which cause menstrual pain by obstructing the outflow of the menstrual blood. In this category may be included absence or atresia of the vulva, vagina, and cervix. The menstrual molimena are experienced, but without a show of blood. With the return of each monthly period the pain increases in intensity as the result of accumulated blood within the uterus, tubes, and, possibly, the pelvis. The obstruction may not be complete, and the retarded blood, having time to coagulate,

is then expelled with cramping-like pains—the so-called "obstructive dysmenorrhœa."

2. *Malpositions* of the uterus and adnexa are less frequently the cause of dysmenorrhœa than are the associated lesions. It is exceptional for the menstrual blood to be obstructed in its outflow by the bending or twisting of the long axis of the uterus. Pain is more often the result of complicating lesions in and about the uterus and its appendages.

3. In *inflammatory diseases* of the uterus and adnexæ, which are more or less tender and painful in the intermenstrual period, the suffering is greatly intensified by the menstrual flux—"congestive dysmenorrhœa." Plugs of tenacious mucus may fill the cervical canal and obstruct the menstrual flow.

4. *New formations* in the genital tract may obstruct the menstrual blood—"obstructive dysmenorrhœa." Pelvic tumors share in the menstrual congestion, and by their enlargement the pressure symptoms are intensified.

Membranous dysmenorrhœa is a term first applied by Morgagni. In this condition there is discharge at the menstrual period of a part or the whole of a cast of the uterine cavity. The discharge of the membrane may occur but once or at each menstrual period. If we believed that the endometrium is shed at each menstrual period we might conclude that membranous dysmenorrhœa is merely an exaggeration of the normal process. The membrane may be shed as a complete triangular cast of the uterus, or may be discharged in shreds.

Under the microscope we see a great variation in structure. The membrane may resemble an hypertrophied endometrium, a decidua, or a fibrinous membrane.

Accompanying the discharge of the membrane is intense pain. The membrane is not to be mistaken for the decidua of extra-uterine or intra-uterine pregnancy.

THE DIAGNOSIS OF THE CAUSES OF STERILITY IN WOMEN.

Before entering into a discussion of the various causes of sterility in women let us clearly understand the clinical significance of the term sterility and the conditions essential to conception.

By sterility we mean an incapacity for childbearing; this definition may be further qualified by the terms "absolute sterility"

and "relative sterility." Sterility is absolute when the individual is incapable of bearing a child to the period of viability; she may conceive, but habitually aborts before the period of viability. Sterility is relative when childbearing is not in accordance with conditions, age, and length of married life. We may speak of relative sterility when three years have elapsed since the last childbirth, or when conception has not taken place within three years from date of marriage—this time limit is, of course, purely arbitrary.

Again, we may speak of sterility as primary and secondary: primary when the conditions which preclude the possibility of childbearing are primary; secondary when after the birth of one or more children there is acquired an incapacity for childbearing.

The conditions essential to conception are briefly enumerated as follows:

1. Deposit of semen containing living, active spermatozoa in the upper segment of the vagina.

2. Passage of the spermatozoa through the cervix into the cavity of the uterus. It is said that spermatozoa will not live longer than twelve hours in the acid secretions of the vagina; while in the uterus and tubes they commonly retain their vitality six to eight days. Leopold reported a case of a woman in his clinic who had not had sexual intercourse for thirty-seven days prior to the operation, when, on abdominal section, living, active spermatozoa were found in large numbers in the fimbriated end of the tube. This case, with many other observations on women and lower animals, has led to the statement that fertilization of the ovum commonly takes place in the tube.

3. A healthy ovum must find an uninterrupted passage from the ovary, through the tube, and on into the uterine cavity.

4. The fertilized ovum must find a permanent resting-place on the endometrium until the period of viability.

With the above definitions of sterility and the conditions essential to conception set clearly before us, we are now in a position to consider the factors which tend to prevent conception.

In seeking the cause of sterility not only the whole range of diseases peculiar to women must be considered, but as well the general physical and social conditions of the individual. More than this, we are not to conclude that the cause of sterility is necessarily found in the woman; full one in six sterile marriages are chargeable to the husband. One marriage in ten is non-productive, and, with

few exceptions, sooner or later the advice of the physician is sought. The subject is, therefore, of prime importance to the physician, and no condition more thoroughly taxes the skill of the general practitioner and specialist.

In determining the cause of sterility we should first consider the general conditions predisposing to sterility, and first of these is *age.* No cause of sterility approaches age in extent and power. The most prolific time of life is between the ages of twenty and twenty-four. Pregnancy may occur before the menstrual period, as so often happens in India, where it is considered a sin to let pass an opportunity for conception—a sin equivalent to infanticide. Because of this belief it is customary to marry before puberty. A case is recorded where a woman gave birth to twelve children before her menstrual flow appeared. Again, it is possible for pregnancy to occur long after the cessation of the menstrual period. Trento reported a case of a woman who gave birth to a child at sixty-seven years of age. Abraham was one hundred years of age and Sarah was ninety when their child was born. Sarah "was old and well stricken with years, and with whom it had ceased to be as it is with women"—that is, she had ceased to menstruate. So, while pregnancy is possible after the menopause, the rule is that the capacity for childbearing ceases four to six years before the cessation of the catamenia.

Anœmia, either primary or secondary to some wasting disease, such as tuberculosis, diabetes, nephritis, and malaria, is an important predisposing factor, and must always be taken into account whatever else may be found.

Marriage of near relatives is said to be a cause of relative sterility, but this statement is not confirmed.

Obesity is undoubtedly a potent cause of sterility. When a woman rapidly increases in weight she very often becomes sterile, and in such the most promising means of relieving sterility is to reduce the weight.

Alcoholism is an indisputable factor; furthermore, the death rate among children born of inebriate mothers is double that of temperate parentage.

The *sexual instinct* evidently has some influence upon the fertility of women. While it is true that many women bear children who have never experienced sexual desire, it is the rule that women are most likely to conceive who have the greatest sexual vigor.

Sexual excess, on the other hand, conduces to sterility through the congestion and inflammation resulting from such excesses.

Sexual incompatibility is an ill-defined condition that plays a rôle in the causation of sterility, though no explanation is offered. We are reminded of the marriage of Josephine and Napoleon.

Having considered the above general predisposing causes, we now look to the more tangible local factors.

Dyspareunia is not an uncommon cause of sterility, and in every case the underlying cause of painful coition must be determined. We look for lesions obstructing the lower genital passage, such as acquired and congenital atresia of the vulva and vagina; overgrowth of the labia and clitoris, and tumors of the vulva, vagina, and uterus, which encroach upon the lower passages. We also look for lesions causing pain, such as urethral caruncle, inflammatory lesions of any portion of the genital tract; inflammation of the urethra and vagina, and for painful lesions of the rectum, including fissure and hemorrhoids. Vaginismus without a recognizable lesion is an occasional cause of dyspareunia. It is not essential to conception that sexual union be complete. This is demonstrated by the fact that pregnancy may occur with an intact hymen and in the presence of other evident obstructions to complete sexual union.

The *maldevelopments* and *malformations* of the genital organs are occasional causes for absolute sterility. The absence of any of the reproductive organs, or the failure of these organs to fully develop, are certain causes of sterility. A uterus partially or completely divided is not likely to become pregnant, and a septum dividing the vagina may offer an obstruction to sexual intercourse. When a woman complains of amenorrhœa, or at most of a scanty irregular flow which has persisted from a delayed puberty, it is highly presumptive that the uterus, together with the tubes and ovaries, has failed to develop beyond the infantile type. The ovaries are primarily at fault in the majority of cases, and in consequence the uterus fails to develop. While there is little encouragement in treatment of any kind it is manifestly illogical to direct the treatment to the uterus rather than to the ovaries—a procedure akin to whipping the cart to make the horse go. The complete closure of any portion of the genital tract will result in sterility, but these conditions are rare, with the exception of closure of the tubes from inflammatory adhesions. The influence of stenosis in causing sterility is doubtless exaggerated. A congenital narrowing of the cervical canal pre-

vents the passage of spermatozoa, but in such cases there is usually an under-development of the uterus, and possibly the ovaries as well to account for the sterility.

The vagina may be too short or too narrow to retain the semen, and the cervix may be too long to allow the entrance of the spermatozoa from the vault of the vagina A short cervix *per se* is not a cause for sterility; not infrequently the explanation lies in an under-development of the uterus.

A frequent cause of secondary sterility is superinvolution of the uterus brought about by superlactation, infection, and malnutrition.

Malpositions as direct causes of sterility have been greatly overrated. Pregnancy is possible in all malpositions of the uterus with the exception of complete inversion. We are forced to conclude that the underlying cause is more often in accompanying inflammatory lesions and in dyspareunia. Chronic endometritis and ovaritis are so commonly associated with displacements, and are such potent causes of sterility, it is fair to assume that they are most often the underlying cause.

The displaced cervix is a more likely cause than is the displaced body of the uterus. The difficulty with which the semen enters the cervix when displaced forward, or to the side in backward or lateral displacement of the uterine body, will account for sterility, whereas it is difficult to conceive of the cervical canal being obstructed by the flexion of the body upon the cervix. The thick resisting wall of the uterus will not permit of so sharp bending as to obstruct the passage of spermatozoa. Reasoning *a priori*, an extreme retroversion with the cervix pointing upward and forward would more likely cause sterility than would an uncomplicated retroflexion with the cervix pointing downward and backward. From like reasoning descent of the uterus, especially when associated with elongation of the cervix, as is usually the case, would be still more likely to result in sterility because of the difficulty of the semen gaining entrance to the cervical canal.

Traumatisms of the cervix and vagina not infrequently predispose to sterility. A lacerated perineum allows of the free escape of semen from the vagina, and a lacerated cervix followed by erosion and eversion of the cervical mucous membrane may offer an obstruction to the semen. Rectovaginal and vesicovaginal fistulæ cause sterility by the effect of the urine and feces upon the semen, by the accompanying vaginitis and the resulting dyspa-

reunia. Cicatricial contraction of the vagina following an injury may interfere with sexual union.

Pelvic inflammation is by far the most prolific source of sterility, and first among the various lesions is endometritis. The hyperplastic form of endometritis will most certainly cause sterility, and particularly when associated with profuse hemorrhages and leucorrhœa. The diseased endometrium is an unfavorable resting place for the ovum, and the discharges play havoc with the spermatozoa. In the cervix the increased mucous secretions of endocervicitis plug the cervical canal so effectually as to prevent the entrance of the semen. Vulvovaginitis may prevent conception through perverted acid secretions and dyspareunia. Infections of the tubes destroy the cilia and often as well the epithelium, thereby hindering the progress of the ovum. Closure of the fimbriated end of both tubes, resulting in a distention of the tube with serum, blood, or pus, will almost certainly cause permanent sterility. Yet it is of interest to know that pregnancy has followed upon the disappearance of double pyosalpinx.

A chronic inflammation or passive congestion of the ovary results in a hyperplasia of the connective tissue surrounding the follicles, and in a thickening of the tunica albuginea and in possible adhesions surrounding the ovary. All this renders difficult or impossible the escape of ova into the tube.

In pelvic cellulitis and pelvic peritonitis constricting bands of adhesions may obstruct the lumen of the tube, and so displace the uterus, ovaries, and tubes as to cause sterility. In all these forms of infection dyspareunia is a large factor in the causation of sterility.

New formations as causes of sterility are yet to be considered. In general, they operate through mechanical obstruction. By their presence an inflammatory reaction may develop as the prime cause of the sterility. Degeneration of the tumor leading to an irritating discharge acts in a deleterious manner upon the spermatozoa. The size of the growth is not of so much consequence as the position ; a small fibroid in the cervical canal may cause complete obstruction, while pregnancy may go on to full term in subperitoneal fibroids of enormous size. Malignant growths rarely cause sterility, because the childbearing period is usually at an end before the advent of either carcinoma or sarcoma. Sterility associated with amenorrhœa in the presence of an ovarian cyst suggests the possible presence of a similar involvement of the other ovary.

THE MENOPAUSE.

The average time of appearance of the change of life is from forty to fifty-five years of age. The earliest recorded natural menopause began at twenty-four years of age, the latest at seventy. The *factors influencing the time of appearance of the menopause* are:

1. *Climate.* The colder the climate the later the menopause.

2. *Social State.* Sir Andrew Clark states that the menopause occurs earlier in the more civilized and cultured classes.

3. *Race.* The Jews reach the menopause at an earlier time than the average woman in the same climate.

4. *Heredity.* It has been frequently observed that heredity has a determining influence upon the establishment of the menopause; this tendency toward an early or late menopause may persist through several generations.

5. *General and Local Diseases:*

(*a*) Those favoring an early climacteric are atrophy of the uterus and ovaries, superinvolution of the uterus, chronic metritis and ovaritis, and the general wasting diseases.

(*b*) Those favoring a late climacteric are malignant growths and fibroids of the uterus, endometritis, subinvolution of the uterus, and chronic metritis.

The climacteric has an average duration of three to four years, during which time the menstrual periods commonly recur at longer and longer intervals as the flow becomes more and more scant; this is known as the "dodging period."

In about one woman in seven the menses stop suddenly and permanently.

The *clinical manifestations* of the menopause are most varied. They are seldom wholly absent, nor are they constantly present. As a rule, they recur at irregular intervals.

The general phenomena associated with the menopause are nervous disturbances, such as irritable temperament, despondency, forgetfulness, fainting, vertigo, flashes of heat and cold, perversion of taste, loss of sexual desire, and occasionally a homicidal or suicidal tendency.

The local phenomena are atrophy of the genital organs and of the breasts, and in many cases an increase in the body weight. There are no facts to substantiate the statement that the development of skin diseases is influenced by the menopause.

LEUCORRHŒA.

Any discharge from the vulva that is not blood is popularly called "whites" or leucorrhœa. When the secretion departs from the normal in color, consistency, odor, irritability, and amount, there must exist either a functional or an organic lesion of the genital organs. It is of the greatest importance to determine the character and source of the secretion.

The normal secretions of the genital organs are: 1. From the vulva the ordinary secretions of sebaceous and sweat glands. The Bartholinean glands lying in the labia majora secrete mucus, particularly during sexual excitement. The reaction is alkaline, and the amount is scarcely noticeable.

2. The vagina does not ordinarily contain glands, but occasionally a few are found in the vault of the vagina. The vagina has essentially a skin surface, having no secretion under normal conditions. The so-called vaginal secretion is the accumulated outpour of the uterine body and cervix mixed with epithelium and bacteria. The secretion is acid in reaction as the result of the action of certain bacteria changing the alkaline secretion of the uterus to an acid reaction.

3. The secretion of the cervix is mucus. It is tenacious and alkaline in reaction.

4. The secretion of the endometrium is serous and sufficient in amount to moisten the surface; it is alkaline, clear, and transparent.

For clinical purposes we will consider leucorrhœa as it occurs in the various periods of life.

Leucorrhœa in Infants. In children a leucorrhœal discharge seldom arises from a point above the hymen. As a rule, it is the expression of a vulvitis, which, in turn, is caused by soiled diapers, intestinal worms, highly acid urine, gonorrhœa, masturbation, and the strumous diathesis. The vulva appears swollen and reddened, is tender to pressure, and is covered by a slimy secretion.

Leucorrhœa in Virgins. In young girls it is not unusual for a transient leucorrhœa to appear from time to time. No pathological basis for the leucorrhœa can be discovered further than a possible pelvic congestion. Persistent leucorrhœa may be due to the same causes found in childhood. As in infants, the lesion is commonly a vulvitis, and is rarely found above the hymen. The secretion is seldom sufficient to more than moisten the vulva, and rarely calls

for a local examination. Anæmia is always to be considered in determining the contributing factors.

Leucorrhœa in the Period of Sexual Maturity. The secretion may come from any portion of the genital tract—from the vulva, vagina, cervix, body, and tubes. In the vast majority of cases the cause may be ascribed to gonorrhœa and to labor and abortion. The most profuse leucorrhœa is occasioned by gonorrhœal infection. In addition to these causes may be mentioned instrumental and digital inspection, displacements of the uterus, passive congestion due to an interference with the return supply of blood from diseases of the heart, lungs, liver, kidney, and spleen, and also to abdominal tumors, to acute infectious diseases, and to all benign and malignant new formations of the vulva, vagina, and uterus.

Not only the cause but the source of the secretion must be determined. Shultze devised the following method of demonstrating the source of the secretion: Following a vaginal douche of sterile water a large tampon of sterile absorbent cotton is placed against the cervix and left there for several hours. If the secretion comes from the uterus, it will collect upon the top of the tampon and can be examined for bacteria and other elements. If the secretion is mucus and in small amount, it must come from the cervix; if watery and abundant, it comes from the body of the uterus, rarely from the tubes—"hydrosalpinx profluens."

It is of importance to distinguish between a hypersecretion of the endometrium and a discharge due to some pathological lesion. This is often difficult, and may be impossible. Women will often complain of a leucorrhœa immediately preceding and following the menstrual flow. As a result of the congestion which precedes the monthly flow one or more days and continues a variable time after the cessation of the bloody flow, there is a hypersecretion of the glands sufficient to give rise to a seromucous discharge.

Leucorrhœa in Old Women. In the aged leucorrhœa has a more serious significance. The source is the vulva, vagina, and uterus. Senile vaginitis, vulvitis, and endometritis are the most common causes.

In the case of all unusual discharges from the genital tract of women advanced in years, whether the discharge be watery, bloody, purulent, or ichorous, there is always a suspicion of malignancy, and this thought is uppermost in the search for the underlying cause. Gonorrhœa infecting the aged rarely involves the uterus and

tubes. The infection is generally limited to the vagina and urethra. The irritation of a filthy and ill-fitting pessary will occasion a vaginal discharge.

Malignant growths give at first a watery discharge, which later becomes turbid, bloody, and foul-smelling. Cancer of the body of the uterus is more common after the menopause than is cancer of the cervix; therefore, in seeking the cause of a suspicious discharge occurring after the menopause it may be necessary to explore the uterine cavity with a curette. The discharge of a senile endometritis may simulate that of a malignant growth, and nothing short of an exploratory curettage with a microscopic examination of the scrapings will establish the diagnosis.

CHAPTER II.

PHYSICAL EXAMINATION.

Preliminary Measures. Having taken the history as outlined in the previous chapter, the next step is to determine by a general physical examination the possible bearing which some remote affection may have upon the pelvic organs.

Confining ourselves more particularly to the abdomen and pelvis, we will proceed to outline the method to be employed in a sytematic and thorough physical examination, and will describe the methods in the order in which practical experience has sanctioned their usage.

No invariable order can be adopted; circumstances will alter the general routine; but it is well to follow a definite method of procedure as closely as possible. The habit of making a systematic routine examination will not infrequently eliminate many errors in diagnosis. The examiner will not likely be content with the finding of any single explanation for the patient's complaint, but will seek further for other possible lesions. The writer recalls a case in which hemorrhage was the symptom complained of. On physical examination an interstitial fibroid was discovered. This was believed to explain the hemorrhage, and a hysterectomy was performed. In the cavity of the uterus was a cauliflower carcinoma, which had not been suspected. The examination had not been complete; when a single cause for the hemorrhage was discovered no further search was made. Had a more conservative operation been performed and the uterus not removed, the more serious of the lesions would have been overlooked.

In making a physical examination care should be taken for fear of injury to the structures examined; and the examiner will always endeavor to avoid inflicting pain. The more skilled the examiner the more careful and gentle he will be. A vaginal examination may cause great discomfort, and serious damage may be done to an inflamed mucous membrane and malignant growths. As the result of a bimanual examination roughly made, not only much

suffering may be caused, but cysts may be ruptured, abscesses may break into the peritoneal cavity, the gestation sac of an ectopic pregnancy may burst, adhesions may be torn, and in the use of the sound, curette, and speculum, serious and even fatal injuries may be sustained. While an exact diagnosis is desired in the first examination, it is seldom absolutely necessary and is frequently impossible. Certain procedures, such as catheterizing the ureters, must often be postponed for a subsequent examination

FIG. 1.

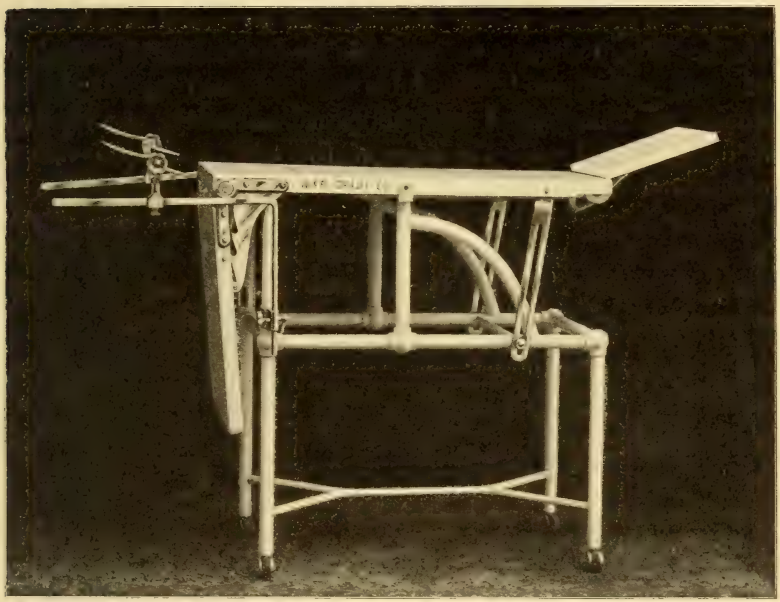

Examining table. (SCHMIDT.)

It is seldom necessary to make an examination during the menstrual period. It is not only objectionable to the patient, but at such times the pelvic viscera are congested and there is an added risk of injury. During the menstrual period the cervix is softened and somewhat patulous, and for this reason Simpson has advised the exploration of the uterine cavity during menstruation for the detection of foreign growths. The added risk of infection and injury at such times would seem to contraindicate such a practice.

We therefore elect the intermenstrual period for local examinations and treatments, for the reasons that the conditions then found

are more nearly normal and there is less risk of injury. Furthermore, it is best to make the examination at a time when the patient is in a condition the nearest possible to the normal. To this end the examination should not be made immediately after a full meal, or when for any reason the patient is exhausted and nervous.

Whenever possible the patient should be examined on a table with good light. Whatever table is used it should be of convenient width and length to permit the patient to assume any desired position. It should be so placed as to be approached by the examiner from all sides, and should be of convenient height to allow the examiner to proceed without assuming an unnatural and strained attitude. Fig. 1 shows a correct table for the making of examinations and operations. This table was designed by Dr. L. E. Schmidt, of Chicago, and has the special advantage of directing the buttocks well over the edge of the table, thereby favoring instrumental examinations of the bladder, vagina, and rectum.

We are often obliged to examine a patient on a bed or a couch. The author does not favor the examining chair because of its formidable appearance, its cumbersome weight, and the inconvenience with which the position of the patient is changed.

PLATE IV.

The abdominal walls are thick and greatly relaxed, free fluid has accumulated in the most dependent portions of the abdomen, causing bulging of the flanks.

PLATE V.

The abdomen is distended with free fluid in the peritoneal cavity. The flanks bulge. The abdomen is less pronounced than in Plate VI.

CHAPTER III.

EXTERNAL ABDOMINAL EXAMINATION. INSPECTION OF THE ABDOMEN.

It is well to expose the abdomen by removing the corset and all constriction about the waist. A sheet should cover the upper portion of the trunk to the waist line; another sheet should cover the lower extremities and hips, as seen in the accompanying illustrations.

The chief value of inspection is to determine abnormalities in the contour of the abdomen. We are to observe the size of the abdomen, its form, the site of a convexity or depression, the laxity or tension of the abdominal wall, the retraction or distention of the umbilicus, the presence of linea albicantes, pigmentations, distended veins, a hernia, skin diseases, peristaltic movements of the intestine, pulsations of the aorta as seen through the thin abdominal wall, and fetal and respiratory movements. Variations in the contour of the abdomen produced by tympany, ascitic fluid, tumors, and thick parietes are readily recognized by a competent observer.

In a thick, fatty abdominal wall the abdomen is flattened and the flanks protrude and sag downward when the patient lies on her back. Great transverse folds are formed. (See Plate IV.)

Free ascites with the patient in the dorsal position causes a bulging in the flanks and a flattening of the anterior abdominal wall. With change in position of the patient the contour of the abdomen is altered. (See Plate V.)

In ovarian cysts the abdomen is irregularly ovoid. In the very large cysts, or where the pedicle is long and the cyst is freely movable, the abdomen may be evenly distended. When the abdominal wall is thin and the cyst large and multilocular, it is sometimes possible to see the irregular elevations through the abdominal wall. (See Plate VI.)

Large uterine fibroids may evenly distend the abdomen, but more frequently cause an irregular protuberance. (See Plates VII. and VIII.) In interstitial fibroids the abdominal enlargement is inclined to be more median than in ovarian cysts.

In excessive distention of the abdomen the skin is white and shiny, and often streaked with irregular red lines.

CHAPTER IV.

PALPATION OF THE ABDOMEN.

THE abdomen is best palpated with the patient in the dorsal position. The head and chest if elevated will diminish the field of exploration. When it is desired to note the effect of change in position upon the abdominal contents, the erect, the knee-elbow, or the lateral position may be assumed.

Preliminary to all abdominal and pelvic examinations the bladder and rectum must be empty and all constricting bands of clothing removed. The examiner's hands should be warm and the finger-nails cut short. Both hands should be used. They should be laid gently upon the abdomen, the pressure steady and firm, avoiding all sudden and unexpected movements. The patient should be instructed to breathe quietly, with the mouth open. Her attention may be drawn from the examination by asking questions concerning some other portion of her body. In this manner, with thin and relaxed abdominal walls, it may be possible to palpate the projecting vertebræ, the posterior wall of the pelvis, the promontory of the sacrum, and the pulsating aorta.

Thick and tense abdominal walls may prevent satisfactory palpation of the abdomen, necessitating an anæsthetic. Very often by care and patience the tendency to contract the abdominal walls may be overcome without resorting to anæsthesia. Remember, that it is possible to do harm by rupturing collections of blood, cysts, and abscesses, and by exciting a limited or latent inflammation.

For convenience of description the abdomen may be divided into quadrants (Fig. 2).

These are named respectively the right upper, the left upper, the right lower, and the left lower quadrant.

Before determining the nature of a swelling, it is necessary to identify it either as growing from the pelvis or from the abdomen, and to demonstrate its relation to the viscera and the abdominal wall.

It is well to follow a routine system, beginning below and proceeding upward. If the preliminary step of emptying the bladder

PLATE VI.

The abdomen is evenly distended by a large ovarian cyst. The abdomen is symmetrically distended. There is no bulging of the flanks.

PLATE VII.

The abdomen is distended by a single large interstitial fibroid of the uterus. The tumor is firm, smooth, and located in the median line.

and bowels is taken there should be no confusion with a fecal tumor and distended bladder. All tumors of the abdominal wall move with the wall, and may be lifted up with it. The connection of a tumor with the skin is recognized by inability to lift the skin apart from the tumor.

FIG. 2.

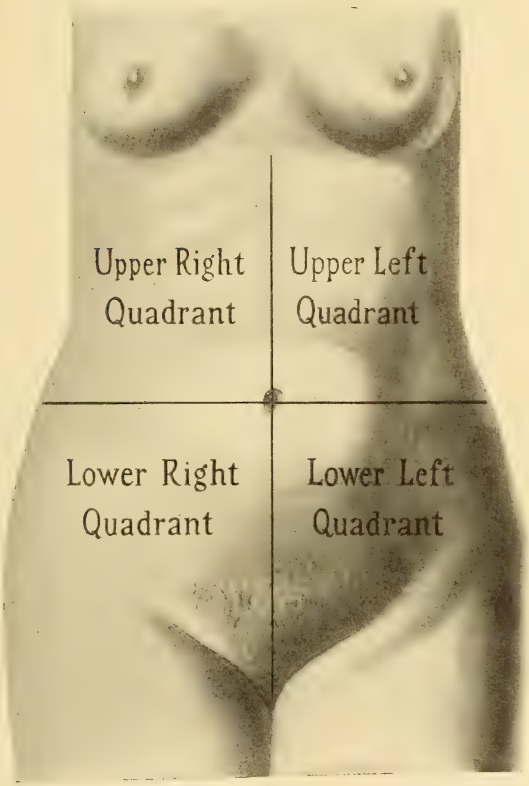

Diagram of the areas into which the abdomen may be divided.

All intraperitoneal organs and viscera move with respiration. The nearer the diaphragm the greater the excursion. If the organ or tumor is adherent or is incarcerated the excursions will be limited. These isochronous respiratory movements are readily recognized by the hand, and under favorable conditions may be recognized by inspection. An organ or tumor lying underneath the peritoneum, if protruding into the peritoneal cavity, may be affected by respiratory movements. Such, for example, is the case

with a movable kidney and a pedunculated subserous fibroid. All tumors arising in the pelvis tend to grow upward.

The contour of the swelling and its consistency are determined by palpation. It is important to recognize periodical alterations in consistency in connection with the differential diagnosis between pelvic and abdominal swellings and a pregnant uterus. No swelling other than a pregnant uterus contracts intermittently. The softening of a tumor speaks for a degenerative process. When the swelling is deep-seated or the abdominal wall thick and tense, it may be impossible to determine the consistency and contour of the swelling. Fluctuation is best detected by percussion associated with palpation, and when elicited speaks for the presence of fluid. According to the readiness of response to impulse, we may judge to some extent of the consistency of the fluid. The examiner is often at a loss to decide whether or not fluid is present. Tense cysts may not fluctuate, and, on the other hand, soft tumors may appear to fluctuate.

The connection of the swelling with other tumors and viscera may be determined by palpation. The exact location of the tumor is noted, and by palpation is often traced to a particular organ. By changing the position of the patient we may gain additional information regarding the attachment of the swelling. Spencer Wells has pointed out that non-adherent pedunculated tumors of the pelvis gravitate into the abdominal cavity when the knee-chest position is assumed.

PLATE VIII.

A multiple fibroid tumor of the uterus unevenly distending the abdomen. The abdominal wall is thin, permitting the irregular contour of the tumor to be distinctly seen.

PLATE IX.

Hernia of a Pregnant Uterus.
A five months' pregnant uterus forming an abdominal tumor protruding between the separated recti muscles.

CHAPTER V.

PERCUSSION OF THE ABDOMEN.

THE abdomen is best percussed with the patient in the dorsal position. When it is desired to demonstrate by percussion the change in position of a tumor or fluid the patient may assume any required position.

Since the normal percussion tone of the abdomen differs according to the contents of the stomach and bowels, the results obtained by percussion are not altogether reliable. The normal range of motion in the abdominal and pelvic viscera also adds to the uncertainty of the conclusions arrived at by percussion. Furthermore, we cannot compare the percussion note on corresponding sides, as is done in percussing the chest.

In proceeding it is well to go over the entire abdomen in a systematic manner. If firm pressure is made by the fingers the intestines, unless adherent, will be pushed aside, and the underlying organ or tumor can be directly percussed. Percussion is of the greatest value in demonstrating the presence or absence of intestine lying in front of the organ or tumor. All other conditions are better elicited by palpation.

By reference to the accompanying diagrams it will be seen that in ascites (Plates IV. to IX.) the dull percussion note of the fluid is found in the most dependent portion of the abdomen, and the tympanitic note of the intestine is found above the fluid. Where the mesentery is short or the bowel fixed by adhesions, the above findings are not elicited. If gas does not distend the intestine, or if fecal matter fills the intestine, the tympanitic note is not elicited in contrast to the dull note of the fluid.

Where the ascitic fluid greatly distends the abdomen there may be no change in the area of dulness. Where there is a small amount of ascitic fluid the intestine may float to the side of the abdomen and give a tympanitic note together with fluctuation.

When an ovarian cyst (Plate VI.) distends the abdomen the percussion note is dull in front and the tympanitic note of the intestine is found low in the sides.

CHAPTER VI.

AUSCULTATION AND MENSURATION OF THE ABDOMEN.

Auscultation is of little value except in the diagnosis of pregnancy. Other than the sounds referable to the fœtus, the placenta, and the pregnant uterus, there may be heard over the abdomen the maternal heart tones, pulsation of the aorta, murmur of abdominal aneurisms, gurgling of gas in the bowel and stomach, and the friction sounds caused by the rubbing together of rough surfaces.

The patient should be in the dorsal position, with the legs sufficiently flexed to relax the abdominal walls, yet not to the extent of interfering with the examination. The ear or stethoscope may be employed, preferably the latter.

The uterine bruit is not to be mistaken for the bruit that is heard in about 50 per cent. of uterine tumors and occasionally in ovarian cysts. A similar bruit has been heard over the tumors of the liver, spleen, and the retroperitoneal spaces. No such sound has been heard over tumors of the kidney.

Mensuration is of some importance in the diagnosis of abdominal swellings. It finds its greatest service in obstetric practice. It is a fairly precise means of determining the rate of growth of an abdominal swelling.

Exact measurements are difficult, because of the variable degree of distention of the intestine and the shifting of the abdominal tumor. There must be a convexity of the abdomen; otherwise, comparative measurements would be of no value.

An ordinary tape-measure will answer the purpose. The measurements to be taken are: the greatest circumference, the circumference at the level of the umbilicus, the distance from the ensiform cartilage to the pubis, from the umbilicus to the anterior-superior spine of the ilium on either side, and the distance from the linea alba to the spine of the vertebræ. It is important for the purpose of comparison that the same position be assumed in making subsequent measurements.

CHAPTER VII.

EXAMINATION OF THE EXTERNAL GENITALS.

THE routine practice of inspecting the external genitals is unnecessary, and should be discountenanced. When required the Sims position or the ordinary lithotomy position is assumed. The sheet is drawn about the lower extremities and tucked about the vulva in such a manner as to make the least possible exposure. The labia are held apart by the thumb and index finger for the inspection of the vestibule, urethral opening, hymen, and perineum.

When gonorrhœa is suspected the urethra and Bartholinean glands should be inspected. When these structures are infected, and particularly if pus can be expressed from the urethra, the diagnosis of gonorrhœal infection amounts to a moral certainty.

Recent injuries should be inspected, but long-standing injuries to the pelvic floor can be detected and a fair estimate of their extent gained from the sense of touch alone.

Malformations, pigmentations, varix, œdema, and all the new formations should be examined.

DIGITAL EXAMINATION OF THE INTERNAL GENITALS.

The hidden position of the internal genitals makes it necessary to examine them through one or more of the natural openings—rectum, bladder, and vagina. Until the end of the eighteenth century the vaginal route was the only one used. Little progress was made in the diagnosis of diseases of the internal genital organs until the introduction of combined methods of examination were introduced by M. Puzos, in the eighteenth century, and revived and elaborated by Sir James Y. Simpson. By the combined examination we have the only means of determining the size, position, consistency, mobility, sensitiveness, and connections of the pelvic organs.

Digital Examination of the Vagina. This is made with the patient in the Sims or lithotomy position, rarely in the erect or

knee-chest position. Thin rubber gloves or finger-cots are advised, not only to prevent infection of the patient, but as a protection to the examiner. With some practice the gloves will not embarrass the sense of touch to any considerable extent. When the bare hand is used it should be scrubbed with soap and water and disinfected with lysol. The most elegant lubricant for the examining finger is scented green soap. Vaseline is not desirable, because of the odor from the secretions, which clings to the fingers in spite of vigorous scrubbing. In an ordinary digital examination of the vagina it is unnecessary to expose the vulva; the examination may be made in a perfectly satisfactory manner under cover of a sheet.

Fig. 3.

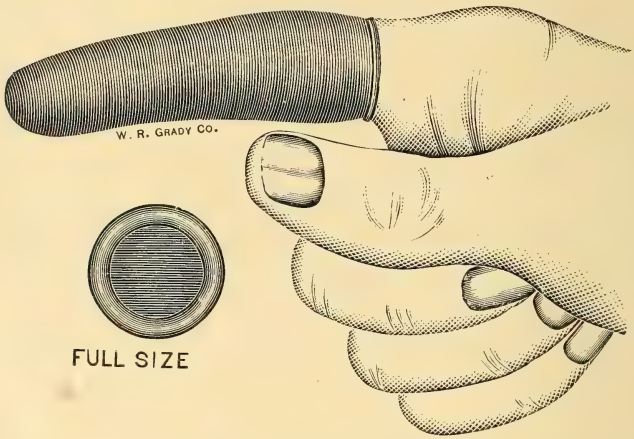

It should be the invariable practice of physicians to wear a thin rubber glove or finger-cot (Fig. 3) in making vaginal and rectal examinations. This is done not only as a matter of cleanliness in preventing septic infection of the genital organs, but as well to prevent infection of the examining finger. A well-known authority on skin and veneral diseases told me that an average of one physician a week came to his office with a syphilitic infection acquired in making examinations. This appalling statement should make us very cautious.

The attitude of the examiner should be carefully considered. Fig. 4 shows the correct position. The examiner stands at the end of the table; one foot rests upon a low stool; the elbow of the examining arm rests upon the knee, thereby permitting free motion in the forearm and hand.

The **choice of hand** will depend in part upon the comparative utility of the two hands, but more upon the habit acquired. As a general thing, the right side of the pelvis is best palpated with the

Fig. 4.

Combined vaginal examination.

left hand, and the left side with the right hand. In the early experience of the examiner it is best to cultivate the sense of touch in a single hand, and in later years, as there are opportunities for more experience, either hand may be used, with equal expertness.

Shall One or Two Fingers be Used in Digital Examinations of the Vagina? Where two fingers can be introduced without discomfort

Fig. 5.

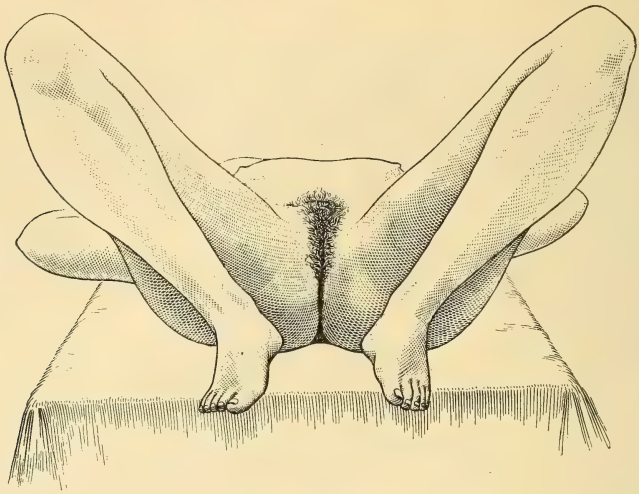

Lithotomy position.

Fig. 6.

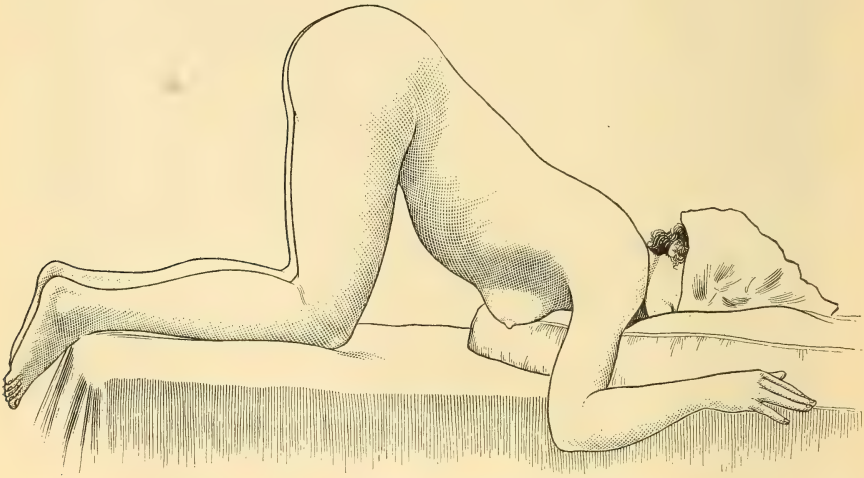

Knee-chest position.

to the patient, the two will be found more effective than one. In order that the fingers may be introduced with the least possible annoyance to the patient, the labia are separated by the thumb and

FIG. 7.

Erect position.

index finger. The middle finger of the opposite hand is inserted into the vulvar opening, with the palmar surface resting upon the perineum. Firm pressure is made by the finger upon the perineum. The vulvar outlet is thereby deepened, and into it the index finger can be readily inserted. The two fingers are now passed into the vagina, making firm pressure upon the perineum and avoiding pressure upon the clitoris and urethra. When the fingers are fully inserted the palm of the hand is turned upward. When the vulvar outlet is small, the mucosa sensitive or the hymen intact, a single finger should be employed. Where pain is caused by inserting the finger, it is well to ask the patient to bear down while the examination is being made.

The following conditions are determined by a simple vaginal examination: the size, form, and position of the vulva, vagina, and vaginal portion of the cervix; the condition of the hymen, whether present or absent, perforate or imperforate; the integrity of the pelvic floor; the presence of new-growths in the vulva, vagina, and vaginal portion of the cervix; sensitiveness and fulness in the vault of the vagina and the capacity of the pelvic outlet.

The knee-chest position is especially used when it is desired to do away with intra-abdominal pressure for the purpose of permitting the uterus and freely movable pelvic tumors to rise out of the small pelvis.

The erect position is practised chiefly in determining the degree of prolapsus of the uterus.

After concluding the examination the finger is withdrawn and the secretion on the finger inspected.

The Combined Vaginal Examination (Bimanual). The advantages of a combined examination over a simple vaginal or rectal examination are evident. The combined method may be regarded as the most valuable of all physical explorations of the pelvis. Various combinations may be utilized, they being designated as abdomino-vaginal, abdomino-rectal, abdomino-vesical, abdomino-vesico-vaginal, abdomino-vesico, and rectovaginal.

As preliminary steps to the examination the bladder and rectum are emptied, all clothing made loose about the waist, and the patient placed in the lithotomy position.

Abdomino-vaginal Examination. In order that this method of examination be properly performed, the vagina must be patent and its walls relaxed. Furthermore, it is essential that the abdominal

walls be sufficiently thin and relaxed to permit of depression. Where there is much fat in the abdominal wall, a pendulous abdomen, or tenderness and pain on pressure, little or nothing can be accomplished by this method without the aid of an anæsthetic. In extreme elongation of the vagina, and when there is an excessive deposit of fat in the external genitals and thighs, it may be impossible to palpate high in the vault of the vagina.

The bimanual examination is best performed in the lithotomy or dorsal position, with the thighs slightly flexed. Little can be gained from such an examination with the patient in the erect or knee-chest position. The side positions, while awkward and ill-adapted for general use, are of special service in testing the mobility of the pelvic viscera and tumors.

Fig. 8.

Sims' position.

All that has been said in describing the digital examination of the vagina concerning the choice of hands, the use of one or two fingers, and the manner of introduction of the fingers, will apply to the combined method of examination. The function of the hand upon the abdomen is to steady the pelvic organs while palpated by the fingers in the vagina. A complete outlining of the pelvic viscera by the external hand is not possible, consequently light pressure is all that is required, and has the advantage of not exciting the abdominal muscles to contract. The tips of the fingers are directed toward the ensiform cartilage and gradually made to compress the abdominal wall at a variable point above the symphysis pubis. With a thin, flaccid, abdominal wall, and in the absence of large swellings, the external and internal fingers may be approxi-

mated in front of the uterus with only the vaginal wall, the bladder, and the abdominal wall intervening. Under most favorable conditions the fingers may be similarly approximated behind the uterus. Lifting the uterus forward and upward by the finger in the vagina the uterus may be palpated over the entire surface of the body, and at the same time the vaginal and supravaginal surface of the cervix may be outlined by the finger in the vagina. In anteversion of the uterus the anterior surface of the uterine body is

Fig. 9.

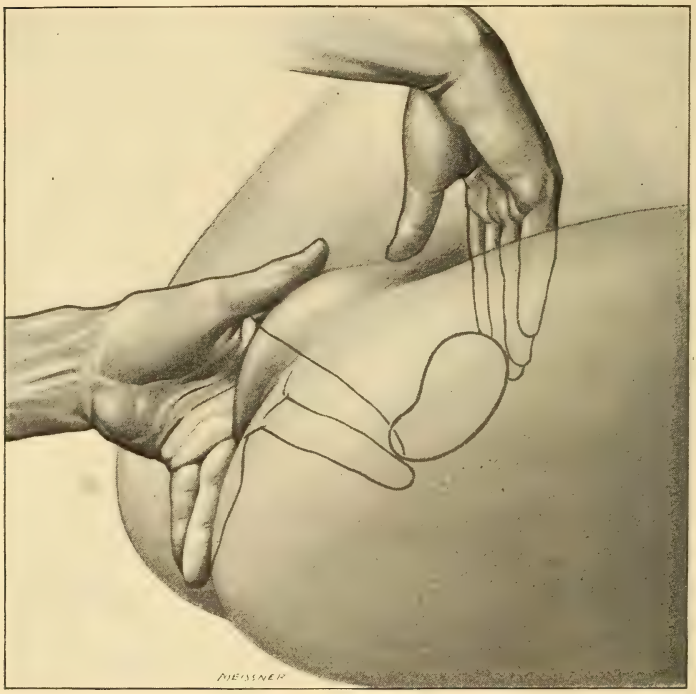

Abdomino-vaginal examination.

best palpated by the finger in the vagina, and the posterior surface by the external fingers. In retroversio-flexion the posterior surface of the uterus is best palpated by the finger in the vagina and the anterior surface by the external fingers. When the uterine body is enlarged it may be readily outlined in the conjoined examination without elevating the uterus by pressure from below.

Under favorable conditions it is possible to determine the position of the uterus; its size, form, sensitiveness, consistency, and mobility.

PLATE X.

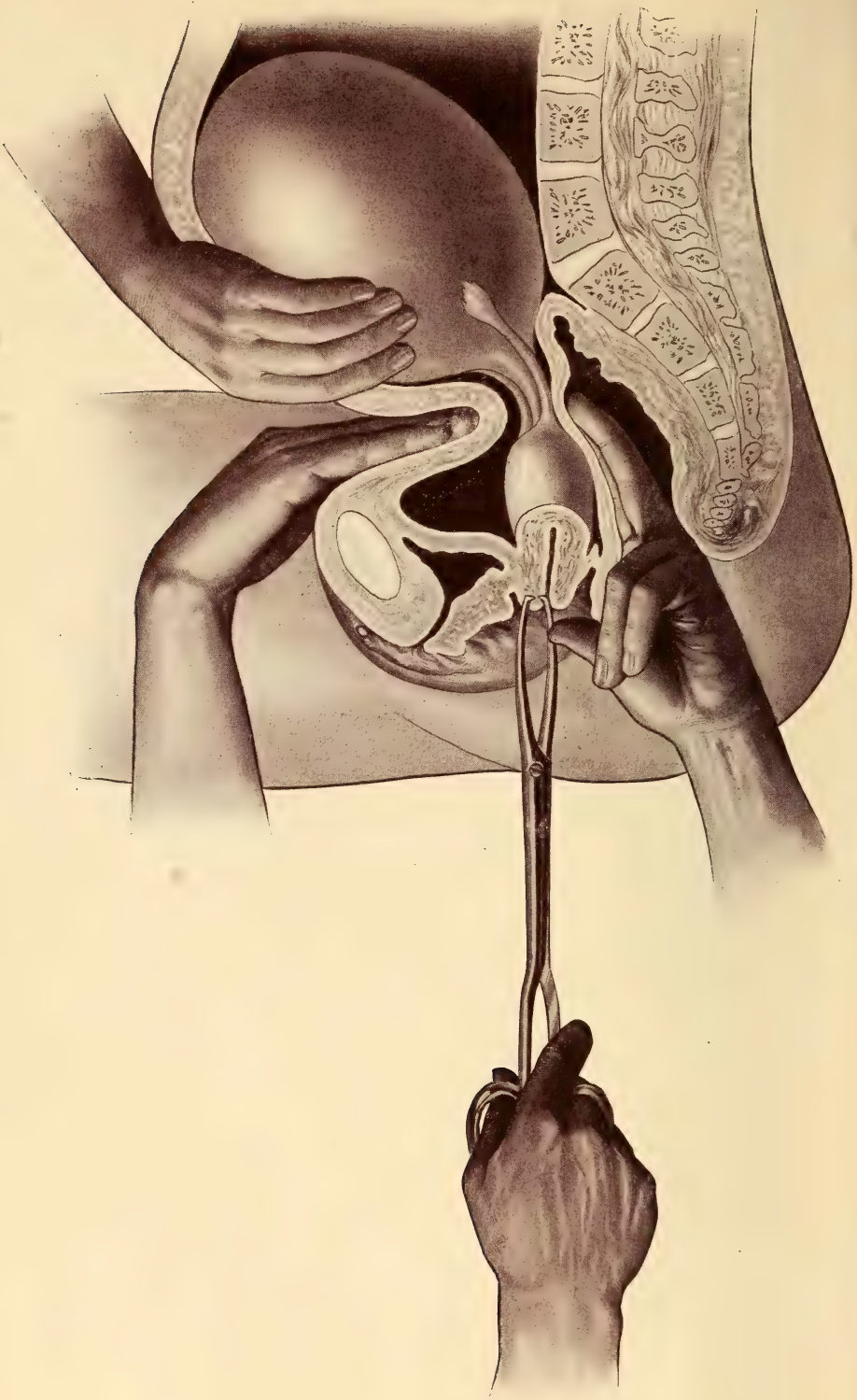

Palpation of the Pedicle of an Ovarian Cyst.

Two fingers are inserted into the rectum and the opposite hand over the abdomen. An assistant makes traction upon the cervix with a vulsella forceps while a third assistant grasps the cyst with both hands and draws it upward. In this manner the pedicle is put upon the stretch and can be engaged between the fingers in the rectum and those on the abdomen.

No manipulating should be done until the position of the uterus is determined, and this is largely accomplished by vaginal touch. Pressure by the examining fingers may correct or exaggerate a malposition of the uterus. A preliminary vaginal examination will serve to eliminate such errors. For details of the method of examination in displacements of the uterus, see Chapter XXI.

The Fallopian tubes, under ordinary conditions of health, cannot be palpated in a combined examination. With conditions most favorable, in which the abdominal walls are thin and relaxed, the vaginal walls distensible, and the tubes in their normal position, it is possible to palpate the normal tubes; they are then felt as thin, round cords which roll between the examining fingers.

The normal ovaries are palpated with difficulty, and are recognized by their position, size, form, and sensitiveness. The ovarian ligament is seldom felt.

The pelvic peritoneum and cellular tissue should be explored as far as possible to discover undue sensitiveness, cicatricial contractions, inflammatory exudates, tumor formations, and collections of blood.

The rectum on its anterior wall may be explored through the vagina and something learned of its sensitiveness, inflammatory infiltrations, foreign growths, and fistulous openings. More satisfactory is the rectovaginal method of examination.

The base of the bladder may be palpated through the anterior vaginal wall. Tumors, calculi, inflammatory infiltrations, new-growths, and tenderness from whatever cause can be determined with some degree of satisfaction.

A rough estimate of the capacity and deformity of the bony pelvis can be made by the combined method.

The *abdomino-vaginal examination* is of greatest service in the differential diagnosis of pelvic tumors. By the combined method their size, form, consistency, rate of growth, relative position, mobility, and connection with other structures are determined. When the tumor is large and in the abdominal cavity the method of Schultze may be employed with advantage. In addition to the customary bimanual examination an assistant draws the abdominal tumor upward while contraction is made upon the cervix with a vulsella forceps. (See Plate X.)

The tumor may so closely press upon the uterus or be so closely adherent to it that a line of distinction between the two cannot be

recognized by the examining finger. The variations in consistency and form, together with the use of the uterine sound, may determine the relations. Swellings of the tubes and ovaries are at first to be differentiated from the uterus; but later, as they increase in size and become displaced behind or to the side of the uterus, they may be distinguished with difficulty. Likewise pelvic exudates may intimately blend with the uterus. Frequently bodies apparently immovable in one position may be movable in another.

Examination under narcosis has many advantages. Kelly lays down the following rules for the use of anæsthesia in the diagnosis of diseases of women:

1. Where doubt exists after the ordinary bimanual examination.
2. Where a patient comes to a specialist after having had treatment for a long time at other hands without improvement.
3. In all cases of pelvic peritonitis involving one or both ovaries or tubes without producing any gross tumor, when the use of the anæsthetic is to find out the extent of the disease.
4. Always in unmarried women.

Nitrous oxide will serve admirably in the majority of cases. When the examination must be prolonged, as in the use of the cystoscope or curette, either chloroform or ether should be used.

It should be a rule to which there are no exceptions, that after the patient is asleep and before the operation is begun a thorough bimanual examination should be made.

Under anæsthesia a higher reach may be gained by *invaginating the pelvic floor*. This is accomplished by making firm pressure upon the vulva and perineum with the examining hand. In so doing a gain of one to two and a half inches may be made. Additional pressure may be made by supporting the elbow of the examining arm against the hip and throwing the weight of the body against the arm.

Digital Examination of the Rectum. In point of efficacy, digital examination of the rectum and, through the rectum, of the pelvic structures ranks next to the vaginal method, and in some conditions is to be preferred.

(*a*) **The Simple Rectal Touch.** When for any reason a digital examination of the vulva cannot be made, the internal genital organs must be examined per rectum. Such conditions are a congenital or acquired absence of the vagina, a narrow, shallow vagina, inversion of the uterus, and vaginismus. A rectal examination is

of special advantage not only when the vaginal examination is precluded, but in all lesions in the rectovaginal space lying on the posterior pelvic wall.

The position of the patient should be the lithotomy, knee-elbow, or the Sims. One or two fingers and, under anæsthesia, the whole hand may be used. In passing the finger into the rectum the tonicity of the sphincter is noted. Fissures, polyps, hemorrhoids,

Fig. 10.

Abdomino-rectal examination.

and new formations are detected. Through the anterior wall of the rectum is felt the posterior vaginal wall, the cervix, and part or all of the posterior surface of the uterus; the base of the broad ligaments, frequently the tubes and ovaries when enlarged and prolapsed, and the uterosacral ligaments. Through the posterior wall of the rectum is felt the sacrum and coccyx. Because of the thinner and more distensible bowel wall the structures occupying the posterior segment of the uterus are more easily reached than

they are through the posterior vaginal vault. The cervix projecting backward is not to be mistaken for the body of the uterus.

(*b*) **Abdomino-rectal examination** (bimanual) is a method carried out in general as is the abdomino-vaginal examination. In virgins with an intact hymen it is the method of choice. All conditions recognized by a simple vaginal examination are more clearly palpated by the combined method.

Fig. 11.

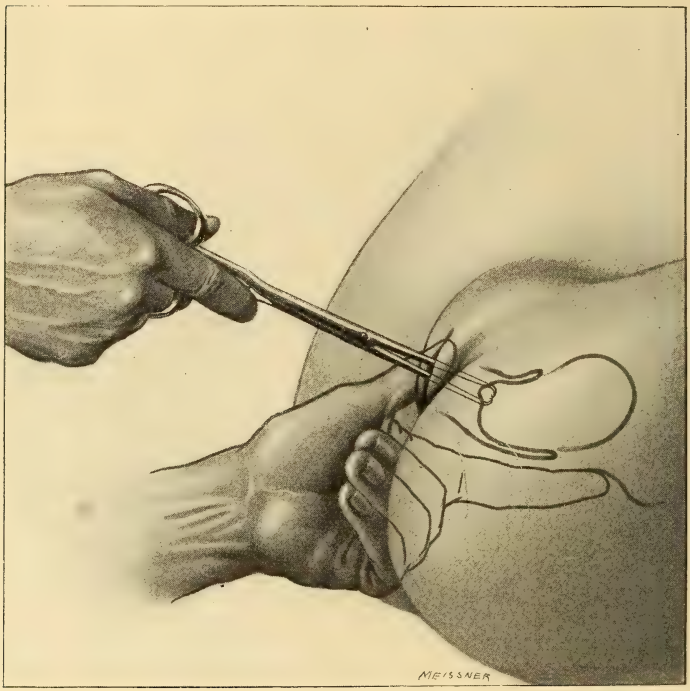

Rectal examination with traction upon the cervix by a vulsella forceps.

The examination may be embarrassed by coils of intestine wedged into the cul-de-sac of Douglas. Where such difficulties exist and the bowels are not adherent, they may be displaced by placing the patient in the knee-chest position. A Sims speculum is inserted into the bowel, allowing the air to rush in and balloon the rectum, when the bowel will fall forward out of the cul-de-sac. The patient is then placed in the dorsal position and the examination continued.

TRACTION UPON THE UTERUS IN THE ABDOMINO-RECTAL EXAMINATION by vulsella forceps will greatly facilitate the examination where the uterus lies either too far forward or too high to be readily reached by the finger in the rectum. At the same time pressure may be made from above downward and backward upon the uterus. The vulsella forceps are held by an assistant while the operator makes the examination. No great amount of force should be applied to the uterus for fear of tearing adhesions.

FIG. 12.

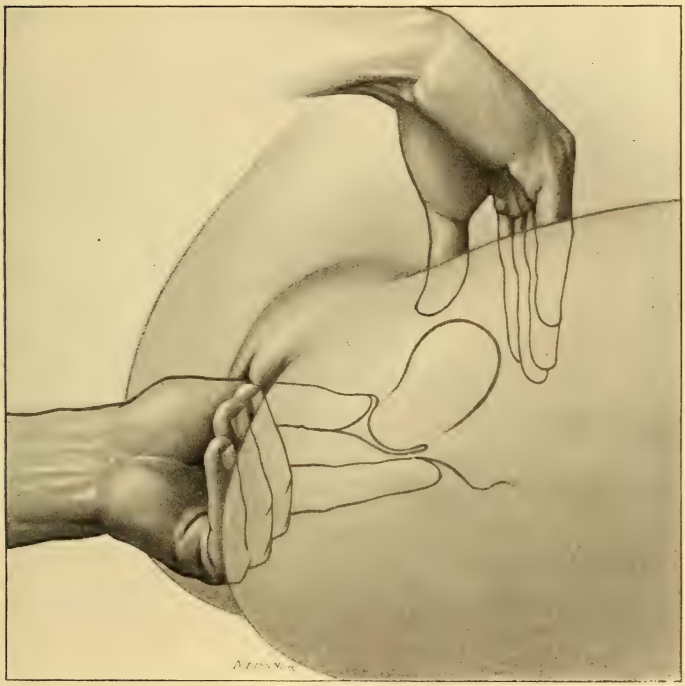

Abdomino-vagino-rectal examination. The right hand depresses the abdomen, the thumb of the left hand is inserted into the vagina, and the index finger into the rectum.

(*c*) **Abdomino-vagino-rectal examinations** are seldom called for. While effective, they are unpleasant to patient and physician. The finger should never be withdrawn from the vagina and inserted into the rectum without cleansing.

Digital examination of the bladder, either simple or combined with vaginal and abdominal methods (abdomino-vesical, abdomino-

vesicovaginal), will not be considered. The method has been replaced by other more efficient and less objectionable methods.

Pelvimetry. It is seldom that pelvic measurements are taken of a gynecological case. This is but an evidence of the illogical separation of obstetrics and gynecology. Not a few of the pelvic

Fig. 13.

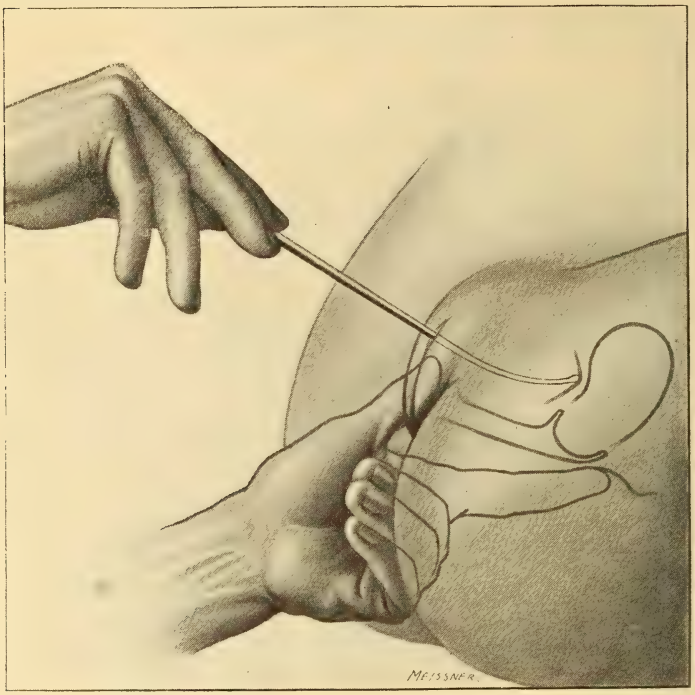

Vesicorectal examination. A sound is passed into the bladder and the index finger into the rectum. In this manner the presence or absence of the uterus is determined.

lesions are the result of deformities of the bony pelvis. For a detailed description of the deformities of the pelvis and their measurements, see text-books on obstetrics. For practical purposes the measurements between the anterior-superior spines of the ilium, between the trochanters, between the widest points in the crest of the ilium, and Baudelocque's diameters are all that are required.

CHAPTER VIII.

THE VAGINAL SPECULUM.

For direct inspection of the vagina the speculum is used both in diagnosis and treatment. For diagnostic purposes it has a limited field of usefulness; digital exploration will alone serve the purpose in a large proportion of cases.

Fig. 14.

Sims' duck-bill speculum.

Fig. 15.

Sims' vaginal depressor.

The lithotomy position is the one of choice. The rectum and bladder must be emptied. Before introducing the speculum a digital examination of the vagina should be made to locate the cervix for the purpose of knowing the proper direction in which to direct the speculum in exposing the cervix.

The varieties of specula in common use are the Sims, Simons, bivalve, and tubular.

Sims' speculum is used with best advantage in the lateral position of Sims. The vaginal outlet is spread open by the thumb and index finger of the left hand, while the right hand introduces the

speculum. The blade is passed between the fingers spreading the vulva, and is allowed to glide over the perineum to the vault of the vagina. With the placing of the speculum the air rushes into the

Fig. 16.

Emmet's tenaculum.

Fig. 17.

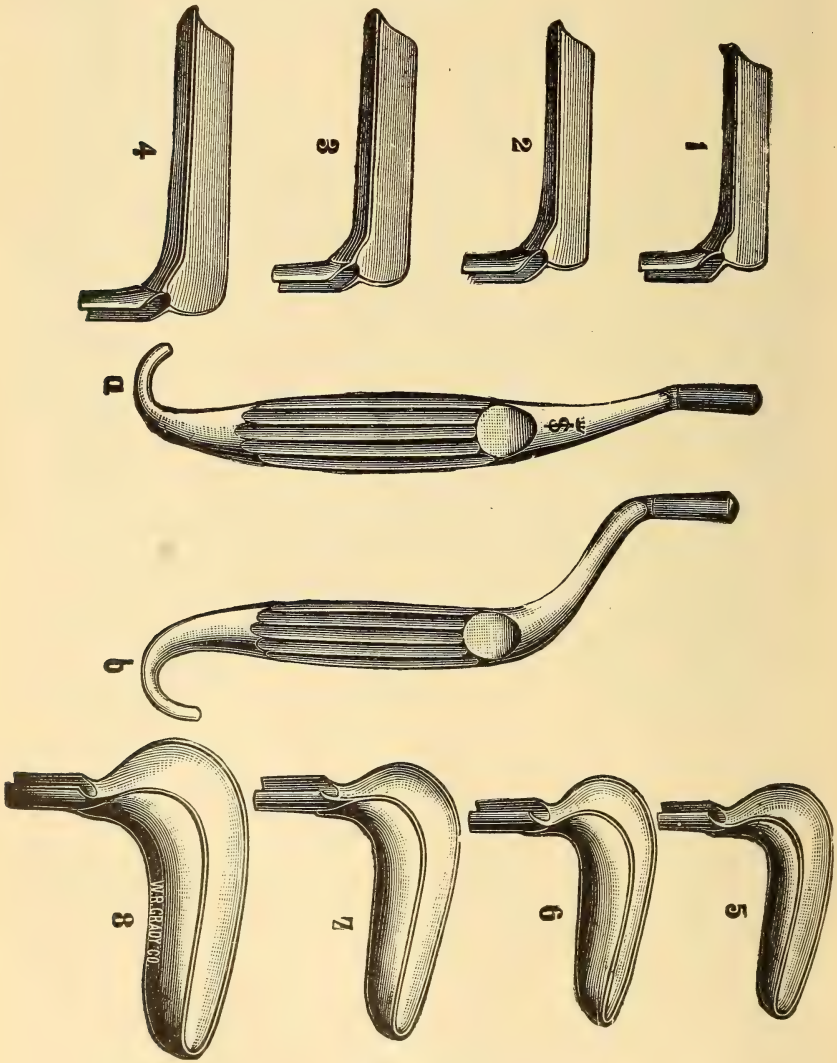

Bozeman's specula.

vagina and balloons it. In this manner a direct inspection of the vaginal mucosa is made possible. Firm and steady traction is made backward upon the perineum in exposing the cervix. The Sims speculum was originally used in the knee-elbow position, but is now almost invariably used in the Sims or left lateral posture.

When the vagina is deep and the walls relaxed, in addition to the speculum, it is essential to use some sort of a depressor with which to expose the cervix by holding the walls of the vagina apart.

When the cervix is directed backward and is not readily exposed to view, it may be hooked by a tenaculum and drawn forward. Such manipulations must only be carried out under the guidance of the eye or finger, for fear of hooking the vaginal wall instead of the cervix.

Simons' speculum is a device not unlike that of Sims, having a single spoon instead of two. It has an advantage over Sims' speculum in that there is no second handle to interfere with the manipulation of the instrument.

A combination of spoons of various shapes and sizes adjusted to separate handles was devised by Bozeman and others (Fig. 17).

For the purpose of exposing the cervix the lateral walls of the vagina may require retraction.

The bivalve speculum (Fig. 19) is in general use, though inferior in every respect to the Sims and Simons. Cusco's lateral modification is simple and easily manipulated.

The instrument consists of two blades, taking the form of a beak. The articulated outer end is manipulated by a screw which spreads the valves to an acute angle. The instrument is closed and inserted by its smaller diameter, and when inserted the instrument is turned so that the screw points toward the perineum. As the blades are separated they tend to distend the vagina, and the cervix engages between the blades. The great objection to this instrument is that the anterior and posterior walls of the vagina are obscured by the blades, and the traction upon the vaginal walls separates the lips of the cervix to an unnatural degree. The one great advantage is the fact that it is a self-retaining speculum, requiring no assistant to hold it.

In withdrawing the instrument care must be exercised for fear of catching folds of the mucous membrane; the instrument must be withdrawn slowly and the screw gradually loosened as the speculum is retracted.

The tubular speculum (Fig. 20) is seldom used. It is made of metal, wood, celluloid, glass, or vulcanite. It may be introduced in the lithotomy, knee-chest, or Sims position. It can only expose the cervix, and this is done with difficulty.

Fig. 18.



Péan's vaginal retractor.

Fig. 19.



Cusco's vaginal speculum.

The self-retaining speculum (Fig. 21), composed of a spoon-like blade and a weighted handle, will be found of the greatest service in making exploratory curettage and in excising pieces from the cervix. Currier's weighted self-retaining speculum with two adjustable blades is an admirable device.

Too much emphasis cannot be placed upon the necessity of surgical cleanliness in the use of vaginal specula. Some operators who scrupulously sterilize all instruments intended to be introduced

FIG. 20.



Ferguson's tubular speculum.

FIG. 21.

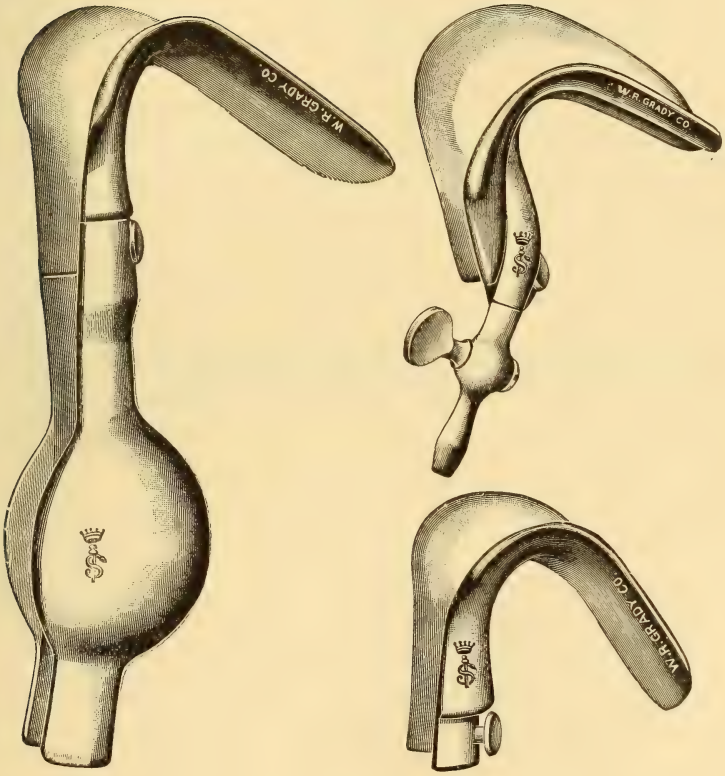

Currier's weighted speculum.

into the uterus carelessly use a speculum after little or no cleansing. Gonorrhœal infection is frequently transmitted in this manner. To fail to sterilize the vaginal speculum before using is criminal negligence.

CHAPTER IX.

THE VULSELLA.

Traction upon the cervix is made with the vulsella forceps. When the uterus and its attachments are in a normal position the cervix can be drawn almost to the vulvar outlet. Little or no pain is caused by the grasp of the forceps upon the cervix.

A vaginal speculum need not necessarily be used in grasping the cervix with the vulsella forceps; the finger may be used as a guide.

As an aid to diagnosis the vulsella forceps are used to make traction upon the uterus, bringing it and adjoining structures within easier reach of the examining finger in the vagina or rectum.

Fig. 22.



Pozzi's tenaculum forceps.

In determining the relation of large tumors and swellings to the uterus, it is of advantage to steady the uterus by making traction downward upon the cervix. The forceps are held by an assistant while the examiner manipulates the tumor. If tumor and uterus move together there must be an intimate connection between the two.

In differentiating an erosion from an eversion of the cervix the two lips of the cervix are grasped by the vulsella forceps and the lacerated edges approximated. If the red surface disappears an eversion is diagnosed; if there still remains a red zone about the external os an erosion must be present.

In removing sections from the cervix for diagnostic purposes the cervix is grasped by the vulsella forceps.

Forcible traction upon the cervix is not without danger. It is possible to rupture the peritoneum and to tear through adhesions. Acute inflammatory lesions of the pelvis are absolute contraindications for the use of the vulsella forceps lest the inflammation be excited to further extension. In the pregnant uterus severe hemorrhage may be brought on by the application of the forceps.

In removing the vulsella care is to be exercised for fear of injuring the cervix or wounding the patient. Superficial sutures of catgut or a vaginal pack with iodoform gauze may be placed if hemorrhage is severe.

CHAPTER X.

UTERINE DILATORS.

For the purpose of exploring the uterine cavity with the finger and curette the cervix must be dilated. *Hegar's* or *Kelley's dilators* are recommended for general use. By them the cervix is symmetrically dilated, with a minimum amount of trauma.

Fig. 23.

Hegar's uterine dilators.

FIG. 24.

Ellinger's dilator.

FIG. 25.

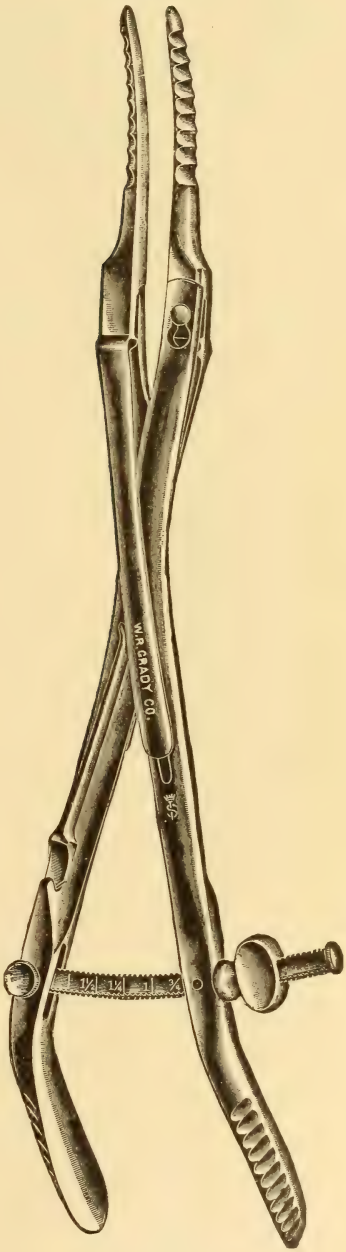

Goodell's dilator.

The vaginal speculum may or may not be used to expose the cervix. The anterior lip of the cervix is grasped by a vulsella forceps. The dilators are sterilized by boiling, and lubricated with sterilized glycerin or boroglycerin. Beginning with a size that can be easily passed through the cervical canal, one after another of the sounds is passed until the cervix will admit the index finger.

The utmost care must be exercised in passing the dilators for fear of losing control of the instrument and accidentally forcing it through the uterine wall. To eliminate this danger the depth and direction of the uterus should first be ascertained by the sound. The dilators are then grasped by the thumb and index finger at a point about one inch short of the length of the uterus.

FIG. 26.

Sea tangle tent.

FIG. 27.

Sponge tent.

FIG. 28.

Tupelo tent.

Instruments of divulsion, such as Palmer's, Goodell's, and Ellinger's, are commonly used in America. Only moderate force should be applied in dilating with these instruments for fear of tearing the cervix. They do not find favor in Europe.

Tents are seldom used of late. They are not only slow and uncertain in their action, but are a source of danger from infection. They are made of sea tangle, sponge, and tupelo. A detailed account of their manner of insertion and use is to be found in text-books on gynecology.

Where great resistance is offered to the dilators, a unilateral or bilateral incision in the cervix may be made. Digital dilatation of the cervix is sometimes possible shortly after abortion or full-time labor. By first inserting the little finger, then the index, and, lastly, the middle finger, the cervical canal may be safely and efficiently dilated.

CHAPTER XI.

THE UTERINE SOUND.

ÆTIUS speaks of using the sound to measure the length of the vagina. Sir James Y. Simpson introduced the modern sound as a material aid in the diagnosis of lesions involving the uterus. Simpson does not deny that the sound was used for exploration and measurements of the uterus long before his time. Certain it is that Wierus used the sound for like purposes as early as 1637. Beginning with the indorsement of Simpson and up to the present time the sound has been used too freely and not without danger. Since the bimanual method of examination has been largely practised the use of the sound has been materially restricted. It is seldom necessary to pass the sound in the consultation room. The bimanual examination will usually suffice.

In the construction of a uterine sound there are certain requirements. The instrument should be made of a flexible metal, preferably of copper, and nickel plated ; the distal end should be rounded and knob-like; the hands should be flat and grooved on one side only. Beginning two and one-half inches from the distal end the sound should be graduated every half inch for the purpose of measuring the depth of the uterine cavity.

Preliminary Procedures. Before the sound is passed certain precautionary measures are necessary. First, there must be surgical cleanliness in the preparation of the field of operation, the instruments, and the hands of the operator. Second, a bimanual examination should be made to determine, if possible, the position of the uterus. By adhering to these preliminary precautions the dangers of infection and perforation are minimized. The most convenient position is the lithotomy, though it is possible to introduce the sound with the patient in the lateral or knee-chest position.

Indications for the Use of the Sound in Diagnosis. 1. **The depth of the uterine cavity** is accurately measured by the sound. Its average normal depth is two and a half inches in a nullipara of mature years, and this is increased about one-half inch in multipara.

(*a*) *The depth of the uterine cavity is lessened* in acquired and congenital atrophy, atresia of the uterus, inversion of the fundus, and in new formations encroaching upon the cavity of the uterus.

(*b*) *The depth of the uterine cavity is increased* in subinvolution, elongation of the cervix, endometritis, metritis, and new-growths of the uterus.

2. **The direction of the uterine canal** is often changed from the normal by new-growths in and about the uterus, by senile involution, by inflammatory contraction, and by displacements of the uterus from whatever cause. As stated under preliminary precautions, it is always wise to precede the passage of the sound by a preliminary bimanual examination. If the relation of the body to the cervix is determined, the sound is curved at the proper angle before it is introduced. By so doing there is less danger of puncturing the uterus.

3. **Stenosis and atresia of the uterine canal** are definitely determined by the sound. Apparent stenosis at the point of flexion is often made to disappear by traction upon the cervix with a vulsella forceps.

4. **Irregularities of the mucosa**, if not too small and soft, may be detected by the sound. Such irregularities are submucous fibroids, polyps, malignant growths, and retained placental tissue. When possible to use the finger it is always preferred to the sound.

FIG. 29.

Simpson's graduated sound.

5. **The Thickness of the Uterine Wall.** By passing the sound into the uterus and with one hand over the abdomen, the fingers of the other hand in the rectum, it is possible under favorable con-

ditions to make a fair estimate of the thickness of the uterine wall.

Contraindications to the Use of the Sound. 1. **Menstruation.** Though not an absolute contraindication, it is better to delay the procedure until the intermenstrual period.

2. **Pregnancy** is an absolute contraindication for the passage of the sound. While the sound has been passed into a gravid uterus without interrupting pregnancy, it is never justifiable to pass the sound where there is a possibility of pregnancy.

3. **Malignant growths,** while not an absolute contraindication, are to be regarded as a source of danger and demand very cautious use of the sound for fear of exciting hemorrhage.

4. **Acute pelvic inflammation** is a contraindication for the use of the sound as well as all manipulation of the pelvic viscera.

DANGERS INVOLVED IN THE USE OF THE SOUND.

1. **Infection of the uterus** may be caused either by an unclean instrument or by carrying the infection from the lower genital tract. Forcible and careless manipulations injure the delicate mucosa, pro-

Fig. 30.



First step: passing sound; patient in dorsal position without speculum; point of sound is guided along palmar surface of left index finger to os externum. (Dudley).

ducing an atrium for infection. Because of the danger of infection the custom of passing the sound in the routine office practice is condemned.

2. **Perforation of the uterus** is an accident that may happen to the most cautious operator. The uterine wall may be so soft as to offer no perceptible resistance to the passage of the sound into the peritoneal cavity. Such softening may be due to infection and to malignant infiltration.

FIG. 31.

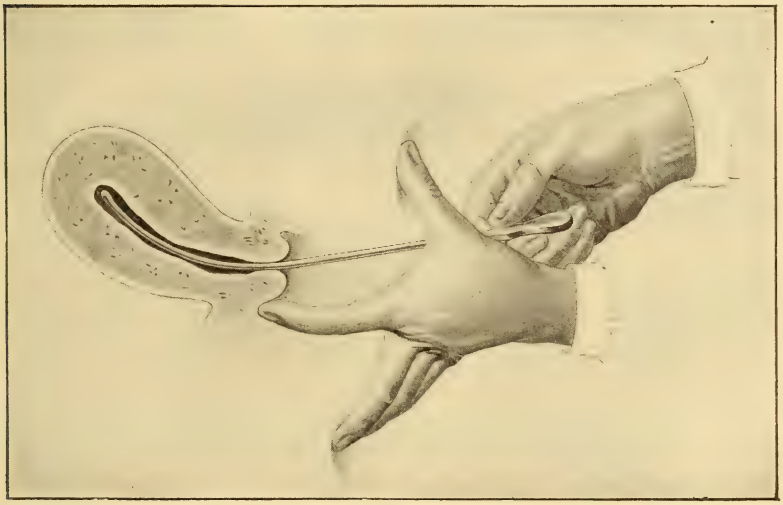

Second step: passing sound; patient in dorsal position without speculum. As sound passes from os externum to fundus, index finger is moved from os externum to posterior vaginal fornix. (DUDLEY).

3. **Hemorrhage** may be alarming in the case of malignant growths of the uterus, in hydatid mole, and in incomplete abortion.

4. **Pelvic inflammation** may be occasioned by the passage of a sound into the uterus. This is seldom the case in the absence of a pre-existing infection.

It is dangerous practice to test the mobility of the uterus by means of the sound. The bimanual examination with or without anæsthesia should afford all needed information with far less risk.

CHAPTER XII.

THE UTERINE CURETTE.

THE fact that the uterine curette is universally used speaks for its utility; but, as with many of the great and useful things of life, it is equally capable of harm in the hands of the incompetent.

The use and abuse of the uterine curette is a subject that should engage the careful consideration of the general practitioner far more than many of the more pretentious problems in the treatment of diseases of women, because the curette is the most used and the most abused of the armamentarium of the gynecologist, and, I might add, of the general practitioner.

Let us briefly consider the *indications* for the use of the uterine curette in the diagnosis of the diseases of women.

FIG. 32.

Blake's curette.

FIG. 33.

Boldt's double curette.

The uterine curette in diagnosis may be used in any of the lesions within the uterine cavity and involving the endometrium.

1. First in order of clinical importance and frequency is **endometritis.** An excessive menstrual flow and a so-called leucorrhœal discharge from the uterus, together with a history of infection, generally suffice for a clinical diagnosis of endometritis; but a positive diagnosis—one that amounts to a scientific certainty—can only be made by a microscopic examination of scrapings removed by the curette. All of the clinical signs of endometritis may be present without inflammatory changes in the endometrium, and, on the other hand, endometritis may be present to a marked degree in the absence of any clinical evidence. It is never justifiable to

curette the uterus for the purpose of differentiating between the various anatomical forms of endometritis, but rather to determine the fact of endometritis and to exlude other possible lesions, such as retained placental tissue and carcinoma. It is a matter of little concern whether we have to deal with a hypertrophic or hyperplastic, a fungus, or a polypoid endometritis. It is the fact of the presence of endometritis and not of the particular anatomical variety that is of practical clinical importance.

2. **Retained products of conception** may remain attached to the uterus for years, giving rise to hemorrhage and leucorrhœa, the cause of which can only be demonstrated by exploring the uterine cavity. In all such cases the finger, if possible, should be used in locating and removing the retained fœtal tissue. Shortly after abortion and labor curetting is rarely justifiable because of the dangers involved.

3. The firm, rounded bulging of a **submucous fibroid** is sometimes demonstrated by means of the curette.

4. **Malignant growths** of the endometrium can only be diagnosed in the early stage by microscopic examination of scrapings. There may be no symptoms, or merely those common to endometritis, and this is even possible in cases far advanced. In my personal experience the systematic examination of uterine scrapings has frequently brought to light an unsuspected malignant growth, and that which has passed clinically for malignancy has been demonstrated to be endometritis or retained placental tissue.

Syncytioma malignum—*i. e.*, a malignant degeneration of placental tissue—is a rare finding, but because of its rapid spread and fatal issue an early diagnosis is imperative. When an unaccountable hemorrhage from the uterus occurs weeks or months after labor or abortion, and particularly after the expulsion of a hydatid mole, an exploratory curettage is demanded, and a microscopic examination should be made in view of the possibility of finding malignant changes in the placental remains.

There is no more important and certainly no more satisfactory procedure in all the range of diagnosis than the differential diagnosis of uterine scrapings. A sharp line cannot always be drawn between the benign and the malignant, but in the hands of a competent observer such failures are unusual.

In the diagnosis of *ectopic pregnancy* it is sometimes advisable to curette the uterus to determine the presence of decidual tissue.

Great caution must be exercised for fear of rupturing the gestation sac.

Contraindications to the use of the curette are first of all **menstruation.** This is not an absolute contraindication, but it is seldom that the procedure cannot wait until the menstrual period is passed.

2. **Pregnancy.** The possibility of pregnancy must be positively excluded. Where doubt exists after a thorough examination it is always well to await developments for a month or more. A good rule to follow is never to use the curette in cases of delayed menstruation where pregnancy is at all possible.

3. **Acute and subacute pelvic inflammations** are contraindications, because of the danger of extending the infection. It is always wise to wait until the pelvic inflammation has subsided before curetting.

Distended tubes and ovaries are liable to rupture. No harm will likely result if the contained matter is serum, but if pus escapes the consequences may be disastrous.

The dangers involved in curettage are by no means trivial. The curette is a formidable instrument, and curettage is not to be regarded as a minor operation and without danger.

1. As with all operations, there is the risk of **septic infection** through the wounded surface. The liability to infection is not great when the uterus is firmly contracted; but in the puerperal uterus, with large venous sinuses and possible infection already existing therein, all the conditions are present favoring a wound infection.

2. **Hemorrhage** is an unlooked-for complication, yet in puerperal and malignant cases the loss of blood may be alarming and fatal.

3. The danger of exciting an **acute exacerbation** of a pre-existing pelvic inflammation is always imminent.

4. **Perforation of the uterus** by the curette is an accident that may happen to the most skilled and cautious surgeon. I venture the assertion that not an operator of large experience has escaped this misfortune. We are not to be assured by the statements frequently made that the perforation is of little consequence. In a puerperal infected uterus the uterine wall may offer no more resistance to the curette than would blotting-paper; the instrument passes through the wall apparently meeting no resistance. In such cases our only safeguard lies in discarding the curette, both the dull and the sharp.

The fingers, placental forceps, and douche are all sufficient, save in very exceptional cases. Not only is the finger less likely to perforate the uterus, but by the finger the placental site is located and the adherent placenta removed, leaving the remaining uterine surface intact, as it should be. Nature has thrown out a barrier in the decidua in the form of leucocytes or phagocytes, the so-called "protective zone," that will resist the invasion of micro-organisms if it is possible for anything to do so. The curette would but tear away this protective wall and allow a direct invasion of the venous sinuses by the septic organisms.

5. **The removal of the decidua** down to the musculature is a possible danger when the curette is used. With the finger this accident will not occur. From the decidua the new endometrium is regenerated, and if completely scraped away there will be left in its place a permanent scar surface, rendering the woman sterile and a sufferer.

The same result, though to a lesser degree, may follow too vigorous scraping of the non-puerperal uterus. The grating of the instrument is a sign that the mucosa is removed down to the deeper and firmer layer, and it is time to stop lest the entire mucosa be removed.

The following is an outline of the *technic of curettage:*

1. Anæsthesia, preferably chloroform.
2. Sterilization of the vulva and vagina.
3. Dilatation of the cervix with Hegar's bougies or an instrument of divulsion.
4. Introducing a curette to one of the uterine horns and deliberately sweeping downward as far as the internal os. Passing by successive sweeps along the posterior wall to the opposite horn, then to the side and in front to the original point of attack, making sure that no furrows or patches are left by again going over the surface in a similar manner.
5. Irrigating the uterus with salt solution. As a routine practice I would recommend swabbing the uterus with full strength formalin.
6. No uterine pack is recommended unless the uterus is relaxed and bleeding freely. A sterilized vaginal tampon may be inserted against the cervix for twenty-four hours, then removed, and 1 per cent. lysol douches or formalin, 1 : 1000, may be given daily for a week.

7. Rest in bed should be enjoined for a period of four or more days.

8. No escharotics should be used. The sharp curette should be used in all cases, with the exception of a puerperal uterus, when a dull curette is employed after more conservative methods have failed. (See Plates XI., XII., and XIII.)

PLATE XI.

Fig. 1.

Curettage. First step: dorsal position. Cervix exposed by perineal retractor in right hand of assistant. Uterus drawn down by vulsella forceps held by left hand of assistant. Dilatation by graduated bougies held in right hand of operator.

Fig. 2.



Curettage. First step: dorsal position. Cervix exposed by perineal retractor in right hand of nurse. Uterus drawn down by vulsella forceps in left hand of assistant. Dilatation begun by small dilator in right hand of operator. (DUDLEY.)

PLATE XII.

Fig. 1.

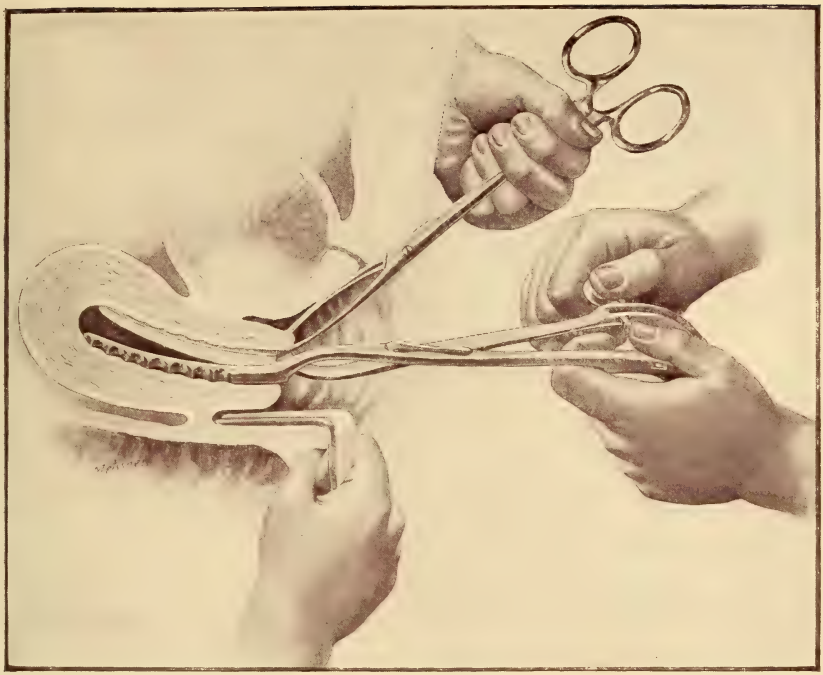

Curettage. Second step: dorsal position. Cervix exposed by perineal retractor in right hand of nurse. Uterus drawn down by vulsella forceps in left hand of assistant. Dilatation completed by Wathen dilator in hands of operator. (DUDLEY.)

Fig. 2.

Curettage. Third step: dorsal position. Perineum retracted by two fingers of operator's left hand. Uterus drawn down by vulsella forceps in left hand of assistant. Endometrium curetted by sharp curette in operator's right hand. (DUDLEY.)

PLATE XIII.

Fig. 1.

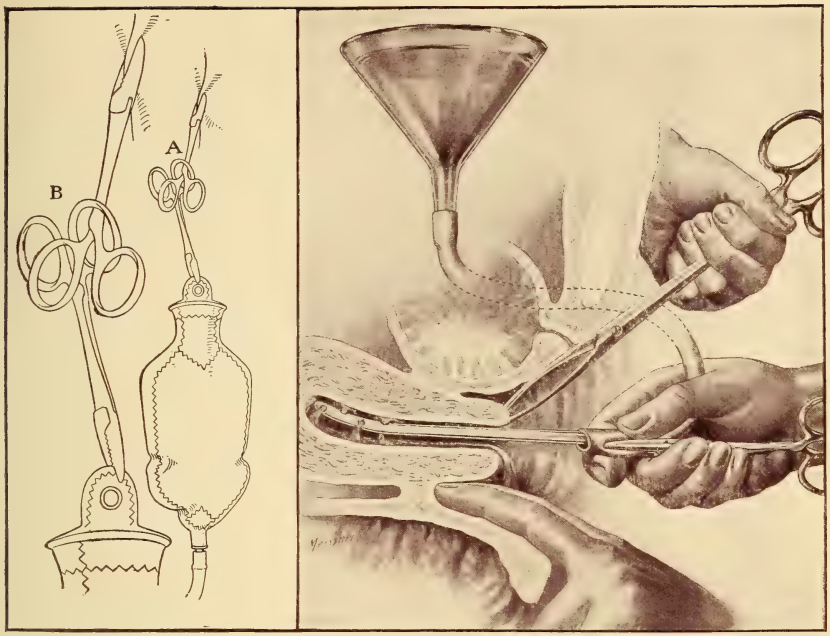

Curettage. Fourth step: dorsal position. Perineum retracted by two fingers of operator's left hand. Uterus drawn down by vulsella forceps in left hand of assistant. Endometrium irrigated by canula inserted into rubber tube in operator's right hand. Figs. *A* and *B* show a fountain syringe attached to a towel by means of pressure forceps. The towel may be fastened to a curtain or other hanging by means of safety-pins. The fountain syringe may be used instead of the funnel. (DUDLEY.)

Fig. 2.

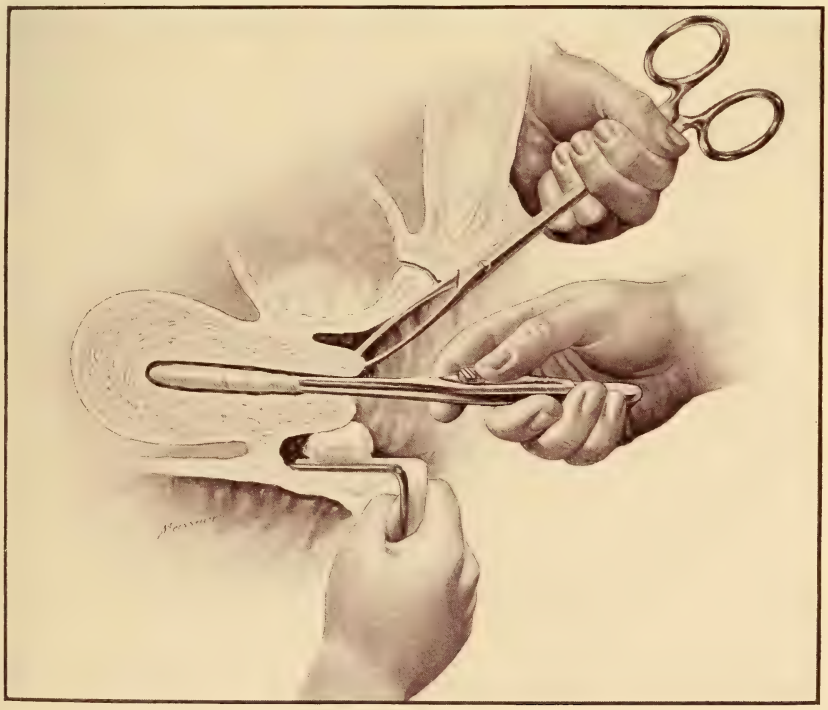

Curettage. Final step: dorsal position. Perineum retracted by Simon retractor in right hand of nurse. Uterus drawn down by vulsella forceps in left hand of assistant. Endometrium disinfected by cotton wound on Emmet's dressing forceps and saturated with desired disinfectant. Application made by right hand of operator. (DUDLEY.)

CHAPTER XIII.

MICROSCOPIC EXAMINATION OF SCRAPINGS AND EXCISED PIECES.

THE microscope is indispensable in the diagnosis of diseases of women. The microscopic examination of scrapings and excised pieces constitutes one of the most important and gratifying means of determining the character of lesions involving the cervix and endometrium.

The bimanual examination will alone determine many of the affections of the pelvic viscera; inspection of the vagina and vaginal portion of the cervix through a speculum will afford much information; direct palpation of the cervical canal and cavity of the uterus will add much to our knowledge of the extent and character of the lesions involving these surfaces; the clinical symptoms are important in the consideration; but a positive diagnosis, one that admits of no reasonable doubt, is often reserved until a microscopic examination of scrapings and excised pieces has been made.

Very often the microscope serves to verify a clinical diagnosis, but in not a few cases a previously unsuspected condition is brought to light by a microscopic examination of scrapings from the endometrium and excised pieces from the vaginal portion of the cervix.

The author does not claim that the microscope is an infallible means of making a diagnosis. In exceptional cases the diagnosis remains in question after all means—the microscope included—have been exhausted.

REMOVAL OF UTERINE TISSUE FOR DIAGNOSTIC PURPOSES.

In all cases, unless contraindicated, a general anæsthetic is advisable. Cocaine may be used as a local anæsthetic in excising pieces from the cervix. When the tissue is soft and friable, as in carcinoma, no local or general anæsthetic may be required.

It is not necessary to shave the vulva, but by scrubbing and douching the field of operation is made clean.

The position assumed by the patient may be the Sims or lithotomy. If the former, the Sims or Simons speculum is used; if the latter, the Simons or self-retaining speculum is preferred. The self-retaining speculum is especially advantageous because no assistant is needed.

Test Excision from the Cervix. After grasping the anterior lip of the cervix by vulsella forceps, a small wedge is cut from the cervix by angular scissors. In selecting a portion for excision an effort should be made to include in the removed piece a part of healthy together with diseased tissue for the purpose of studying the transition stages.

Hemorrhage is to be controlled by a gauze pack, or, when necessary, by the placing of absorbable sutures.

Test Curettage of the Uterus. The cervix is dilated sufficiently to admit a moderate-sized curette. The instrument is passed under control of the eye by the aid of a Sims or Simons speculum. The patient is in the Sims or lithotomy position. In order that no portion of the endometrium escape the curette, the uterus should be scraped systematically and thoroughly, beginning at one horn and sweeping deliberately down to the internal os, passing in this manner over the entire inner surface of the uterus, taking care that no portion of the endometrium be missed. Before the blood has time to firmly coagulate the scrapings should be removed to a 4 per cent. solution of formalin. Allowing them to lie long in water causes maceration. All particles in the scrapings are to be carefully preserved, so that if necessary the entire specimen may be examined.

Frozen Specimens of Excised Pieces and Scrapings. Where an immediate diagnosis is required the freezing method may be employed with fairly satisfactory results. It occasionally happens that the examination of excised pieces and scrapings will determine the question of a more radical procedure. If by reason of expediency or added risk from a second anæsthetic it becomes necessary to proceed without delay, frozen sections may be prepared and diagnosed while the patient is being prepared for a radical operation. Not more than twenty minutes are required for the examination.

The following is the method employed in Johns Hopkins Hospital by Cullen:

(*a*) Place the frozen section in 5 per cent. aqueous solution of formalin for from three to five minutes.

(*b*) Leave in 50 per cent. alcohol one minute.
(*c*) In absolute alcohol one minute.
(*d*) Wash out in water.
(*e*) Stain in hæmatoxylin two minutes.
(*f*) Decolorize in acid alcohol.
(*g*) Rinse in water.

FIG. 34.



Bardeen CO_2 freezing microtome.

This microtome is an improved pattern after designs by Professor C. R. Bardeen, of Johns Hopkins University, and is a most excellent instrument for regular pathological and other demonstrations. It is indispensable for clinical work where stained sections of morbid tissues are required within a few minutes of the beginning of an operation in order that the surgeon may determine his mode of procedure.

It freezes almost instantaneously regardless of room temperature or humidity and at very small expense. The temperature of the object to be frozen is, within limits, under the control of the operator.

The freezing chamber contains a spiral passage through which the expanding CO_2 passes, securing the maximum freezing power.

The knife slides on glass guides. The finest feed is twenty microns. The microtome may be attached directly to a CO_2 cylinder.

(*h*) Stain with eosin.

(*i*) Transfer to 95 per cent. alcohol.

(*j*) Pass through absolute alcohol, then through either creosote or oil of cloves, and mount in Canada balsam.

While the freezing method has an important place in connection with the operating room, the sections are not overly satisfactory, for the reason that only small sections can be made and differentiating stains cannot be used. Where an immediate diagnosis is not required (and this is true in the majority of instances) the celloidin or paraffin methods are preferred.

Fig. 35.

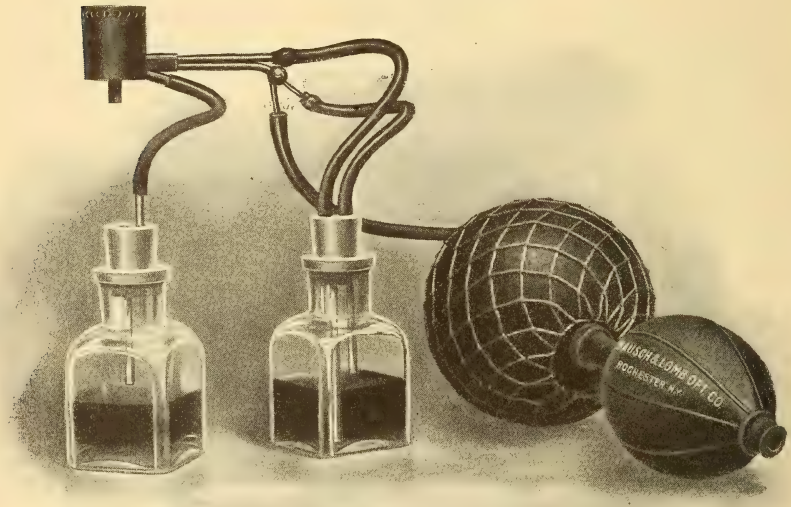

Ether or rhigolene freezing attachment.

This attachment consists of a cyndrical freezing stage upon which the object to be frozen is placed and against which a very fine spray of ether or rhigolene as desired is projected by a delicate atomizer operated by the bulb air-pump shown in the illustration. The rapid evaporation of the fluid abstracts sufficient heat from the object to freeze it in a short time. There is always, however, an excess of fluid which does not evaporate, and this is drained back into a bottle and used again. This freezer is applicable to the automatic laboratory, medium laboratory, student, table, and demonstration microtomes.

FIXING THE SPECIMENS.

Zenker's fluid (Müller's fluid, 100 per cent.; bichloride, 5 per cent., and, shortly before using, the addition of 5 per cent. of glacial acetic acid) is an excellent fixing fluid, preserving the blood in its natural color. After fixing in Zenker's for twenty-four hours the section is placed in cold running water for twenty-four hours or in a weak iodine solution for a like time. The section is then ready for hardening in alcohol. No better fixing fluid can be used where time will permit. It is often well to place the entire uterus in Zenker's fluid for a week or more before cutting sections from it.

Alcohol as a fixing agent is objectionable because of the shrinking of the tissues. Where it is desired to examine for micro-organisms alcohol is of special value.

Formalin may be used in a 2 to 4 per cent. solution. It is objected to because of the difficulty in cutting the musculature.

HARDENING AND EMBEDDING.

When it is desired to prepare the section hurriedly, a small piece is placed immediately in absolute alcohol and changed three or four times in twenty-four to thirty-six hours, when it is ready for embedding.

When an additional day or two can be taken better sections are made by running the pieces through successive strengths of alcohol and changing every two to twelve hours through 70, 80, and 90 per cent. and absolute alcohol.

It is now necessary to embed the section in a substance which will permeate the tissue, filling up all spaces and giving support to the section while being cut and mounted.

The embedding of a specimen in celloidin follows upon the hardening process. For general purposes the celloidin method is preferred. From absolute alcohol the section is placed in equal parts of sulphuric ether and absolute alcohol from six to twenty-four hours, depending upon the size of the section. Next the section is changed to a dilute solution of celloidin in ether for from six to twenty-four hours; it is placed in a thick solution of celloidin in ether for an equal time, when it is ready to mount upon a cork for sectioning.

After blocking the specimen on wood or cork it is allowed to fix firmly in the open air or under a bell-jar, and is then placed in 70 per cent. alcohol for an hour or more. The section is now ready for cutting and mounting.

The embedding of specimens in paraffin is an excellent method for general laboratory purposes, but is somewhat complicated for private laboratory use. When the tissues are soft and small, as in scrapings, ideal sections are prepared by this method. For serial sections no other method can be employed. After thoroughly dehydrating the tissue the specimen is immersed in a solution of zylol and paraffin, or in chloroform and paraffin, from two to twenty-four hours, and is kept at a uniform temperature of 37° C. Next the specimen is immersed in melted paraffin for a like time and

FIG. 36.



Student microtome.

The student microtome is intended for individual and laboratory use where a reliable mechanical microtome at small cost is required. It is extremely simple, yet very accurate in construction. This is one of the few models which have remained practically unchanged, showing that it is adapted for its work.

The stand is one solid piece of metal. The knife block is as heavy as is consistent with the size of the instrument. The feed arrangement is carried in a metal stirrup attached permanently to the front of the stand and consists of an accurately cut micrometer screw having pitch of 0.5 mm., with graduated head divided to 100 parts, each graduation, therefore, having a value of 5 microns. The object clamp is adjustable in two planes and can be set for paraffin or celloidin cutting.

kept at a temperature of 48° to 50° C. It is then removed to a cool place and is quickly solidified in the paraffin, after which it is blocked out with a knife and mounted on a cork for cutting.

METHOD OF STAINING AND MOUNTING SECTIONS.

Celloidin Sections. For all practical purposes the hæmatoxylin-eosin stain is most satisfactory. After cutting the sections and immersing them in water for a few moments, the following method is adopted:

Fig. 37.

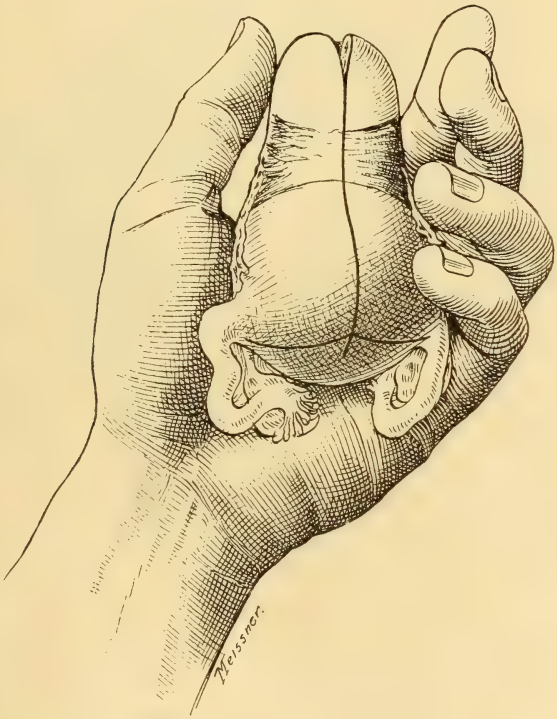

Lines of incision in opening the uterus after hysterectomy.

1. Stain in hæmatoxylin one to two minutes.
2. Decolorize in acid alcohol.
3. Immerse in weak ammonium water until the blue color returns.
4. Immerse in water to remove the ammonium.
5. Counterstain in eosin from ten to thirty seconds.

6. Immerse in 75 per cent. alcohol two minutes.
7. Absolute alcohol one minute.
8. Clear in creosote or oil of cloves.
9. Mount in Canada balsam.

Paraffin Sections. After cutting the sections they are carefully transferred to a shallow basin of warm water, on which they spread in thin ribbons. The water must not be hot enough to melt the paraffin, but merely sufficiently so to unfold the sections and spread

Fig. 38.

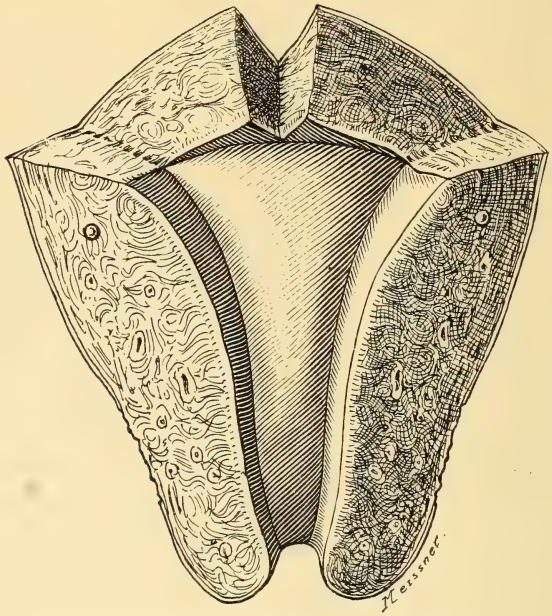

The uterine cavity exposed.

them out smoothly. A glass slide is held underneath the sections, and they are made to float upon the slide. The slide is then withdrawn from the water, the water drained off, and is then placed for several hours on the top of an oven or radiator, where the moisture is thoroughly driven from the slide and the section firmly fixed. The paraffin is dissolved in zylol or chloroform (by which the section is "cleared"), and from this point on the staining is carried out in the usual manner.

INSPECTION OF THE UTERUS AFTER REMOVAL.

In order that a satisfactory examination may be made of the uterus after its removal, the operator should handle and mutilate the specimen as little as possible. Introduction of swabs, probes, and curettes injure the endometrium and lead to false observations. Fig. 37 shows the method of opening the uterus. The body of the uterus is grasped by the left hand. Two incisions are made, as shown in Fig. 38, and the uterus is spread open in such a manner that the entire mucosa will be exposed. Before small sections are removed it is always well to fix the uterus in Zenker's fluid for several days. The structures are thereby least disturbed in their relations.

The color, consistency, outline, and measurements are all to be noted and recorded. Foreign growths and abnormalities are described in detail.

CHAPTER XIV.

EXPLORATORY PUNCTURES AND INCISIONS

An exploratory puncture is not seldom resorted to for the purpose of completing the diagnosis. When conjoined examination fails to determine the nature of a pelvic tumor aspiration is an essential aid to the diagnosis. Collections of blood, pus, and serum in the tubes, ovaries, and pelvic tissues often cannot be diagnosed with certainty until the contents are procured either by aspiration or by incision. Furthermore, the character of the obtained fluid may not be recognized until submitted to a chemical, microscopic, and bacteriological examination. It is a growing conviction that an exploratory incision affords better results and is less dangerous than is aspiration. This is particularly true of abdominal explorations.

Fig 39.

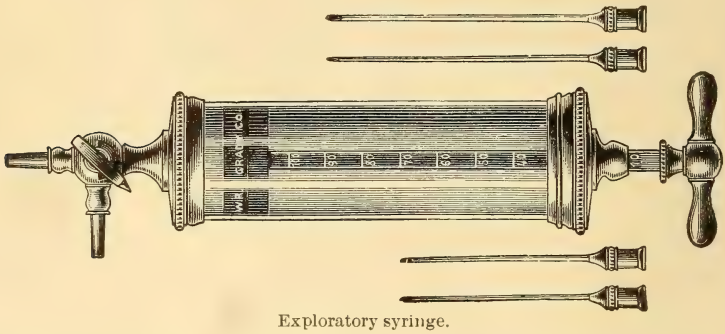

Exploratory syringe.

The instrument and field of operation must be rendered perfectly sterile. When surgical principles are carried out no harm should follow either procedure. Exploratory incisions are of value not only in determining the character of the contained fluids in the pelvis, but the procedure has a wide range of usefulness. Indeed, it may be truly said that every abdominal incision is in a sense exploratory. The abdominal surgeon very often encounters unsuspected growths and adhesions, and, for this reason, one who is not master of any condition that may unexpectedly arise should not undertake to open the abdominal cavity.

PLATE XIV.

BREAST OF DARK BRUNETTE, NEAR TERM.

From Life. (Jewett.)

PLATE XV.

BREAST OF BLONDE IN LATER MONTHS OF PREGNANCY.
From Life. (Jewett.)

Value of the Sign. *In a woman of the childbearing period, who has previously been regular, cessation of menstruation is a highly probable sign.*

2. Morning Sickness. Occurs commonly between the fourth and eighth weeks; earlier and more frequent in primipara.

Fig. 41.

Breast of woman who has been pregnant, showing pigmented areola and position of gland. Dennis.)

Fallacies:

1. Diseases of the brain, kidney, and digestive tract.
2. Uterine displacements.
3. New-growths of the uterus and ovaries.

Value of the Sign. *Highly presumptive when associated with amenorrhœa.*

3. Salivation. Rarely present after the fourth week, and is of no special value.

4. Nervous Phenomena.
   1. Ringing in the ears—rarely present.
   2. Neuralgia—rarely present.
   3. Changes in disposition.

Value of the Sign. *Negative.*

5. Irritable bladder, due to the size and weight of the uterus.

Value of the Sign. *Negative.*

II. Objective Signs.

1. Changes in the Mammary Glands. At the end of the fourth week the breasts tingle and enlarge ; at about the twelfth week there is pigmentation and enlargement of the areola, prominence of the glands of Montgomery, the nipples enlarge, become erectile and sensitive, veins stand out prominently under the skin, a secondary areola forms, linea albicantes are sometimes seen near the areola, and colostrum is secreted.

Fallacies :
   1. Breasts may enlarge from pelvic tumors.
   2. Breasts may enlarge during menstruation.
   3. Prostitutes and multiparæ may have a secretion of colostrum.
   4. Multiparæ retain some of above signs, and little or no change may occur during pregnancy.

Value of the Sign. *Highly presumptive, and especially in young primiparæ.*

2. Discoloration of the vulva and vagina may occur as early as the sixth week or as late as the eighth month. The structures soften and become blue in color from venous congestion. Discoloration varies in degree and in time of appearance.

Fallacies :
   1. Frequently observed in fleshy women.
   2. Caused by all new formations and inflammatory swellings in the pelvis.
   3. May be due to portal congestion from diseases of the heart, lungs, liver, kidney, etc.

Value of the Sign. *Presumptive.*

3. Softening of the vaginal portion of the cervix generally begins at the fourth week, earlier in multiparæ. It is due to passive congestion. The softening begins at the external os and extends upward.

Fallacies: Same as for discoloration of the vulva and vagina.
Value of the Sign. *Highly presumptive.*

FIG. 42.

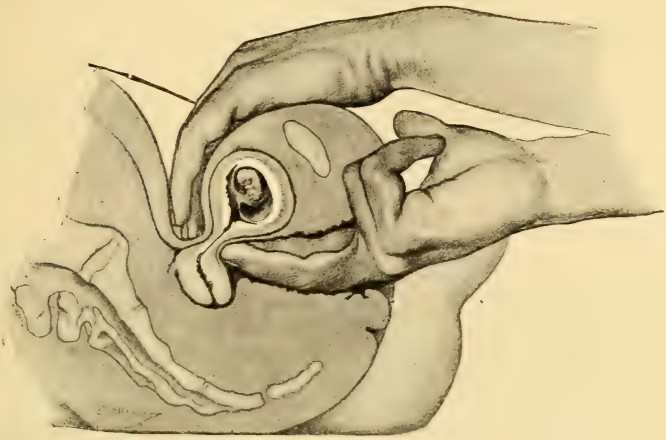

Bimanual examination for compressibility of the isthmus at the sixth week. (JEWETT.)

FIG. 43.

Retroversion of a pregnant uterus, with fixation by adhesions binding the fundus to the rectum and sacrum.

4. Softening and Compressibility of the Lower Uterine Segment (Hegar's sign). Elicited by introducing one or two fingers into the posterior vaginal fornix and approximating the fingers of the hand over the abdomen as closely to the fingers in the vagina as possible. The lower uterine segment may be compressed to the thinness of paper.

Hegar's sign may be elicited as early as the sixth week. The sign may be impossible of demonstration, because of the thickness

Fig. 44.

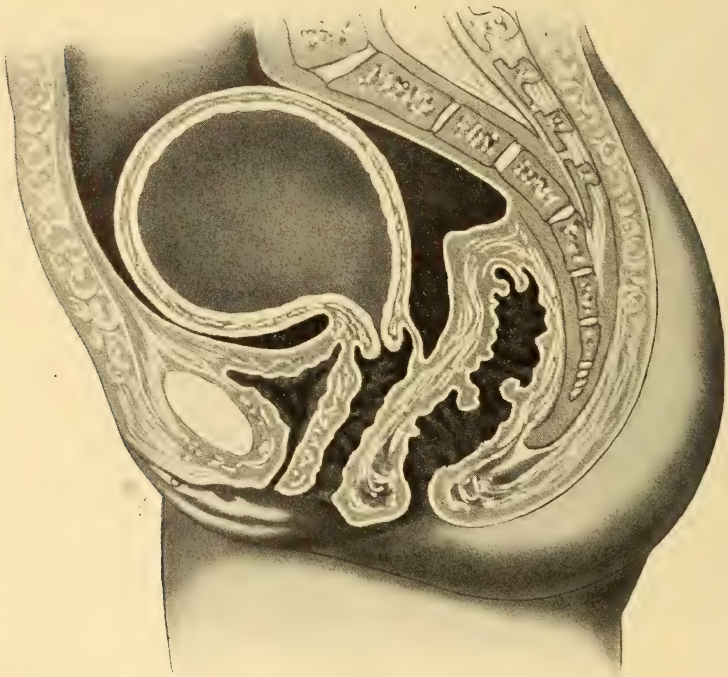

Anteversio-flexion of the pregnant uterus at the end of the third month of pregnancy.

and rigidity of the abdominal wall. Rectal palpation will be of service in these cases.

Value of the Sign. *Very reliable, though not a positive sign of pregnancy.*

5. Leucorrhœa often begins early and persists throughout pregnancy.

Value of the Sign. *Negative.*

6. Changes in Position, Size, Form, and Consistency of the Uterus.

a. Position: extreme anteversion.

b. Size of child's head at end of third month.

c. Form: increase in the antero-posterior diameter, becoming spherical at the end of the third month.

d. Consistency: soft and elastic.

Value of the Sign. *Highly presumptive.*

There are no positive signs of pregnancy in the first trimester except seeing the fœtal structures and decidua, but when two or more of the above-named presumptive or highly probable signs are present the diagnosis of pregnancy amounts to a moral certainty.

Second Trimester.

I. Subjective Signs.

1. Cessation of Menstruation continues.
2. Morning sickness rarely persists after the fourth to the fifth month.
3. Salivation rarely continues.
4. Nervous phenomena may increase.
5. Bladder may be less irritable.
6. Active Fœtal Movements. Time of occurrence, sixteenth to eighteenth week—earlier in multipara. Likened to the fluttering of a bird in the hand, and increases in force with time.

Fallacies:

1. Peristaltic movements of the bowel.
2. Spasmodic contractions of the abdominal muscles.
3. Movements of abdominal tumors.

Value of the Sign. *Presumptive.* Of value in determining the date of confinement. Count forward twenty-three weeks in primipara, twenty-four weeks in multipara.

II. Objective Signs.

1. Active Fœtal Movements. *A certain sign of pregnancy when felt and heard by the physician.*
2. Passive Fœtal Movements (ballottement). Is first elicited about the sixteenth week. Ballottement may be:

(*a*) Internal. Hands are placed as in an abdomino-vaginal examination. With the hand on the abdomen a sharp tap is given; the fœtal body is felt to bound and rebound.

(*b*) External. The hand is placed flat upon one side of the abdomen, the opposite side is sharply tapped with the fingers of the other hand.

Fallacies:

1. Pedunculated tumors floating in ascitic fluid.
2. Stone in the bladder.
3. Floating kidney and spleen.

FIG. 45.

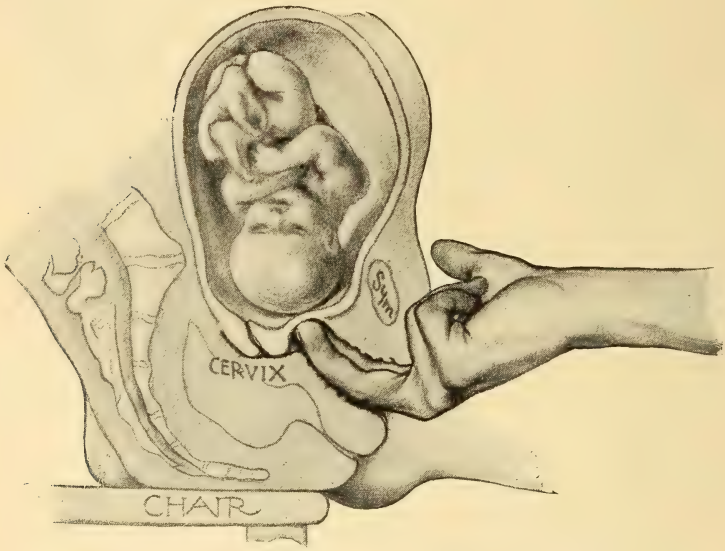

Internal ballottement, semirecumbent posture, at sixth month. (JEWETT.)

Value of the Sign. *Positive in competent hands.*

3. DIRECT PALPATION OF THE FŒTUS.

Value of the Sign. *Positive.*

4. INTERMITTENT UTERINE CONTRACTIONS. The time of appearance is between the tenth and sixteenth week. The uterus becomes firmer and assumes a pear shape, then slowly relaxes. The intervals between contractions are five to twenty minutes.

Fallacies:

1. Contractions of the recti muscles.

2. Contractions of soft fibroids.
3. Intermittent uterine contractions in hæmatometra, pyometra, and hydrometra.

Value of the Sign. *Positive.*

5. AUSCULTATION.

1. *Fœtal Heart Tones.* Heard in the fourteenth to the eighteenth weeks. The conditions governing the intensity of the heart tones are:
   a. Position of the fœtus. Heart tones increased when the child's back presents.
   b. Position of the placenta. Heart tones decreased when auscultating through the placenta.
   c. Size of child. Heart tones strong in proportion to the development of the child.
   d. Thickness of the abdominal walls obscures the fœtal heart tones.

The heart tones resemble the tick-tack of a watch under a pillow. The frequency is 100 to 150 a minute. Temperature and exercise increase and uterine contractions slow the heart beat.

Value of the Sign. *Most reliable of all signs, not only showing the fact of pregnancy, but also the life of the fœtus.*

2. *Fœtal Souffle.* A soft, blowing sound synchronous with the fœtal heart beat occurs in 14 to 16 per cent. of all cases. The sound is caused by the circulation in the cord, and is said to be due to an abnormally short cord or one that is twisted, knotted, or wound about the neck of the child.

Value of the Sound. *Positive when heard.*

3. *Placental Souffle.* A soft, blowing sound, synchronous with the maternal heart beat. The intensity is decreased during uterine contractions. The sound is not constant in rhythm or intensity, and is best heard on the left side of the uterus. The time when first heard is between the fourteenth and eighteenth week.

Fallacies:

a. Heard in vascular tumors of the pelvis.
b. Gas in the mother's bowels.
c. Murmurs in the arteries of the pelvis.

Value of the Sign. *Probable sign of pregnancy.*

6. RATE OF GROWTH OF THE UTERUS.

Value of the Sign. *Positive in experienced hands. No other tumor grows so steadily and rapidly.*

7. Changes in Position, Size, Form, and Consistency of the Uterus.

(*a*) *Position*—median.

(*b*) *Size.* End of the third month, at the level of symphysis pubis.

End of the fourth month, three finger-breadths above symphysis pubis.

End of the fifth month, two-thirds the distance from the pubes to the umbilicus.

End of sixth month, at the level of the umbilicus. (See Fig. 46.)

(*c*) *Form*—globular.

(*d*) *Consistency*—soft and elastic.

Value of the Sign. *Positive in experienced hands.*

Third Trimester.

I. Subjective Signs.

1. Cessation of Menstruation continues.
2. Morning sickness rarely persists.
3. Salivation rarely persists.
4. Nervous phenomena may be increased.
5. Active fœtal movements increase, and may seriously annoy the mother.

II. Objective Signs.

1. Active fœtal movements increased.
2. Passive fœtal movements increased.
3. Direct palpation of the fœtus usually accomplished with ease.
4. Intermittent uterine contractions marked.
5. Auscultation of fœtal heart, fœtal and uterine souffle increasingly distinct.
6. The rate of growth of the uterus continues as in second trimester.
7. Position of the uterus at the end of the seventh month is one-third the distance from the umbilicus to the ensiform cartilage; at the end of the eighth it is two-thirds the distance, and at full term it has dropped back to the level of the eighth month.

8. Changes in the Form of the Uterus. The lower uterine segment thins and distends; the cervix becomes effaced from above downward.

9. Changes in the Contour of the Abdomen. Until the end of the ninth lunar month the abdomen shows a regular curve. When the head sinks into the pelvis the epigastrium is flattened and the abdomen protrudes more prominently.

10. Presentation of part or all of the fœtal parts is the last and most conclusive sign of pregnancy.

Fig. 46.

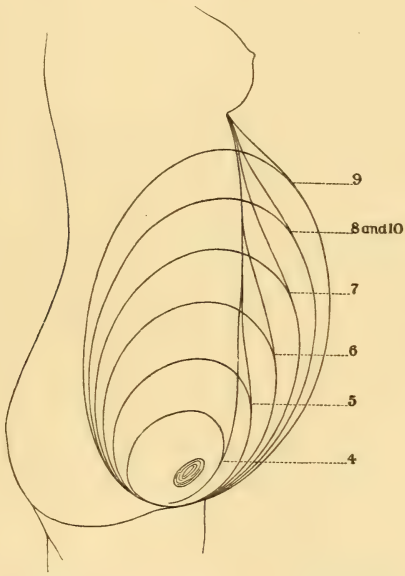

Showing the level of the fundus from the fourth to the tenth month.

DIAGNOSIS OF THE LIFE OR DEATH OF THE FŒTUS.

Fœtus is known to be living when the physician: 1. Hears the fœtal heart or fœtal souffle.

2. Feels the fœtal movements.

Fœtus is believed to be dead when: 1. Fœtal movements cease after having been felt by the physician.

2. Fœtal heart tones cease after having been heard by the physician.

3. Temperature of the vagina is lowered.
4. Fœtus loses its normal elasticity.
5. Colored liquor amnii is discharged.
6. Head of the child is softened.
7. Mother loses flesh, breasts diminish in size, and there is general malaise. It is to be remembered that a dead fœtus may lie in the uterus weeks and months after full term.

DIAGNOSIS OF THE TIME OF PREGNANCY AND PREDICTION OF THE DATE OF CONFINEMENT.

The exact time of conception is rarely known, hence it is impossible to fix the exact date of confinement. The duration of normal pregnancy varies within wide limits. Pregnancy may be accidentally terminated by a fall, diarrhœa, shock, etc. The normal limits are placed at two hundred and forty to three hundred and twenty days.

The data for determining the date of confinement are:

1. From the date of a single coition count forward two hundred and seventy-two to two hundred and seventy-five days.
2. From the first day of the last menstrual period count backward three months and add seven days.
3. From the time of "quickening" count forward twenty-three weeks in multiparæ and twenty-four weeks in primiparæ.
4. From the level of the fundus. (See Fig. 46.)
5. From the size of the fœtus—an uncertain method requiring long experience.

Diagnosis of Multiparity. It may not be possible to say with certainty that a woman has given birth to a child. The following are the anatomical evidences of previous childbearing:

1. **Rupture of the Hymen and Perineum.** The hymen may be congenitally absent; it may not rupture in labor, and is usually ruptured in coitus, masturbation, and in operations upon the lower genital tract.

2. **Laceration of the Cervix.** The cervix may not be lacerated in labor, but may be by dilating for intra-uterine explorations and operations.

Lacerations of the perineum, when direct violence can be excluded, are regarded as positive evidences of multiparity.

3. **Lacerations of the Vagina.** When direct violence and operations upon the vagina can be excluded, scars in the vaginal mucosa are regarded as evidences of multiparity. The smoothing out of the rugosities may be due to masturbation and coition, and cannot be regarded as conclusive evidence of multiparity.

4. **Mammary glands** are pigmented, flabby, and show the striæ gravidarum in a multipara, but these evidences are not always present, and, on the other hand, they may be present to a greater or less degree in women who have not borne children.

5. **Striæ gravidarum** are commonly found on the abdominal wall and thighs. They are the result of stretching of the skin from a growing tumor, and hence may result from abdominal distention from whatever cause, not only in multipara, but as well in primipara, and in the male as well as in the female. While suggestive of pregnancy, they cannot be regarded as positive evidence.

DIAGNOSIS OF MULTIPLE PREGNANCY.

1. **Unusually large uterus** may be due to hydramnios, hydatid mole, large fœtus, and uterine tumors complicating pregnancy.

2. **Groove in the fundus** separating the fœtuses. This is an unusual finding.

3. **Palpation of two heads** or of **two breeches**—a positive evidence when elicited.

4. **Fœtal heart tones** heard in two separate areas and not synchronous.

5. **Vaginal touch** demonstrating two separate and distinct presenting bodies—*i. e.*, two heads, two breeches, or a head and a breech, or two separate and distinct protruding bags of membranes.

6. **Mensuration of the fœtus,** showing an abnormally long measurement for a single fœtus.

DIAGNOSIS OF THE CAUSES OF HEMORRHAGE OCCURRING DURING PREGNANCY.

Any of the causes of hemorrhage from the non-gravid uterus (see page 28) may operate during pregnancy. We must, therefore, carefully distinguish between hemorrhage due to pregnancy alone and one resulting from some complication of gestation. In so doing we must exclude the possible existence of inflammatory

lesions, of benign and malignant new formations, of ulcers and erosions of the cervix.

It is often only with the greatest difficulty that we are able to determine the source of hemorrhage from the pregnant uterus. According to Winter, endometritis is the most frequent source. With the fœtus *in utero* it is manifestly impossible to say with absolute certainty that endometritis exists. This fact is due to the unreliable symptoms, to the absence of any reliable physical signs, and, finally, to the impossibility of demonstrating by microscopic examination of scrapings the characteristic histological changes in the decidua before the termination of pregnancy. We are, therefore, compelled to rely upon the history of endometritis previous to pregnancy and upon the exclusion of other possible causes. A negative history does not exclude the possibility of endometritis, because the various inflammatory lesions of endometritis may exist without symptoms and without apparent cause.

The long continuance of the hemorrhage, the admixture of mucus with blood, and the habit of habitual abortion are suggestive of endometritis, but a positive diagnosis is only made by a microscopic examination of the decidua after expulsion of the egg.

Placenta prævia as a cause of hemorrhage occurring during pregnancy is a most important factor from a clinical point of view. Hemorrhage from placenta prævia rarely occurs in the early months of pregnancy, and the liability increases up to the time of labor. The first loss of blood generally occurs after the eighth month.

A characteristic feature of hemorrhage from placenta prævia is said to be its occurrence in the intervals between uterine contractions. The loss of blood may be instantly fatal or may slowly exhaust the patient's strength. The diagnosis rests upon establishing the fact of pregnancy and upon the physical evidences of a misplaced placenta. Under favorable conditions the edge of the placenta may be palpated through the abdominal wall. In a conjoined examination the fœtal parts are indistinctly felt through the vagina, and ballottement may be impossible of demonstration. It is only possible to recognize placenta prævia by feeling the placenta through the dilated cervix. The characteristic stringy feel of the placenta is noted. An incomplete placenta prævia is recognized by sweeping the finger between the margin of the placenta and the sides of the cervix. In complete placenta prævia this would be impossible.

Hemorrhage from premature separation of a normally situated placenta (accidental hemorrhage) may occur late in the period of pregnancy or in labor. The hemorrhage is apparent or concealed. In concealed hemorrhage it is possible for death to occur without the blood finding its way out through the cervix.

In making a diagnosis of the cause of the hemorrhage, placenta prævia and rupture of the uterus must be excluded. The former can only be excluded by palpating or failing to palpate the placenta through the dilated cervix; the latter is excluded from the fact that it occurs late in labor, the uterus diminishes in size, and a new abdominal tumor arises.

In concealed hemorrhage there is, in addition to the usual general signs of internal hemorrhage, a sudden increase in the size of the uterus; cessation or obscurity of the fœtal movements and heart tones, and, finally, in place of the soft, elasticity of the normal pregnant uterus, there is a boggy consistency.

THE DIAGNOSIS OF ABORTION.

We may speak of abortion in progress, of incomplete abortion, and of complete abortion. In making a diagnosis of abortion we must first establish the fact of pregnancy. This is not always possible in early abortion without the presentation of part or all of the fœtal structures.

When hemorrhage from the uterus is associated with painful uterine contractions the diagnosis of pregnancy is most probably correct. An irregular hemorrhage, following upon a period of amenorrhœa in a woman sexually mature, is always suggestive of pregnancy, and when the uterus corresponds to that of pregnancy the diagnosis of incomplete or threatened abortion is made with certainty. Through the dilated cervix it may be possible to see or feel the presenting part of the ovum.

The diagnosis of an abortion is manifestly more difficult when it is not certain that pregnancy has existed. This difficulty arises in abortions of the second month when the expected menses are delayed and there follows a hemorrhage unlike the menstrual flow in appearance and in amount. That pregnancy exists is suggested by the period of amenorrhœa, the softening and discoloration of the cervix, the slight enlargement and softening of the uterus, and the discoloration of the vagina and vulva. These evidences of preg-

nancy, together with the unexpected appearance of a uterine hemorrhage, are all but conclusive proofs of an abortion. All blood expelled should be carefully searched for fœtal tissue.

After establishing the fact of pregnancy and of abortion, it then becomes imperative to determine whether the abortion is complete or incomplete. With but few exceptions the hemorrhage will continue as long as the uterus is not thoroughly emptied, and will cease the moment all the fœtal structures are expelled.

It is to be remembered that in some women there is a periodical flow of blood for one, two, or more months after conception. We may say with certainty that abortion is complete when the expelled ovum is intact, or after a digital or instrumental exploration of the uterine cavity. We may say with certainty that abortion is incomplete when only a portion of the ovum is known to have been expelled or when fœtal remains are found in the uterus by exploring with the finger or instruments.

THE ANATOMICAL DIAGNOSIS OF PREGNANCY.

The diagnosis of pregnancy may not be made with certainty from the subjective and objective signs. There may be a complete absence of all subjective symptoms, or the patient may deny their existence. Again, an early abortion may not be recognized by the patient as such, and the diagnosis must rest upon the macroscopic and microscopic examination of expelled masses and membranes or of scrapings removed by the finger or curette.

The macroscopic diagnosis of pregnancy is made from naked eye inspection of particles removed from the uterus—*i. e.*, chorionic villi, decidua, fœtal body. It is not always possible to recognize these structures with certainty by the unaided eye, and in such cases the microscope is indispensable.

The microscopic diagnosis of pregnancy is largely based upon the finding of *chorionic villi.* These are composed of a connective tissue framework in which are found fœtal bloodvessels. The connective tissue is composed of round, spindle-shaped or stellate-shaped cells, with an intercellular mucinous substance identical to that of Wharton's jelly in the umbilical cord. Fibrillar processes join the cells forming a network. The bloodvessels coursing through the stroma are endothelial-lined canals in the early weeks of pregnancy; later they acquire a muscular wall. As pregnancy

advances the embryonic connective tissue cells become matured into fibres forming a more compact stroma. The epithelial coverings of the villi in early pregnancy are composed of two distinct cellular layers. The innermost layer is that of Langhans, forming a single or double row of spindle-shaped cells immediately covering the stroma. In the early months of pregnancy Langhans' layer is clearly defined, but in the later months it may wholly lose its identity.

FIG. 47.

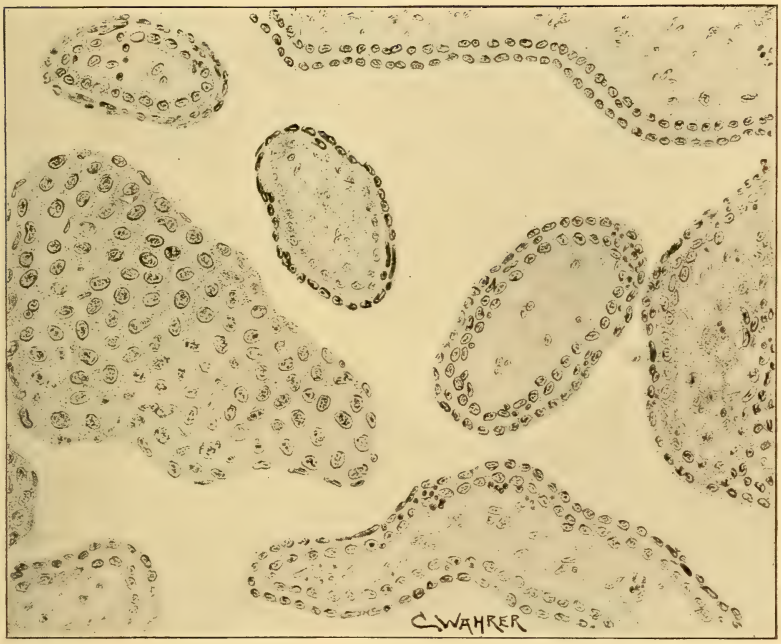

Scrapings from a puerperal uterus. Chorionic villi and decidua are seen. There are no degenerative changes.

Overlaying Langhans' layer is the syncytium, an irregular band of protoplasm containing many nuclei and vacuoles. The nuclei are round or oval, and take a deep stain. The protoplasm is finely granular, and contains vacuoles of considerable dimensions. Giant-cells and buds spring from the syncytium particularly at the top of the villus; these also contain nuclei and vacuoles.

The presence of chorionic villi in discharged membranes is proof positive of a uterine pregnancy.

The *decidua* may be regarded as the endometrium of pregnancy.

It is, therefore, a maternal structure. The endometrium becomes thickened even to tenfold. This thickening is due to an increase in size of the various elements of the endometrium. From the beginning of pregnancy the connective tissue cells of the mucosa increase in size four and even six times their original proportions. This growth is due more to an increase in the cell protoplasm than to the cell nuclei. These hypertrophied connective tissue cells are

Fig. 48.

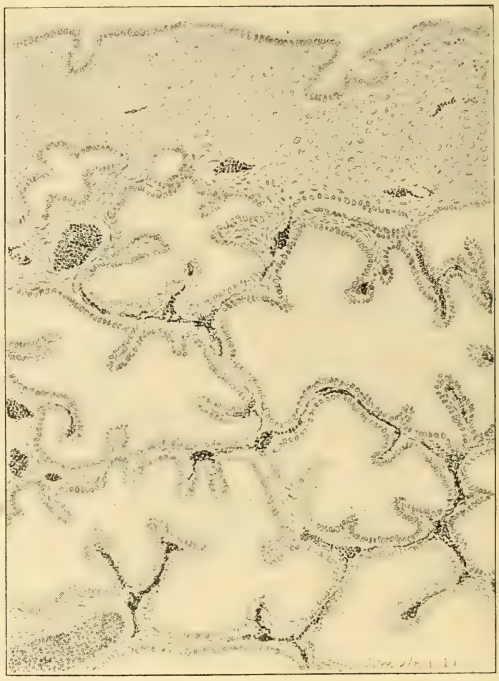

Decidua of early pregnancy. The glands are large, irregular, and lined by a single layer of columnar epithelium. The interglandular connective tissue is relatively scant.

known as decidual cells. In form they closely resemble squamous epithelium. The connective tissue spaces are almost wholly obliterated by compression.

Veins and arteries which in the mucosa of a non-gravid uterus are scarcely visible in the decidua are large blood channels and spaces.

It is most important to consider the changes in the glands. They become greatly enlarged and tortuous. Near their outlet the surrounding decidual cells compress the gland, and deeper in the

decidua the glands are tortuous and enormously increased in size. These glandular changes divide the decidua into a compact and spongy layer. Above is the *compact layer*, where the glands are compressed and the decidual cells are closely packed together; below is the *spongy layer*, where the decidua is honeycombed by distended, tortuous glands. In the expulsion of the placenta the line of cleavage is within the compact layer. The regeneration of the glands and surface epithelium originates in the gland epithelium of the spongy layer.

The epithelium of the glands is transformed from the cylindrical type to the cubical or flattened, containing but little cell protoplasm and closely resembling squamous epithelium. Many layers of squamous epithelium have been observed. It is evident that a diagnosis of glandular endometritis or of malignant adenoma might be made where pregnancy is unsuspected.

CHAPTER XVI.

THE MICROSCOPIC DIAGNOSIS OF EXPELLED MEMBRANES FROM THE UTERUS.

THE physician will be called upon to determine the nature of a membrane or mass spontaneously expelled from the uterus. Here the microscope is indispensable. It is of prime importance to first determine whether or not the membrane is organized. Placing the membrane in cold water, if it becomes friable and disintegrates it is unorganized. Under the microscope a fibrinous structure is seen, in the meshes of which are blood cells in all stages of disintegration.

FIG. 49.

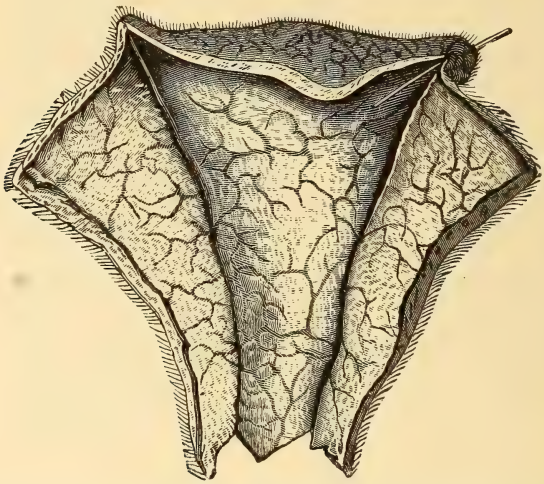

Cast from uterine cavity in exfoliative endometritis, membranous dysmenorrhœa, natural size. (After COSTA.)

Calcareous concretions may be expelled spontaneously or removed by the curette. They most probably come from calcareous deposits in mucous polyps or submucous fibroids.

Of the organized structures, we will consider the decidua of intra-uterine pregnancy, the decidua of extra-uterine pregnancy, and the decidua of menstruation. The following table will give an exact presentation of the practical points in the differential diagnosis of these structures :

PLATE XVI.

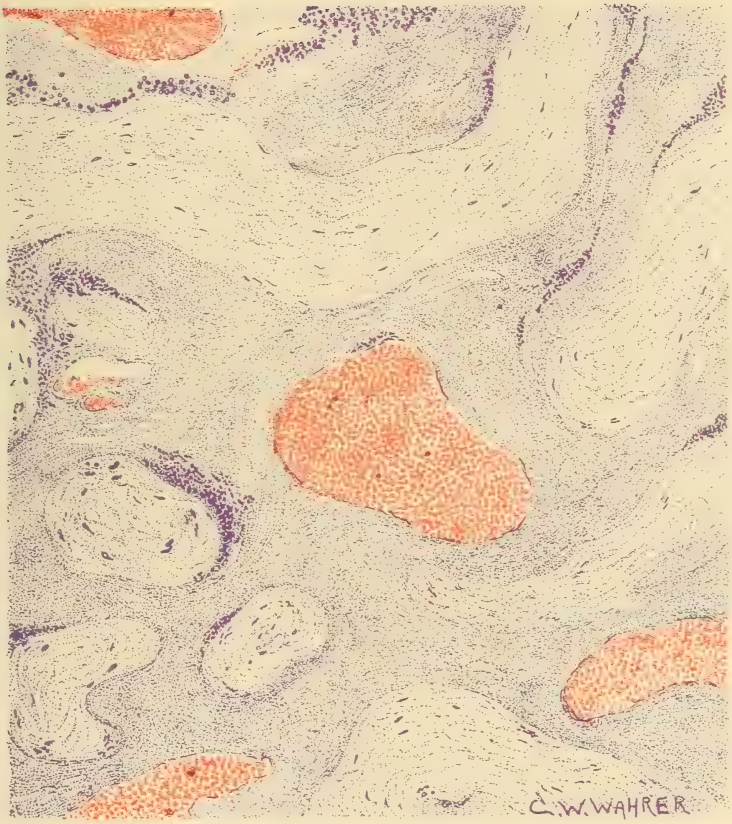

"Placental Shadows."

The section represents placental tissue scraped from the uterus ten weeks after an abortion. The degenerated villi are shown as "shadows." Islets of old blood are seen between the villi.

THE DIAGNOSIS OF EXPELLED MEMBRANES.

	Decidua of intra-uterine pregnancy.		Decidua of extra-uterine pregnancy.	Decidua of menstruation.	
Clinical features.	Symptoms and signs of pregnancy; hemorrhage and pain accompanying the discharged membrane; no extra-uterine pelvic tumor.		Symptoms and signs of pregnancy; often irregular; hemorrhage and pain accompanying the discharged membrane; extra-uterine pelvic tumor.	No evidence of pregnancy. No extra-uterine pelvic tumor.	
Macroscopic findings.	Thick shreds with shaggy surface, or smooth, glistening membrane.		Rough fibrous membrane; no villous structures; irregularities on inner surface.	*Unorganized.* Fibrinous structure, external surface smooth, internal surface rough.	*Organized.* Triangular cast of uterus, or bits of membrane; surface smooth with sieve-like depressions.
Microscopic findings.	Surface epithelium.	Seldom present	Flattened; may be wanting.	Absent.	Cylindrical, rarely flattened.
	Glands.	Compressed above, widely dilated and very irregular below; epithelium flattened.	Changes similar to intra-uterine pregnancy, though less marked.	Absent.	Zig-zag in their course; epithelium cylindrical.
	Stroma.	Typical decidual cells.	Decidual cells not so large; more intercellular substance.	Fibrinous.	Round-cell infiltration; protoplasm of cells increased.
	Vessels.	Very widely dilated; walls composed of endothelium; no musculature.	Less widened blood spaces.	Absent.	As found in endometritis.
	Fœtal tissue.	Chorionic villi amnion.	Absent.	Absent.	Absent.

Decidual cells are hypertrophied connective tissue cells. There are causes of hypertrophy of these cells other than pregnancy, and hence it is that decidual cells are not pathognomonic of pregnancy. The only positive evidence of pregnancy in discharged membranes is the presence of chorionic villi.

CHAPTER XVII.

THE DIAGNOSIS OF ECTOPIC PREGNANCY.[1]

Etiology. I. **Predisposing Causes:** 1. Mechanical interference with the passage of the ovum through the tube from—

(*a*) Tumors in and about the tube.

(*b*) Persistence of the fœtal type—small lumen and convoluted course of the tube.

(*c*) Peritoneal bands constricting the tube and drawing it out of position.

(*d*) Congenital anomalies in development, namely, diverticuli, rudimentary fimbriæ.

(*e*) Malposition of the tube, either congenital or acquired.

2. Loss of cilia and epithelium through inflammation.

II. **Essential Cause.** While the above conditions are frequently present, it is a matter of common observation that tubal pregnancy may occur in an apparently normal tube.

Webster affirms that in ectopic pregnancy there is a genetic reaction in the tube which is essential to the implantation and development of the ovum in the tube as truly as is a similar genetic reaction in the uterus essential to uterine gestation. This genetic reaction consists in the formation of decidual tissue. It is claimed by Webster that a decidua, however limited, is always to be found in the pregnant tube. Without a decidua the ovum would find no abiding place in the tube, even in the presence of the above-named predisposing causes. In the event of a decidual formation in the tube these predisposing causes will serve to obstruct the passage of the ovum, making possible the implantation of the ovum in the tube rather than in the uterus. This genetic reaction has never been discovered in the ovary or in the peritoneal cavity, and hence it is that primary ovarian or abdominal pregnancy has never been positively demonstrated.

Ectopic pregnancy may occur at any time during the period of sexual maturity, but with greatest frequency between the ages of

[1] The author acknowledges his indebtedness to J. Clarence Webster, from whose monograph on "Ectopic Pregnancy" much of the material in this chapter has been taken.

thirty and forty. It is stated that a long period of sterility predisposes to ectopic pregnancy, probably because of the existence of one or more of the above-named predisposing causes. Tubal gestation occurs five times as frequently in multipara as in primipara—a fact which may again be explained on the ground of the development of the above predisposing causes. We occasionally see reports of cases in which a second, third, and even fourth gestation has occurred in the same tube, or has occurred alternately in both tubes.

Pregnancy seems as frequent in one tube as in the other. Multiple ectopic pregnancy is possible—that is, an ovum in either tube, a twin pregnancy in a single tube, a normal uterine pregnancy

Fig. 50.

Ectopic gestation in blind accessory fimbriated extremity of the right tube. (Jewett.)

together with a tubal pregnancy, and, finally, uterine pregnancy together with pregnancy in both tubes. Hanna finds sixty-nine cases of tubal pregnancy associated with uterine pregnancy.

There is no evidence of a uterine pregnancy occurring during the course of a tubal pregnancy. In nearly three-fourths of the cases the ovum develops in the ampullary portion of the tube and with about equal frequency in the interstitial and fimbriated portions.

Classification. I. **Ampullar tubal pregnancy**, in which the gestation begins in the ampullar end of the tube. Ampullar tubal

pregnancy may persist as such, or the gestation sac may rupture from the tube.

1. Persistent. In rare instances the gestation in the ampulla may go to full term. The gestation sac is pedunculated, movable, incarcerated, or fixed by adhesions. When confined to the pelvis the uterus and ovary are crowded to the opposite side; when large and lying in the abdominal cavity the uterus may not be displaced. As a rule, the gestation sac lies at the side of or behind the uterus, rarely between the bladder and uterus. Adhesions may firmly bind the tube, uterus, and ovary together.

Fig. 51.

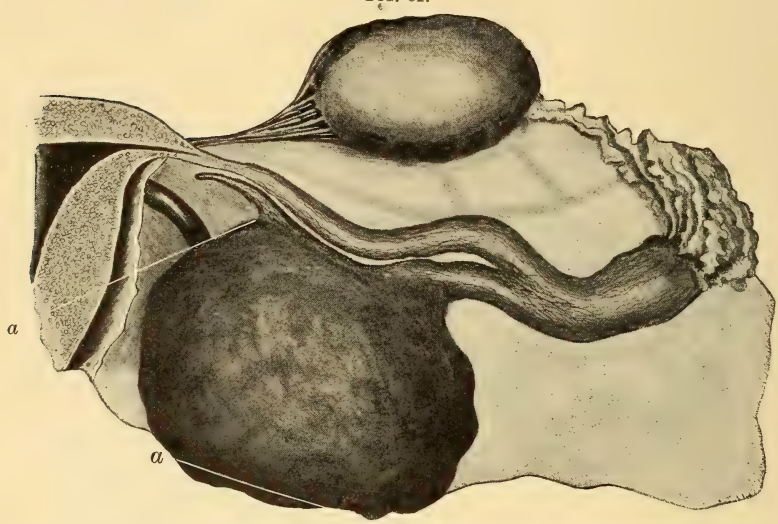

Left Fallopian tube, with ectopic gestation in diverticulum. *a*, *a*. Gestation sac communicating with diverticulum. (Jewett.)

2. Rupture may occur early. The most likely exit is between the layers of the broad ligament, though not infrequently it ruptures into the free peritoneal cavity.

(*a*) *Subperitoneo-abdominal gestation*, in which the ovum escapes through the lower segment of the tube between the layers of the broad ligament. Here the ovum may perish or go on to full development. Rupture usually takes place not later than the fourteenth week. The escape of the fœtus and blood may be gradual or abrupt. So gradual may the process be that no general disturbance will be caused, and, on the other hand, the fœtus and blood may be discharged in such a manner as to occasion profound shock.

As the gestation sac enlarges the layers of the broad ligament are separated, the pelvic viscera are pushed to one side, the peritoneum is stripped from the bladder, uterus, rectum, and pelvic wall. Later, as the gestation sac increases in size, it burrows beneath the parietal and visceral peritoneum, crowding the viscera forward and to the side.

The placenta may remain attached to the tube or escape with the fœtus between the layers of the broad ligament and become attached to any of the raw surfaces. The tube may be stretched out over the gestation sac as a mere ridge. Rupture into the peritoneal cavity may take place at any time after the escape of the ovum

Fig. 52.

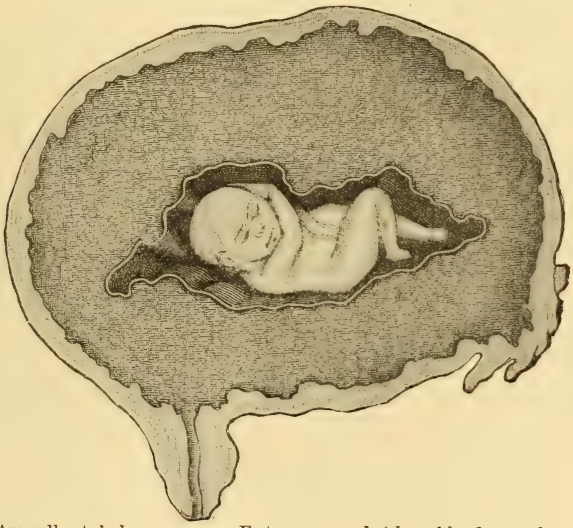

Ampullar tubal pregnancy. Fœtus surrounded by a blood coagulum.

and blood between the layers of the broad ligament. The danger to life in such an event is imminent, and immediate surgical interference is imperative.

Gestation Comes to an End. 1. *By the formation of a hæmatoma.* The accumulated blood destroys the life of the fœtus. The lower the attachment of the placenta the greater the hemorrhage, and hence the greater liability of destroying the life of the fœtus. The blood undermines the peritoneum, sometimes encircling the uterus and rectum, and displacing the viscera. Coagulation of the blood is rapid, and eventually complete absorption of the clots or the organization of the clots into adhesions follows.

2. *By Suppuration.* This event is usually late. It is unusual for an acute abscess to follow an hæmatoma of the pelvis. The more intimate the relation to the bowel the greater the liability to suppurate. If the abscess is not opened by surgical intervention it may become absorbed, but will almost surely find its way to a hollow viscus or externally through the vagina or abdominal wall. Parry reports a case in which rupture occurred thirty-two years after the formation of an abscess. Twelve cases are recorded in which the fœtus was discharged through the bowel.

(*b*) *Tuboperitoneal gestation,* in which the placenta remains in the tube and the fœtus escapes into the peritoneal cavity. The probability of such a condition was long held impossible. The first authentic case reported was that of Croom. Webster made sectional, dissectional, and microscopic studies of the case, and proved the existence of tuboperitoneal gestation beyond dispute. Webster holds that it is as yet unproven that a fœtus can escape into the peritoneal cavity free of its investing membranes and then develop to full term; he doubts the probability of such an occurrence. Furthermore, it is as yet unproven that the early complete ovum can escape into the peritoneal cavity and there go on to develop. As stated by Webster, it is inconceivable that a villous covered ovum can escape into the peritoneal cavity and there await the development of intervillous blood spaces.

Gestation may terminate by rupture of the tube and escape of blood into the free peritoneal cavity. The amount of blood lost may be insignificant and occasion no constitutional effects; while, again, the blood may instantly escape in such large amounts as to jeopardize the life of the mother and fœtus unless surgical intervention is prompt. The consequences to the mother are, therefore, dependent upon the extent of the tear, the rapidity with which the blood is allowed to escape, and, finally, upon timely surgical interference. The fœtus may plug the opening and prevent the escape of much blood, or the blood may escape at intervals and eventually assume large proportions without seriously depressing the patient.

Interrupted hemorrhage may also be due to contraction and retraction of the tube and bloodvessels. Though the quantity of blood lost in an interrupted hemorrhage may be equally as great as in the immediate escape of an equal amount of blood, the effect upon the mother is far less serious. The later in pregnancy the rupture occurs the more serious the consequences, because of the unusual size

PLATE XVII.

Secondary Abdominal Pregnancy at Eight Months, Primarily Tubal. The primary attachment of the placenta is plainly discernible at the original tubal site. After rupture the placenta grew and became attached to a large surface on the anterior abdominal wall. The child was delivered through a retro-uterine vaginal incision.

of the rent, the failure of the muscular wall to retract, the presence of large blood sinuses, and the failure on the part of the fœtus to be absorbed.

Prior to the end of the second month, if rupture takes place, the hemorrhage will usually not be great, and the fœtus will almost certainly be absorbed. Rupture has been known as early as the second week. The time of greatest frequency for rupture to occur is from the sixth to the fourteenth week. The greatest number rupture in the second month.

The escaped blood accumulates in the most dependent portion of the pelvic cavity. There it is rapidly coagulated, and is later absorbed, suppurates, or is organized.

FIG. 53.

Primary intraperitoneal rupture; fifth week. Tube completely ruptured. *a*. Ovum still slightly adherent to its original site. (JEWETT.)

Fritsch says there is no case of pelvic hæmatocele in which ectopic pregnancy can be positively ruled out; while, on the other hand, such authorities as Kober and Freund have reported cases. It is unusual for acute peritonitis to follow the development of a hæmatocele, though it is the rule for peritoneal adhesions to form about the mass of escaped blood.

GESTATION MAY BE DESTROYED. 1. *By the Event of Tubal Abortion.* By tubal abortion is meant the escape of the ovum through the fimbriated end of the tube into the peritoneal cavity. This implies that the tube must be patent at its fimbriated end. The contractions of the tube expel the ovum, forcing it in the direction of least resistance. The nearer the attachment of the ovum to the fimbriated end of the tube, the greater the liability to abortion. Hemorrhage is rarely considerable. All that has been

said of tubo-abdominal gestation in reference to the fate of the mother and ovum applies to tubal abortion, though with less force. The hemorrhage is rarely so great and the fœtus is usually absorbed. Hence the mother may and, indeed, often does suffer but little.

2. *By the Formation of a Mole.* The fœtus dies and is preserved in its entirety, forming a fleshy mole. The death of the ovum is

Fig. 54.

Intraligamentary rupture of a tubal pregnancy. Rupture at the isthmus, with escape of the fœtus.

caused by an escape of blood into the fœtal membranes. At first the mass appears like a fresh, firm, blood clot. Later it organizes and becomes paler as the blood absorbs and organizes.

3. *By the Formation of an Abscess.* Secondary infection of the ovum and escaped blood, as a rule, occurs through the bowel. In this manner a pyosalpinx may be formed, leaving no trace of pregnancy.

PLATE XVIII.

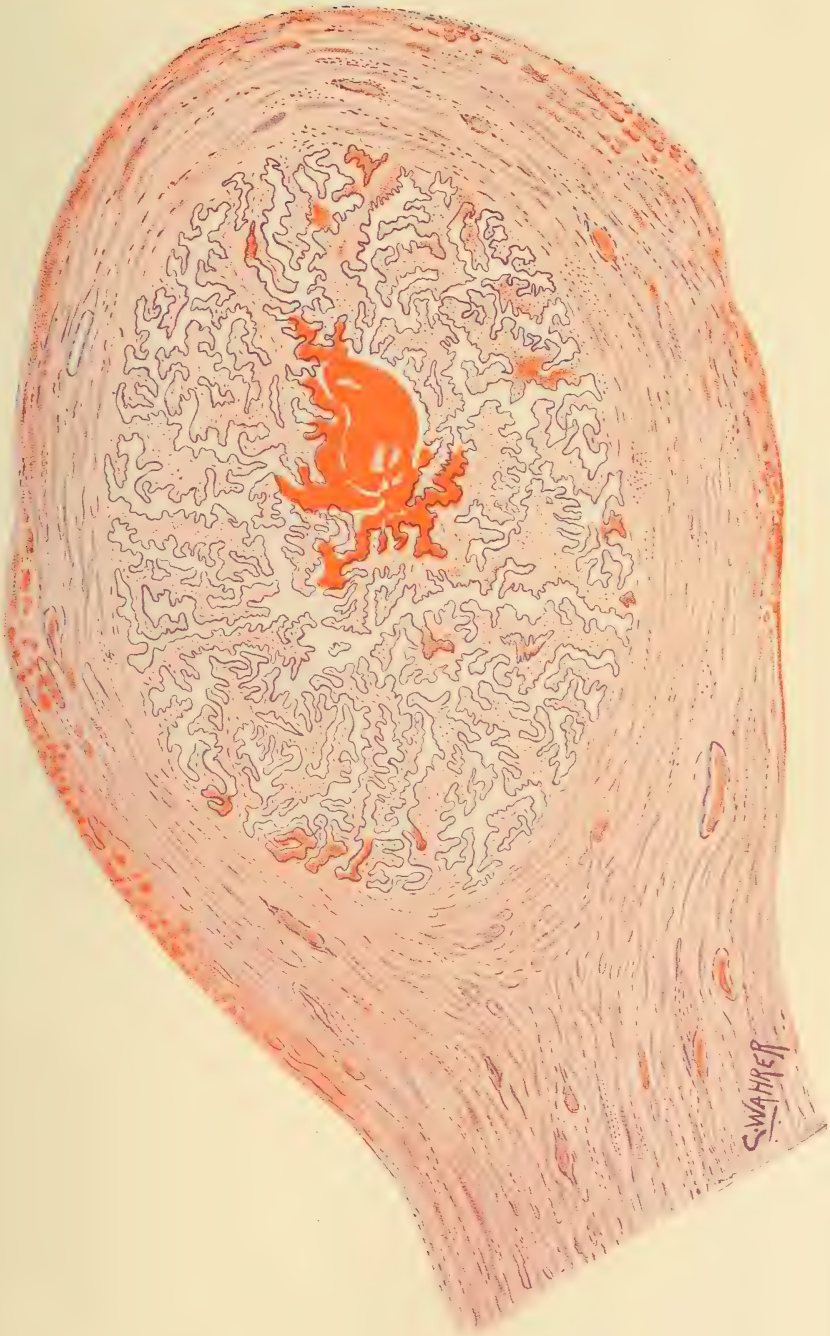

Tubal Pregnancy.

The wall of the tube is thickened. The villi are vascular and near the centre of the lumen. Entangled in the meshes of the villi is an irregular blood clot containing numerous syncytial cells—this represents the fœtal remains.

4. *By the formation of an adipocere, a lithopedion or mummy,* where the fœtus is far advanced in its development.

II. **Interstitial tubal pregnancy,** in which that portion of the tube lying within the uterine wall encloses the gestation sac. This is an unusual location. There may be tubo-uterine pregnancy, in which the ovum lies partly within the interstitial portion of the tube, partly within the uterine cavity. Again, the ovum may first develop within the interstitial portion of the tube, and later be expelled into the cavity of the uterus ("tubal abortion"). The gestation sac forms a part of the uterine tumor, and lies within the attachment of the round ligament—all other forms of tubal pregnancy lie external to the round ligament. Interstitial pregnancy may go on to full term; the fœtus may die at any period of its development, or, finally, rupture of the tube may permit the ovum to escape into the uterine cavity, between the layers of the broad ligament, or directly into the peritoneal cavity. In any event, the resulting hemorrhage may be fatal.

III. **Infundibular tubal pregnancy,** in which the ovum is found in the infundibulum. This is an unusual condition. The behavior is similar to that of ampullar pregnancy. The tube is likely to adhere to surrounding structures, and by adhering to the ovary a tubo-ovarian pregnancy becomes possible.

RETROGRESSIVE CHANGES IN A DEAD FŒTUS.

1. *Mummification* is a process of desiccation, the water being extracted from the fœtus. In addition a deposit of earthy salts is often superimposed.

2. *Calcification,* in which the fœtal membranes and placenta, rarely the superficial parts of the fœtus, are permeated and incrusted with lime salts. There is rarely formed a dense incrustation. It is not uncommon for an adhesive peritonitis to be set up about the lithopedion. The petrified ovum may remain in the tube, in the peritoneal cavity, or between the layers of the broad ligament for years without creating serious disturbance. Well-formed children may be born while the parent still carries a lithopedion. Death may result from peritonitis.

3. *Adipocere formation,* in which the ovum is converted into a soap-like mass. Calcareous deposits may be found in the adipocere.

4. *Gangrene of the fœtus* may result, and if surgical interference is not instituted death from septic infection and peritonitis will follow.

It is possible for a perfectly healthy and well-formed child to be delivered by surgical means, but, as a rule, the fœtus is poorly developed and not viable.

ANATOMICAL CHANGES IN THE TUBE.

Mucous Membrane. In the tubal mucosa decidual changes are always to be found (Webster). This view is not universally accepted. Webster has never failed to demonstrate a decidua in the tube, but finds great variation in the location and extent of the development. The early specimens more clearly show this so-called genetic reaction than do the advanced cases. The decidua may be confined to a narrow ring about the tube. It is, therefore, not strange that conflicting statements are made concerning the presence of a decidua in the tube. It is often necessary to make sections from various portions of the tube.

As in uterine pregnancy, so in the tube we find a decidua vera, reflexa, and serotina. The decidua vera is composed of a spongy and compact layer, as in uterine pregnancy. In the compacta the decidual cells are closely packed together, while in the spongy

---

EXPLANATION OF FIGS. 55 TO 61.[1]

Fig. 55. Side view. Pregnancy complicated by hæmatocele of both broad ligaments; blood clot posterior and to either side of the uterus, crowding the cervix forward.

Fig. 56. Retro-uterine hæmatocele extending into both broad ligaments, the mass on the one side rising much higher than on the other, so that accumulation of blood feels to the touch like two distinct masses closely set together and sharply rounded above and at the sides.

Fig. 57. Front view. Hæmatocele of left broad ligament extending anterior to the uterus; felt as a hard tumor in the left vaginal vault close to the uterus; easily felt through the vagina and in the left inguinal region.

Fig. 58. Retro-uterine hæmatocele lifting the peritoneum high out of the cul-de-sac of Douglas, and extending into both broad ligaments. Easily felt on vaginal and abdominal palpation.

Fig. 59. Front view. Hæmatocele in both broad ligaments extending in front of the uterus; tumor larger on the right side than on the left, and divided on the left into two segments. The mass on the left side communicates with that on the right, high up in front of the cervix. Uterus pushed back to the posterior wall of the pelvis.

Fig. 60. Side view. Retro-uterine hæmatocele, not extending to the sides of the pelvis. Mass felt between the uterus and rectum, lifting the peritoneum out of the cul-de-sac of Douglas, and crowding the uterus forward.

Fig. 61. Front view. Hæmatocele of the left broad ligament, lying close to the uterus; easily felt through by vaginal touch and by palpation over the left iliac region. Crowds the uterus forward and to the right.

[1] Suggested by Kuhn, in Veit, Handbuch der Gynäkologie.

FIG. 55.

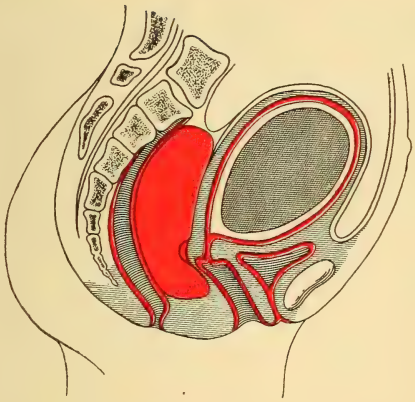

FIG. 58.

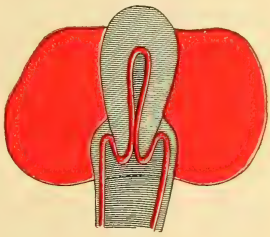

FIG. 59.

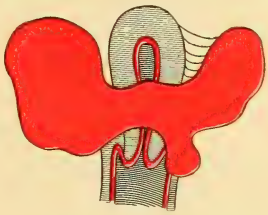

FIG. 56.

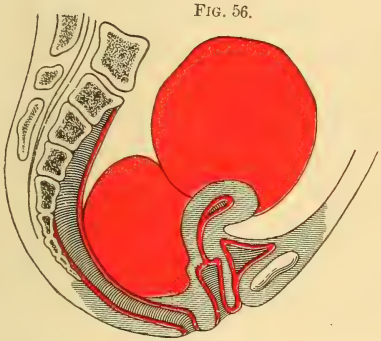

FIG. 60.

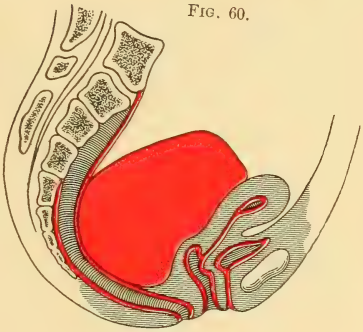

FIG. 57.

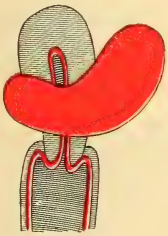

FIG. 61.

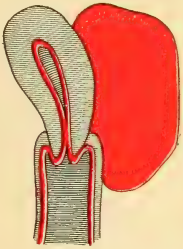

layer they are separated by gland-like spaces formed by mucous folds. In later months the distinction between the compact and spongy layers is lost. In the earlier stages the surface epithelium remains intact, but as time goes on the cilia are lost, the cells become flattened, and, finally, wholly disappear. As in the endometrium, the decidual cells are derived from the connective tissue of the mucosa. They are essentially greatly enlarged connective tissue cells, and show great variation in size and form. In far advanced cases these cells become elongated into a fibrous structure, losing their decidual character.

The decidua serotina, that portion of the decidua known as the placental site, is relatively larger than is the serotina of the pregnant uterus.

The decidua reflexa may or may not be present. Some authorities disclaim its existence. As stated by Webster, the tube lumen may be so small that the ovum pressing upon the wall of the tube makes the formation of a decidua reflexa impossible. On the other hand, the tube lumen may be exceptionally large, in which case a complete reflexa may be formed. As the ovum develops the reflexa becomes thin and early disappears.

Beyond the attachment of the ovum the tubal mucosa may not suffer change. Not infrequently decidual changes are recognized throughout the entire mucosa of the tube. As the ovum enlarges and fills the tube the surface epithelium is compressed and wholly disappears; so, also, with the decidua.

The muscular wall of the tube varies in thickness in different sections and in the various stages of pregnancy. In the early months the musculature thickens through hypertrophy. In the later months pressure and stretching of the musculature may cause all traces of muscle fibres to wholly disappear.

The peritoneal covering of the tube is stretched by the growing ovum. Inflammatory adhesions may form about the tube.

Regarding the fœtal membranes, there is little that differs from the membranes of normal uterine gestation.

The Clinical Diagnosis of Ectopic Pregnancy. THE CLINICAL DIAGNOSIS OF ECTOPIC PREGNANCY is made, first, by establishing the fact of pregnancy, and, second, by locating the gestation sac. The subjective signs are of value in establishing the fact of pregnancy, but the location of the gestation sac can only be determined by a physical examination.

The **subjective signs** may not differ materially from those of uterine pregnancy of a similar age. In the early weeks of an ectopic gestation the patient is seldom aware of any unusual complications, while in the later months the symptoms seldom conform to those of normal pregnancy, and will give rise to feelings of apprehension on the part of the patient. Not so with the physical signs; these are to be differentiated from the normal from the earliest time.

1. *Cessation of menstruation* occurs in about one-half of the cases. The hemorrhage when present comes from the endometrium.

2. *Morning sickness* occurs at about the same time and to about the same extent as in uterine pregnancy.

3. *Nervous phenomena*, such as ringing in the ears and despondency, are likely to be exaggerated above that of normal uterine gestation.

4. *Periodic colicky pains* are unlike anything that should occur in normal uterine pregnancy. It is this incident that commonly first attracts the patient's attention to her condition. These pains are said to be due to the contractions of the uterus and pregnant tube. In character they are intermittent and cramping, and are located in the region of the uterus and affected tube. During these pains rupture of the gestation sac may occur.

The objective signs differ essentially from those of uterine gestation.

1. *The mammary glands* do not often show the marked changes accompanying uterine pregnancy. The areola is poorly marked and the secretion of cholostrum is scant.

2. *Discoloration of the vulva and vagina, softening of the vaginal portion of the cervix and compressibility of the lower uterine segment* may all be present, but seldom to the degree found in uterine gestation.

3. *Active fœtal movements* may be recognized earlier and with greater ease than in uterine pregnancy, provided the fœtus lies in close proximity to the abdominal wall. Later on the movements may be readily seen through the parietes.

4. *Intermittent uterine contractions* are often present, though not to the degree found in uterine pregnancy.

5. *Direct palpation* of the fœtal parts may be very difficult and obscure, or very easy, depending upon the relation of the fœtus to the abdominal wall.

6. *Auscultation.* *a.* Fœtal heart tones are heard, with varying degrees of distinctness, depending upon the development of the fœtus, its relation to the abdominal wall, and upon the thickness of the latter.

b. The fœtal souffle is rarely heard, and only in the latter half of pregnancy.

c. The placental souffle is rarely heard after the third month, and only on the side occupied by the gestation sac.

7. *The rate of growth, form, position, and consistency of the uterus* varies considerably from that of uterine gestation. While the uterus almost always enlarges, it never attains a greater size than that of a four months' pregnant uterus, and does not enlarge regularly and progressively as does the gravid uterus. The nearer the gestation sac is to the uterus the larger the uterus develops. Cases are recorded in which the uterus did not develop, but these are exceedingly rare.

The general contour of the uterus differs somewhat from that of the normal pregnant uterus. It retains much the same form as does the non-pregnant uterus. The transverse diameter is proportionately less, and there is no shortening of the cervix in advanced cases.

The uterus seldom lies in the median line, but is crowded to one side by the gravid tube.

In consistency the uterus changes, but not to the degree found in uterine gestation.

8. *The discharge of the uterine decidua* is an event peculiar to ectopic pregnancy. Part or all of the uterine decidua may be expelled at any time during the course of an ectopic pregnancy. As a rule, the decidua is expelled piecemeal, rarely in its entirety. Much blood may accompany the discharged decidua and completely mask the accompanying fragments. Where ectopic pregnancy is suspected the escaped blood should be carefully preserved by the nurse for the inspection of the physician.

Histologically, the uterine decidua of ectopic pregnancy does not differ essentially from that of uterine gestation, the distinguishing feature being the absence of fœtal structures.

Spurious Labor. At full term pains not unlike those of labor come on and constitute what is known as spurious labor. These pains may occur weeks before the end of full term, and, on the other hand, may altogether fail or be delayed one or more months beyond full term. The pains commonly continue a number of

hours, as in normal labor, but have been known to persist for a week and longer. They vary in intensity and location ; often they are severe and located in the side of the pelvis. A bloody discharge appears shortly after the onset of the pain, and with it there is usually a discharge of decidual membrane. The amount of blood lost may be alarming.

Following spurious labor the fœtus always dies, the liquor amnii becomes absorbed, the gestation sac contracts, and the fœtus undergoes changes previously referred to, namely, mummification, lithopedion, gangrene, and adipocere formations.

9. "*Intraperitoneal Hemorrhage.* It may be stated at the outset that its signs and symptoms consist, speaking generally, of the signs and symptoms of an acute and sudden abdominal lesion *plus* those of severe internal or concealed hemorrhage, and that whenever these are present in a female patient during the childbearing age, the probability of their being due to a disturbed ectopic gestation should be vividly present to the physician's mind. The first symptom is the occurrence of a sudden and severe pain in the abdomen, accompanied very often with vomiting. The patient almost immediately expresses herself as feeling extremely faint and ill. She is quite conscious, and remains so. The abdomen is often more or less distended and rigid, and it becomes excessively tender. There is soon noticed, along with the usual signs of collapse, a gradually increasing pallor of the surface. The pulse increases in frequency, without, at first, any corresponding rise in temperature, and becomes weaker and more compressible. Presently it is only now and then that it is perceptible, and finally it cannot be felt at all. The patient complains of feeling more and more faint ; her pain perhaps abates ; she becomes restless, sometimes vomits, often sighs deeply, yawns and exhibits other signs of weariness, and, if left untreated, gradually sinks, maintaining a perfectly clear intellect to the last.

"Such is a picture, imperfect, as all attempts to describe such a condition in words must be, of the clinical aspect of a patient with diffuse intra-abdominal hemorrhage. Now and then the bleeding becomes spontaneously arrested, the patient rallies, and, if no fresh outburst occurs, the blood becomes gradually absorbed and the patient recovers. But the condition is one in which no such fortunate result can be counted upon, and in which the tendency is not to recovery, but to death, and to very speedy death, for the

majority of cases end fatally within forty-eight hours, and many within a much shorter time. In the case of the wife of a medical friend of my own, death occurred within three hours from the beginning of the attack.

"If I were asked upon what points I should principally rely in diagnosing this condition, I should be disposed, in the light of my own experience, to enumerate the following, viz.:

"(*a*) The fact that at the moment of the attack the patient was in her usual health. This circumstance would render it highly improbable that the symptoms were due to gastric or intestinal perforation or to rupture of an internal abscess or suppurating cyst.

"(*b*) The gradually increasing pallor of the patient and the gradually rising pulse rate (without corresponding rise of temperature), both being indicative of internal hemorrhage.

"(*c*) The extreme tenderness of the abdomen. To this symptom I have learned to attach a very special value. It often misleads the medical attendant into supposing that there is acute general peritonitis. It cannot, therefore, be too strongly insisted upon that marked, and even excessive, abdominal tenderness does not necessarily indicate an inflammatory condition. It is met with, for instance, over ovarian tumors when, as the result of rotation of the pedicle, they have become the seat of hemorrhages, intracystic and intramural. It is quite true that peritonitis is a not infrequent later result of this accident, but this marked tenderness may be observed when, on opening the abdomen, there is no visible sign of inflammation.

"(*d*) If a menstrual period has been missed or is overdue, the diagnosis of the case is greatly facilitated; but it does not follow that because menstruation has been regular rupture of an ectopic gestation may be excluded. For some of the most appallingly sudden cases of rupture occur (as I hope to point out later) at a very early stage of the pregnancy, even, it may be, before a single period has been missed. Hence arrested menstruation is not essential to the diagnosis, though when present it is a valuable help to it. If in addition to the arrested or delayed menstruation there is morning sickness, the diagnosis is even further facilitated. But, after all, these signs of early pregnancy do not prove very much. They do not even prove that the pregnancy, if present, is ectopic, or that, whether it is or not, it has anything to do with causing the present illness. All that can be said is that when symptoms are

present that suggest the possibility of a ruptured ectopic gestation these signs of pregnancy serve to confirm the suspicion.

"These are, so far as I have been able to observe, the *main* helps to a correct diagnosis.

"There still remains to be considered one or two other points of diagnosis of less importance than those just indicated.

"It is frequently stated in text-books that when there is intra-abdominal hemorrhage there will be the usual signs of the presence of free fluid in the peritoneal cavity. In a case of very extensive effusion, and in a patient without much fat in the abdominal wall, it may be possible to obtain evidence of fluctuation and of dulness in the flanks, shifting on change of posture, but such evidence is not usually forthcoming.

"Lastly, a word must be said as to the evidence obtainable by vaginal examination. Here, again, the signs are not very definite. There is no distinct circumscribed swelling to be felt, as in the case of encysted effusions (pelvic hæmatocele). All that can be made out is, in the words of my friend Mr. John W. Taylor, 'a full and boggy condition of the pouch of Douglas, suggestive,' to the experienced finger, 'of the presence of fluid or semiclotted blood within the pelvis, but,' as he goes on to say, 'the symptoms denoting that a lethal hemorrhage is actually taking place are of chief importance.'

"There is very often a slight hemorrhage going on from the vagina, generally regarded by the patient either as due to the appearance of a delayed menstrual period, or, if she believes herself to be pregnant, as indicating the probability of a miscarriage.

"Owing to the gradual subsidence of the pain, and the patient's freedom, as a rule, from anything like alarm about herself, the extreme gravity of the condition may easily be overlooked. In fact, as Mr. Taylor has pointed out, it is more frequent to find that the medical attendant has failed to appreciate the danger than that he has made an incorrect diagnosis" (Cullingworth).

10. *Bimanual Examination.* An anæsthetic will be found of immense advantage in making a bimanual examination. Great variations are observed in the local findings of ectopic pregnancy. Vessels are felt to pulsate in the vaginal vault, particularly on the side of the gestation sac. The vagina may be displaced and misshaped by the gestation sac and accumulated blood above. The vaginal walls are made to bulge at the sides and behind the uterus, and the vagina may be pushed far to one side.

The uterus is almost invariably displaced by the tumor mass. The most common displacement is forward and upward, because of the frequency with which the blood collects in the pouch of Douglas. The uterus is elongated, but is never so broad as in uterine gestation of a similar period of development. Its consistency is firmer than in uterine pregnancy, the lower uterine segment is not well-marked, and the cervix is not shortened.

The pregnant tube is not unlike the inflammatory swellings of the tube. Without other evidences of pregnancy it would be impossible to say, with assurance, that the tube is pregnant and not distended with blood, pus, or serum. As in sactosalpinx the pregnant tube commonly lies low at the side of or behind the uterus.

In interstitial pregnancy the gestation sac forms with the uterus a single mass, distinguished by a more elastic consistency as contrasted with the firmer uterine tissue.

Differential Diagnosis. 1. **Pregnancy in a Retroverted Uterus.** Since the gestation sac of an ectopic gestation frequently lies behind the uterus, and since in the early months the size, form, and consistency of the uterus of an ectopic pregnancy does not differ widely from that of intra-uterine pregnancy, confusion is likely to arise. Here an anæsthetic examination is of the greatest value. Under anæsthesia the uterus should be located and clearly outlined apart from any mass outside. In ectopic pregnancy lying in the retro-uterine space the uterus lies well forward, and by its form and consistency can usually be outlined apart from the gestation sac. The anatomical distinctions between the pregnant uterus and the uterus of an ectopic pregnancy are to be borne in mind. In uterine pregnancy the uterus is more elastic and soft, the lower uterine segment is clearly defined, and the transverse diameter is relatively increased. The possibility of a combined uterine and extra-uterine gestation is to be borne in mind.

2. **Uterine pregnancy complicated with a tubal or ovarian swelling** may easily be confused with ectopic pregnancy. The difficulties are increased when the uterus is enlarged through inflammation (chronic metritis). Such a uterus when gravid will not have the usual elasticity and softness of a normal pregnant uterus. On the other hand, the abdominal wall and uterine musculature may be so thin as to give the impression that the fœtus lies outside the uterus. In the first trimester the physical examination of the uterus alone can only serve to suggest the possibility of pregnancy. When from

the size, position, consistency, and contour of the uterus pregnancy is suspected, the next step is to determine whether the adnexæ are enlarged from pregnancy, infection, or a new formation. The history must be carefully considered, with special reference on the one hand to pregnancy and on the other hand to infection. The pregnant tube is usually of softer consistency and less tender to pressure than are inflammatory swellings. More confusing, still, is the occasional occurrence of a tubal pregnancy implanted upon an inflammatory swelling of the tube. Here, and, indeed, in all cases, the history will be of the greatest value in making the differential diagnosis. The unilateral involvement of the tube is evidence in favor of tubal pregnancy, though bilateral tubal pregnancy is possible and unilateral involvement of the tube and ovary is common. A pregnant tube is not so likely to be fixed by adhesions as is a salpingitic swelling, and tenderness on pressure is not so great.

As a last resort, when a diagnosis is imperative, a sound may be passed into the uterus, or if there is evidence to support the belief that an abortion has occurred, the uterus may be curetted and a microscopic examination made of the scrapings. If decidua and fœtal tissue are found the pregnancy must have been intra-uterine.

If no decidua is found we are not to conclude that tubal pregnancy cannot possibly be present, because it is possible that the decidua was previously expelled.

Pelvic Exudate, Especially when Following upon an Abortion. A period of amenorrhœa may be interrupted by uterine hemorrhage.

No fœtal structures may have been recognized in the escaped blood. From such a history the examining physician is unable to decide whether it was a uterine abortion or a ruptured tubal pregnancy. If not examined until some time has elapsed and there is found a mass in the pelvis the question will arise as to whether there exists an inflammatory exudate or the gestation sac and the escaped blood of a ruptured ectopic pregnancy. If an inflammatory exudate, the history should point to a pelvic infection following the abortion, to a rise of temperature, and pain in the pelvis. The mass should be firmly fixed and tender to pressure. In ectopic pregnancy there is less tenderness and pain, and the general symptoms of sepsis are not present unless the mass has become infected. A very good general rule to be remembered is that in a pelvic

abscess the fever and high pulse rate precede the development of the pelvic exudate, while in ectopic pregnancy there is no fever or rise of pulse rate before the development of the tumor. Furthermore, with the development of the inflammatory exudate the general symptoms of infection increase, while with the sudden appearance of an escaped mass following upon the rupture of a gravid tube the temperature is likely to become subnormal.

Finally, an exploratory puncture or incision through the vaginal wall will determine the true nature of the swelling. If a pelvic abscess develops it may not be possible to determine whether it was derived from an inflammatory exudate or from a secondary infection of an ectopic pregnancy. In the removal of the pus, fœtal tissue may or may not be discovered either by the naked eye or by the microscope.

Pregnancy in a bicornate uterus may closely resemble an ectopic pregnancy. The diagnosis may be cleared up by the discovery of a septum in the vagina or cervix. It is seldom possible to palpate the round ligament, but if found to be attached to the uterus external to the gestation sac the pregnancy is either interstitial or in a horn; if the round ligament lies internal to the gestation sac a tubal pregnancy is positively present.

Pregnancy in a rudimentary horn cannot be distinguished from tubal pregnancy before opening the abdominal cavity. It is then recognized by finding the insertion of the round ligament external to the gestation sac.

Ovarian tumors may be difficult to distinguish from an ectopic pregnancy. In ovarian tumors the breasts may enlarge and secrete cholostrum, and there may be morning sickness and amenorrhœa. With the aid of an anæsthetic a bimanual examination should determine the diagnosis. As a rule, the uterus can be clearly outlined distinct from the ovarian tumor, and is found not to differ from the normal non-gravid uterus.

Rupture of an ovarian cyst may suggest a possible rupture of an ectopic pregnancy. The absence of a history of pregnancy, the presence of a long-standing tumor, and the absence of changes in the uterus suggestive of pregnancy, including a decidua, should suffice for the making of a diagnosis.

Torsion of the pedicle of an ovarian cyst may give rise to pain and symptoms of internal hemorrhage not unlike those of a ruptured ectopic pregnancy. A consideration of the points referred to in the

PLATE XIX.

Retro-uterine hæmatoma crowding the cul-de-sac of Douglas up, and the uterus upward and forward.

above paragraph on rupture of an ovarian cyst should serve in excluding rupture of an ectopic pregnancy.

An ovarian tumor complicating pregnancy is at times confusing in the diagnosis. The shape, size, and consistency of the uterus will usually serve in determining the presence of a uterine pregnancy. The great improbability of a tubal pregnancy complicating a uterine pregnancy, together with the usual signs of an ovarian cyst, will usually clear up the diagnosis. If the cyst is large it will be observed that there is an absence of ballottement, of fœtal heart tones, of fœtal movements, in what is suspected of being a gestation sac.

Fibromyoma of the uterus can scarcely be mistaken for ectopic pregnancy. There is an absence of a history of pregnancy. The uterus shows none of the changes characteristic of pregnancy. The tumor is of long standing, which, together with its firm consistency and close relation of the uterus to the tumor mass, should leave little doubt as to the diagnosis. An exploratory curettage of the uterus will fail to find a decidua.

Malignant disease of the pelvis by its irregular outline may suggest an ectopic pregnancy, and the more so when occurring in the "dodging period." The absence of the signs of pregnancy and the presence of general signs of malignancy should exclude the possibility of ectopic pregnancy.

Pelvic hæmatoma and hæmatocele not due to ectopic pregnancy are exceedingly rare. Causes other than ectopic pregnancy resulting in the formation of a hæmatoma or hæmatocele are obstructions to the outflow of the menstrual blood, rupture of varicose veins in the broad ligaments, rupture of an ovarian cyst and of the uterus. In determining the origin of the blood mass the first and most important step is the consideration of pregnancy. In long-standing cases of hæmatoma and hæmatocele following upon the rupture of an ectopic pregnancy it may be impossible to find any evidences of pregnancy either in the tube or in the uterus.

CHAPTER XVIII.

DIAGNOSIS OF HYDATIFORM MOLE.

Synonyms. *Hydatiform* degeneration of the chorion; uterine hydatids; vesicular mole; myxoma chorii; blasenmole; cystic mole; hydatid mole; dropsy of the villi.

History. In a valued contribution by R. Kossman, Berlin, we are given in the German text translations of the original manuscripts on hydatiform mole from the time of Ætius von Ameda, in the early part of the sixteenth century, to the time of Virchow, in the latter part of the nineteenth century.

Hippocrates was evidently acquainted with the condition as a cause of abortion. He states that when the "cotyledons" fill with mucus the menses become scanty; and if the woman becomes pregnant, abortion occurs after the embryo has attained considerable size.

It is interesting to note that as late as the early part of the nineteenth century it was believed that conception was not essential to the development of a hydatiform mole. Dating from the writing of Velpeau, the lesion has been universally recognized as a degeneration of the chorionic villi. Since then it has been a question as to the cause of the degeneration of the chorionic villi and the character of the degeneration. Virchow may be credited with having advanced the modern theory as to the pathological nature of hydatiform mole, though his views are not universally accepted. (See later.)

Etiology. Nothing definite is known of the immediate and remote causes of hydatiform mole. The age at which it commonly occurs is said to be near the end of the childbearing period. According to Bowin, 25 per cent. are found between the ages of forty and forty-six years. Schroeder reported one occurring at seventeen years of age. In 210 cases tabulated by the author it is seen that the average age is twenty-seven years; that the extreme ages are thirteen and fifty-eight years, and that the greatest number occurs between the ages of twenty and thirty years. As to the fre-

quency of recurrence, it is not unusual for a woman to give birth to a second mole some months or years after the expulsion of the first. In the second case here reported there was an interval of about twenty months between the expulsion of the first and second mole. Fritsch records a case in which there were four moles successively developed. Majer records eleven moles and a single child born of one woman.

It is stated that syphilis, anæmia, heart and kidney lesions, and tuberculosis are general predisposing factors in the production of

Fig. 62.

Section of the uterus with the mole in situ.

hydatiform mole, but proof of this is wanting. The question as to whether the lesion is of maternal or of fœtal origin is not fully settled. In favor of the view of the maternal origin may be mentioned the recurrence of the mole in the same individual and by different husbands; the common occurrence late in life; the partial vesicular degeneration of the chorion in the presence of a perfectly healthy fœtus; the common occurrence of cystic degeneration of the ovaries associated with hydatiform mole; and, lastly, that endometritis and nephritis commonly precede the development of hydatiform mole. In favor of the fœtal origin is the fact that in

twin pregnancy one mole alone may be involved in the cystic degeneration of the chorionic villi. If, as has been stated, death of the fœtus is a cause for vesicular degeneration of the chorion, how are we to account for the rarity of the lesion in cases of missed labor and abortion, where the fœtus has remained dead for weeks and months in the uterus? The fact that in partial vesicular degeneration of the villi the fœtus may remain perfectly healthy forces us to the more probable conclusion that extensive vesicular degeneration of the chorion results in the death of the fœtus. Contrary to the evidence advanced in support of the theory of maternal origin is the occurrence of many moles prior to the formation of the placenta, at the time when there is not an intimate anatomical relation of the mole to the uterine wall. Marchand holds that hydatiform mole occurring early in fœtal life can be ascribed to a primary change in the ovum. He does not deny the possibility of other causes operating to produce partial degeneration of the chorion, and admits as highly probable that malnutrition has much to do with the development of the mole.

Van der Hoeven examined ten hydatiform moles, of which nine were in the third, fourth, and fifth months of fœtal development; the tenth was in the first month. The last showed no vesicular degeneration of the reflexal placenta. Van der Hoeven reasoned that the ovum was healthy when it reached the uterus, and that it is possible that the disease was primary in the uterine wall, though not probable. In support of the theory of uterine origin he found degenerative changes in the endometrium. Virchow was the first to suggest the possible causal relation of endometritis to hydatiform mole. From the great frequency of endometritis complicating pregnancy as compared to the relative infrequency of hydatiform mole, it is not likely that any direct relationship between the two lesions can be established. It would be difficult to determine whether the changes in the endometrium are primary or secondary to the development of the mole. Again, the histological changes in the endometrium associated with hydatiform mole are by no means constant. It has been suggested by Baumgart, Marchand, Kaltenbach, Krentzmann, Runge, Fraenkel, and others that the tendency to cystic degeneration of the ovum may be referred to cystic degeneration of the ovaries. Each of the above-named authors has reported a case of hydatiform mole complicated by cysts of the ovary, and in a single case there was also a cystic

kidney. In my second case both ovaries were cystic, each about the size of a man's fist. In 210 recorded cases tabulated by the author in only 8 were cystic ovaries recorded. The number of abdominal incisions made in these cases is few—a fact which possibly accounts for the above statistics. On the other hand, cystic degeneration of the ovaries is so commonly observed as compared with hydatiform mole that it is not likely that they stand in the relation of cause and effect.

FIG. 63.

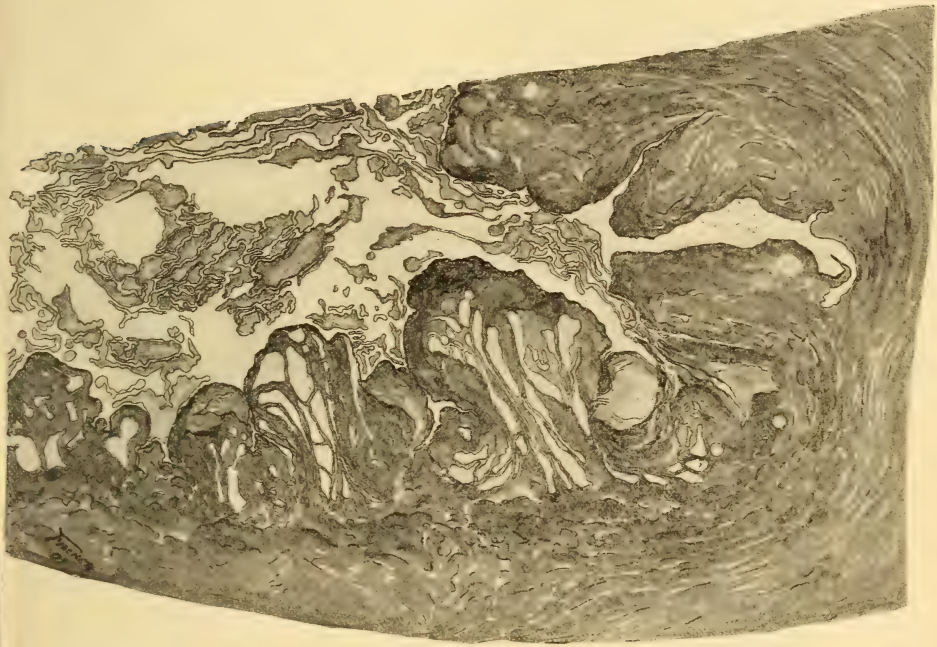

Section of the uterine musculature, decidua, and mole. × 4.

Matwejew and Sykow reported in the Gynecological Society of Moscow a case of tubal pregnancy in which the placenta had undergone cystic degeneration, and the ovary was likewise cystic. The patient was aged thirty-two years; she had had four normal labors and three abortions. The right tube contained the ovum, which ruptured about the eighth week of pregnancy. Symptoms of internal hemorrhage followed the rupture of the tube. Abdominal section revealed a large collection of blood in the pelvis, a ruptured tube, within which there was an hydatiform mole. The author stated that the cystic ovaries were undoubtedly the cause of the cystic degeneration of the placenta.

Microscopic Examination. **The Decidua Vera.** The glands do not differ essentially from those of normal pregnancy. In size, number, and general outline there is nothing unusual. The secreting epithelium of the glands is partially lost; the remaining cells are cubical or flattened. In the gland lumen are many desquamated and degenerated epithelial cells and not rarely free blood and leucocytes. The decidual cells present no anomalies in structure; as in normal pregnancy they present a variety of forms, the greater number being polygonal or spindle-shaped. In the compacta they are more uniformly spindle-shaped, with elongated nuclei. Free blood together with groups of leucocytes are found between the decidual cells and the musculature.

The Decidua Serotina. On the surface of the decidua serotina is a thin, fibrinous layer in which decidual cells are scattered. The

Fig. 64.

Cystic degeneration of a villus, with an islet of syncytium within the degenerated stroma.

decidual cells are round, polygonal, and spindle form, with large, round, granular nuclei. The glands are large, irregular in form, and the secreting epithelium flattened or cubical. Bloodvessels are intimately associated with the decidual cells, and free blood is found in the decidua and musculature.

Chorionic Villi. It is observed that the intensity of the stain is subject to great variation, particularly in the connective tissue stroma. The larger the villus the fainter is the stain; while in the largest villi the central portion of the stroma utterly fails to take a stain, thereby showing complete degeneration and loss of tissue. At the periphery of the villus, where the stroma is seldom if ever wholly lost, there is a faint stain, showing but partial degeneration. This is best shown by the Van Gieson stain. Great variations in

staining are also shown in the epithelial layer, the cells lying nearest the stroma taking the stain more faintly than those at the periphery. The non-degenerated connective tissue of the villus is of the embryonal type; the cells are elongated, having spindle-shaped nuclei. There is not the degree of development into fibrillæ as described by Webster in the chorion of the fourth month, but it resembles in point of development the villus of four to six weeks' development. The first evidence of degeneration in the connective tissue is shown in the indistinct outline of the cell body, which becomes a granular substance beset with stellate cells containing a granular nucleus, and from which radiate fine fibrillar processes. Finally the formed elements disappear, and there is left an irregular

Fig. 65.

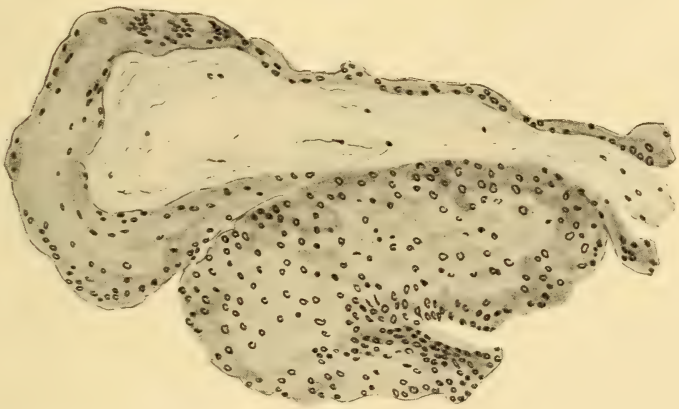

Beginning degeneration of the stroma, with unusual proliferation of the syncytium.

space filled with clear serous fluid. At the periphery, in close touch with Langhans' layer, there always remains more or less connective tissue, arranged in concentric layers, which is more fibrillar than that of the centre of the stroma. In none of the villi is the stroma wholly degenerated. The degeneration of the stroma is in direct proportion to the size of the villi; in the smaller villi there is little if any degeneration. The process seems to be a granular degeneration or necrosis, with subsequent absorption, leaving spaces which fill with serum. I have not been able to demonstrate mucoid degeneration, as was first affirmed by Virchow. Storch took issue with Virchow on this point, and, after him, the lesion is spoken of as "cystoid degeneration of Storch." Other authorities, while agreeing with Storch, disagree as to the manner by

which this "cystic degeneration" is brought about. Merkle and Giese call it a secondary œdema due to an inhibited formation of the placenta. Koster and Rumler believe it to be an œdema of the stroma resulting from interference with the circulation through the pedicle of the vesicle.

Krentzmann also takes issue with Virchow. He says: "Vesicular mole is the result of an irregular proliferation of the epithelial parts of the chorion, with hydropic swelling and consecutive necrosis, manifested especially in the larger vesicles. The superficial stratum of the stroma—that which is near the living epithelium—remains unchanged, but the inner parts become liquefied."

In addition to the above-named authorities may be mentioned Marchand, Fraenkel, and Neumann, who believe in the cystic degeneration theory as opposed to the myxomatous degeneration theory of Virchow. They speak of the proliferation of the epithelial elements as being coincident with the liquefaction of the stroma.

Bloodvessels in the villi are difficult to demonstrate. Webster in describing the chorion of the sixth week of development says: "Most of the villi have capillaries. These consist simply of a tube of small, flat, endothelial cells around which the connective tissue is somewhat condensed, though to a different extent in various places." No bloodvessels were seen in the large cystic villi; and when seen in the small, less degenerated villi they appear thicker-walled than is described by Webster (*vide supra*). No calcareous deposits were seen in the villi. The most significant changes centre in the epithelial elements of the chorion. There is seen an active and very irregular proliferation of the epithelial cells, with a tendency to invade the uterine structures to a degree not seen in normal pregnancy. Before degenerative changes are noted in the stroma the epithelial layers proliferate to an unusual degree. This proliferation of epithelium is particularly marked at the tips of the villi. The larger the villi the greater the proliferation. This proliferation, while similar in character, is to a greater degree than is found in normal pregnancy of the same age, and may surpass that found at any time of pregnancy.

In the syncytium and Langhans' layer of the small villi there is little change from the normal. As the villi enlarge through degenerative changes in the stroma and proliferation of the epithelial elements there are seen in the periphery of the villi, particularly

at the distal end, clumps and buds of protoplasmic bodies taking a deep stain and containing irregular groups of nuclei. Irregular vacuoles are seen in these protoplasmic bodies. The protoplasm is finely granular, and takes a fainter stain than do the nuclei. The buds and clumps of protoplasm take a deeper stain than do the remaining portions of the epithelium. Here and there in the larger villi irregular nests of syncytium are seen in the stroma of the villi. These, according to Van der Hoeven, are *prima facie* evidence of malignancy. A careful study of my specimens relative to this phase has led me to the conclusion that such is often, though not always, an accidental finding, due to tangential cutting of the villus, and not to an active invasion of the stroma by the epithelial elements. These changes in the syncytium and Langhans' layers are essentially hyperplasia and necrosis of the cell elements; the protoplasm increases in amount and the nuclei in size and number. The vacuoles are in number and size directly proportionate to the amount of epithelium, and are doubtless due to degenerative changes from malnutrition. Coagulation necrosis of the syncytium is more or less in evidence throughout the specimen. With the death of the fœtus there is loss of the fœtal blood supply to the villi. This does not necessarily result in necrosis of the villi, provided the maternal blood supply is sufficient to supply the needed nourishment; on the contrary, the villi may continue to grow.

According to Marchand, the fœtal blood is of minor importance in supplying nourishment to the villi. As evidence of this he has demonstrated necrosis of the stroma in the presence of a fœtal blood supply and in the absence of a syncytial covering. His conclusion is that the syncytium exercises a governing influence over the maternal blood supply to the stroma of the villi; when destroyed the stroma will undergo degenerative changes. Marchand asserts that a well-formed stroma is found only where the maternal circulation is adequate and the syncytium intact.

It is found that in partial moles where the maternal circulation is less disturbed the necrosis of the stroma is correspondingly less. It would appear, then, that the remote cause of the necrosis of the chorion lies in the failure on the part of the maternal circulation leading to degeneration of the connective tissue, and to a serous exudate which finally replaces the stroma of the villi. Peters believes the syncytium to be a sort of endothelial layer lining the intervillous spaces and exercising some important part in the func-

tion of interchange between maternal and fœtal circulation. Furthermore, that it serves to protect maternal blood from direct contact with Langhans' layer, which probably has some coagulating or destructive influence on the maternal blood.

With a disturbance of the maternal circulation the reciprocal relations between the maternal and fœtal circulation are altered, and, as a result, there is added to necrosis of the stroma a serous

FIG. 66.

Group of degenerated villi, showing proliferation of the syncytium.

exudate, with the formation of cystic spaces filled with clear serum. The accumulated fluid in turn causes further necrosis of the stroma through compression; complete degeneration of the connective tissue fibres is seldom if ever seen. There is always a limited amount of fibres compressed in a concentric manner immediately beneath the Langhans layer. In the larger villi there is also pressure necrosis of the epithelial covering, affecting both Langhans' layer and the syncytium.

Malignant Degeneration. The greatest interest in hydatiform moles centres in the fact of their liability to undergo malignant degeneration. Solowij and Krzysz-Kowski have shown that about 10 per cent. of hydatiform moles become malignant. On the other hand, it is generally recognized that fully 40 per cent. of the cases of syncytioma malignum arise from hydatiform mole. In collecting reported cases of hydatiform mole I have found a scarcity of case-reports of non-complicated hydatiform mole; that cases are seldom reported unless they have undergone malignant degeneration. For this reason it is impossible to arrive at any exact estimate of the frequency of hydatiform moles and of their malignant degeneration. Referring to the reported cases, which include all I am able to find in the literature, it appears that 16 per cent. of hydatiform moles become malignant. For the reason stated above it is probable that this percentage is far too high.

From the very onset the difficulties involved in dealing with the many mooted questions concerning the malignancy of hydatiform mole appear insurmountable. The intimate blending of fœtal and maternal structures, together with the secondary processes of degeneration, are so complicated and are so subject to variations that it is difficult and at times impossible to distinguish the benign from the malignant. Indeed, Van der Hoeven goes so far as to state that all hydatiform moles are malignant; that the proliferation of the epithelial elements of the chorion (syncytium, Langhans) assumes a malignant type in the invasion of the uterine musculature and connective tissue stroma of the villi. He further reasons that if this tendency on the part of the epithelial elements to proliferate is not marked, or if the mole is expelled or removed before the epithelium invades the uterine tissue beneath the line of cleavage (within the compact layer of the decidua), there can be no recurrence. If left behind in the uterine tissue, the epithelial elements continue to proliferate and to be carried to distant parts of the body by way of the blood stream, there forming metastatic malignant epithelial growths.

Neumann studied 8 cases of hydatiform mole; 5 were not followed by malignant changes, 3 died of syncytioma malignum. In the 5 so-called benign moles the epithelium of the chorion proliferated to an unusual degree, but did not invade the connective tissue of the stroma, while in the 3 malignant moles the connective tissue stroma was invaded by syncytial giant cells. Neumann

arrived at the conclusion that the earliest evidence of malignancy lay in the invasion of the connective tissue stroma of the villi by the epithelial elements of the chorion. As suggested by Pierce, the "view of Neumann is not generally recognized, and with right, for cases of nephritis and lead poisoning have since been described where the same cells were found in the stroma of normal villi; hence their presence can have no pathological significance in hydatiform mole."

It is evident from the observations of Veit, Webster, Pick, and others that the invasion of the deep structures of the uterus, and even of structures beyond the uterus, by chorionic epithelium, is not evidence *per se* of malignancy; that, on the contrary, syncytial masses are found in the uterine musculature, and are deported to distant parts of the body by veins in normal pregnancy; that soon after the termination of pregnancy they disappear. The transition between benign and malignant chorio-epithelial elements is a gradual and imperceptible one, just as is true in the transition of all benign hyperplastic growths into the malignant types; and to differentiate them is manifestly impossible. There undoubtedly exists an intermediate stage between the benign and malignant. Berry Hart examined an hydatiform mole in which the epithelial changes were identical with those described in the malignant type; no recurrence followed the expulsion of the mole. Both the syncytium and Langhans' cells participate in the proliferative changes, but to a varying degree. There is, likewise, great variation in the rate of growth in the epithelial elements, the explanation not only lying inherent within the cell elements, but also in the degree of resistance offered by the uterine tissue.

Two of the cases described by Kworostansky were in the second month of pregnancy—one a benign hydatiform mole, the other a syncytioma malignum. It is of the greatest interest to compare these two cases from an anatomical point of view. In the benign mole there was unusual proliferation of the syncytium and Langhans' layer, forming a loose connection with the decidua serotina; in the veins of the serotina both syncytial and Langhans' cells were found in limited numbers. The decidua vera was invaded to a lesser degree; no epithelial elements were found in the uterine musculature. In the placental site were evidences of endometritis, as demonstrated in scrapings removed six weeks after the expulsion of the mole. The case recovered without recurrence. The author

states that the patient, aged twenty-four years, was anæmic, and that this impoverishment of the blood afforded insufficient nourishment to the villi, thereby exciting the chorio-epithelium to extend deeper into the uterine musculature in order to obtain greater nourishment. Sufficient nourishment not being provided by the stroma of the villi, narcosis follows. In the second case, which was malignant, there was also extreme anæmia. The epithelial elements behaved similarly to that of the first case, only to an exaggerated degree, apparently differing only in the degree of epithelial invasion of uterine structures. The syncytial cells invaded the intermuscular spaces and veins of the uterus as far as

FIG. 67.

Distal end of a chorionic villi, showing beginning degeneration of the stroma.

the parametrium. Atrophy and necrosis of the decidual and muscular elements followed; bloodvessels were changed to blood lacunæ. In comparing my specimen of benign hydatiform mole with one having undergone malignant changes, it was advisable to select for comparison not only one of similar age, but also one that had been removed together with the uterus, as was mine. In this way we avoid certain retrogressive changes and the disturbance of anatomical relations which would otherwise mislead. Two such cases have been reported—one by Poten and Vassmer, the other by Neumann. In both these cases the essential variation from my own case appears to lie in the more marked proliferation of the syncytium and Langhans' cells and in their extended invasion of the uterine veins and musculature. While it is not to be expected that a benign mole may be recognized from a malignant mole by

the naked eye, yet it is worth while to observe that Pautz and others have found in malignant moles that the villi rarely attain large size, are firm, and have a long, slender pedicle, giving to the mole the appearance of soft-cooked rice.

Ladinski, in a recent clinical review of deciduoma malignum, reported a case of hydatiform mole followed by malignant degeneration. He collected thirty-three similar cases, and concluded that malignant degeneration occurred most frequently in cases where mole pregnancy terminated in the fourth month. It does not appear that the length of time a mole remains *in utero* has any influence upon its disposition to become malignant. In twenty cases Ladinski finds the average time of appearance of syncytioma malignum is eight weeks after the mole has been expelled.

Diagnosis. The rate of growth of the uterine tumor is the most constant and characteristic sign of hydatiform mole. With few exceptions, the size of the uterus is greater, even to double that of the normal pregnant uterus of a like period. At twelve weeks it has been found larger than the average pregnant uterus at full term. The growth is not usually symmetrical; in a number of cases the uterus is found to be proportionately broad. Furthermore, the rate of growth is not uniform. Near the time of expulsion the uterus frequently assumes a very rapid growth, soon to be followed by uterine pains and profuse hemorrhage. Within twenty-four hours the uterus may ascend two or three fingers' breadth.

Hemorrhage is usually the first symptom to attract the attention of the patient. Preceding the hemorrhage is a period of amenorrhœa extending over one, two, or three months—rarely longer. In a single case hemorrhage appeared in the third week of gestation, and again as late as the fifth month. The usual time of occurrence is in the second and third months. It is occasionally stated that the hemorrhage is more profuse at night. This was true in my first case, there being very little loss of blood during the day and profuse bleeding at night. As a rule, the hemorrhage is at first slight, gradually increasing in amount and frequency, finally becoming continuous and in such quantities as to cause more or less anæmia. Hemorrhage is always to be feared at the time of the expulsion of the mole; this is particularly true when the mole is far advanced and when firmly adherent to the uterus. It has been known to recur within a week in a case that did not prove to be malignant, but such an event is exceptional. Where malignant degeneration

has followed the birth of a mole hemorrhage is known to have recurred nine days after the mole was expelled, and as late as four and one-half years. Consulting the statistics, it is seen that hemorrhage, ushering in malignant changes, first appears in the first and second months, with about the same frequency as in the fifth and sixth months following the expulsion of the mole. *We may formulate the dictum that hemorrhage recurring weeks and months after the expulsion of an hydatiform mole is suggestive of malignancy, and demands immediate and thorough investigation into the cause.*

Nausea and vomiting are present in a larger percentage of cases than is common to pregnancy. Severe and uncontrollable vomiting occurred eighteen times in the 210 collected cases. The explanation probably lies in the unusual distention of the uterus.

Pain in the back and pelvis is complained of in nearly all cases, but does not usually develop until hemorrhage has persisted for some time. Not infrequently pain is absent until the hemorrhage is profuse and the cervix dilating.

In extensive degeneration of the chorion the fœtus dies early and is absorbed. We then have none of the physical evidences of a fœtus. In partial degeneration of the chorion the development of the child may not be hindered, and there may be no clinical evidences of vesicular degeneration.

The consistency of the uterus is a subject of some importance from a diagnostic point of view. Poten reported eleven cases of hydatiform mole, in three of which he observed irregular contractions of the uterine wall. These contractions were localized over a limited area, and were transient, lasting but a few minutes and reappearing at variable intervals. To the examining finger they might easily be mistaken for intramural fibroids. Poten does not claim this is a reliable sign, but suggests that further investigation of the phenomenon be made.

An early diagnosis of hydatiform mole is of importance because of the liability to malignant degeneration. While, as a rule, there will be the usual clinical signs of a mole some time before malignant changes develop, there is always the possibility of early malignant transformation, and it is not possible to detect these early malignant changes. Our only safeguard lies in the early recognition of the mole and in its immediate removal.

Will the microscope supply an infallible means of making an early diagnosis of malignant degeneration of a mole? We do not

accept the statement of Van der Hoeven and Neumann that epithelial invasion of the stroma of the villi is the earliest and at all times reliable evidence of malignancy. As has been stated, such findings are not uncommon in normal pregnancy. Marchand failed to find the stroma invaded in a malignant mole, and Ruge found such invasion in an undoubted benign mole. In my second case there was epithelial invasion of the stroma of the villi. Two years have elapsed since the removal of the mole, and no signs of malignancy have developed.

In a case reported by Poten the mole went on to the time of full-term pregnancy. Neumann's cells were found in the stroma of the villi. On the twenty-sixth day after the mole was expelled hemor-

Fig. 68.

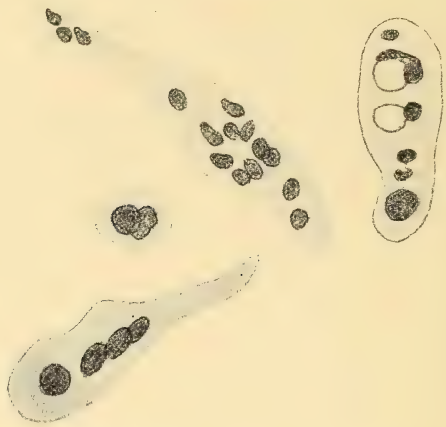

Giant syncytial cells showing vacuoles.

rhage recurred to a slight degree. The uterus was curetted, and a microscopic examination of the scrapings showed no evidence of malignant invasion; recovery followed. This case shows how difficult, and at times impossible, it is to determine the character of an hydatiform mole. In the light of our present knowledge we must always make a guarded diagnosis in the early stage; and at no time can a diagnosis be made with absolute certainty from the expelled mole. The invaded decidua, and if possible the underlying musculature, will alone afford evidences of malignant invasion prior to the development of metastasis. In the case reported by Schmidt a diagnosis of malignancy was first made from a microscopic examination of a metastatic growth which appeared in the

vagina. The uterus was not removed, and recovery followed the removal of the vaginal growth. When hemorrhage recurs days or weeks after complete removal of the mole the uterus should be curetted and the scrapings examined for active and extensive invasion of the uterine tissues. Large nuclei, rich in chromatin and mitotic figures, together with a tendency on the part of the protoplasm to separate into individual cells or chains of cells, is, according to Voigt and Gottschalk, suggestive of malignancy.

We are forced to the conclusion that as yet we have no certain means of making an absolute and early diagnosis of malignant degeneration of an hydatiform mole. The clinical signs, together with the gross and microscopic appearances, are all to be carefully considered. In view of our inability to make an absolute early diagnosis, vesicular degeneration of the chorion, however limited, demands immediate interference, to be followed by a period of at least three years of watchful expectancy; and if, at any time following the expulsion of the mole, hemorrhage recurs, the uterus is to be curetted and a microscopic examination made of the scrapings.

Regarding the prognosis of hydatiform mole, experience teaches us to look with suspicion upon all cases, even months and years after the removal of the mole. It is seldom that serious consequences occur while the mole is *in utero*. Malignant degeneration, rupture of the uterus, fatal hemorrhage—all these have occurred with the mole in situ, though such happenings are, fortunately, rare. We have learned to fear remote results—*i. e.*, a repetition in subsequent pregnancies and malignant degeneration of retained chorio-epithelium. Heitzman estimated the mortality at 13 per cent. These statistics were gathered at a time when chorio-epithelioma malignum was not recognized. It is generally accepted that 10 per cent. of hydatiform moles undergo malignant degeneration. This estimate is generally accepted as approximately expressing the death rate of hydatiform mole; but it is far too small, as shown by the following data. Deaths from hemorrhage and, to a lesser degree, from septic infection and rupture of the uterus add materially to the death rate, bringing the mortality to near 25 per cent.

In my 210 cases collected from the literature there were 49 deaths —a mortality of about 25 per cent. Of this number 32 died from syncytioma malignum (16 per cent.); 7 died from hemorrhage (4 per cent.); 4 died from septic peritonitis (2 per cent.); 1 died from

general sepsis; 1 from uræmia; 1 from endocarditis and nephritis; 1 from meningitis, and 2 from unknown causes. The author does not regard these statistics as expressing actual facts. There is doubtless a tendency to report all cases resulting fatally and to overlook those having no special point of interest in their course and termination.

The later in pregnancy we have to do with vesicular degeneration of the chorion the more grave the prognosis, because of the difficulty in removing the mole; the greater liability to rupture of the uterus and to malignant degeneration. It has been stated, and

Fig. 69.

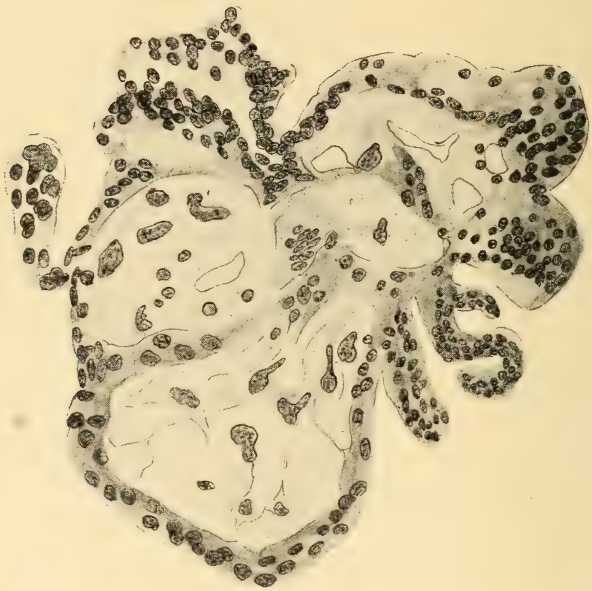

Showing syncytial invasion of the stroma.

will bear repetition, that the removal of an hydatiform mole is imperative as soon as the diagnosis is established. There can be no temporizing, however limited the vesicular degeneration and however early or late the condition is recognized. Where but a small area of the placenta is involved the diagnosis is not made until the termination of pregnancy; hence the question of interference will not arise during pregnancy, but the same degree of watchful expectancy must be exercised after the termination of pregnancy. While all agree as to the disposition that should be

made of the mole, it is always a grave question as to what should be our attitude toward the uterus after the mole is expelled. Solowiz has advised hysterectomy in all cases, and surely this would be the logical conclusion were we to agree with Van der Hoeven that all hydatiform moles are malignant.

Recognizing the frequency of malignant degeneration of hydatiform mole, and finding our most reliable and early evidences in malignant invasion of the decidua, we indorse the advice of Butz, who would curette the uterus ten or twelve days after the expulsion of the mole, for the purpose of removing remaining fœtal elements and of making a microscopic examination of the scrapings to detect a possible malignant invasion, as shown by active proliferation of the chorio-epithelium. Doubt will occasionally arise after such a procedure, and where such doubt exists the uterus should be removed on suspicion.

Respecting the influence of hydatiform mole upon future child-bearing, it is observed that healthy children are born subsequent to the expulsion of the mole, and that there does not appear to be acquired an added tendency to abortion. Contrary to the statement made by most text-books, it is the exception for a woman to give birth to more than one mole. In 210 recorded cases but two women gave birth to two moles, one to four (not recorded), one to five (not recorded), and one to eleven. It is furthermore seen that conception is possible very soon after the expulsion of the mole. On the other hand, a period of twenty years of sterility, and in two instances ten years, has preceded the development of the mole. It is correctly stated that multiparæ are more liable to hydatiform mole than primiparæ. In the 210 cases, 42 were primiparæ, 139 multiparæ, and 29 not recorded.

CHAPTER XIX.

THE DIAGNOSIS OF CHORIO-EPITHELIOMA MALIGNUM.

From the fact that the histogenesis of this new-growth has until recently been little understood, a number of names have been assigned to it. It was called deciduoma malignum, because it was believed to be a malignant proliferation of the decidua. Sarcoma-chorio-cellulare was a name suggested, on the theory that the essential cell structures were of mesoblastic origin. On the other hand, the name carcinoma syncytiale was proposed, because of the supposed epithelial character of the growth. The term chorio-epithelioma malignum more accurately expresses the true histogenesis of the growth, for it is now generally accepted that the growth is derived from the epithelial elements of the chorion and not from the decidua.

We are indebted to Sänger for our first knowledge of this tumor formation. In 1888 Sänger described such a case before the Obstetrical Society of Leipzig. He, however, believed the growth to be a malignant proliferation of the decidua, and classified it as a sarcoma.

L. Fränkel was first to demonstrate the origin of the growth in the epithelium of the chorion. He classified the tumor as a carcinoma.

The greatest and most important work on the subject is that of Marchand, to whom we are largely indebted for our present knowledge of the histogenesis and histology of chorio-epithelioma malignum. He it was who demonstrated that both the syncytium and Langhans' cells take part in the formation of the new-growth, and hence the fœtal origin of the tumor, though occupying maternal tissues.

Peters demonstrated the true genesis of the epithelial layers of the chorion, Langhans' layer and syncytium in his observations on an ovum five to six days old. He has demonstrated to the satisfaction of most observers that both the syncytium and Langhans' layers are derived from the ectoderm or trophoblasts, being histogenetically identical. Holding to this view of the histogenesis

of Langhans' layer and the syncytium, we are prepared to enter into a more intelligent discussion of the histology of the growth.

Etiology. Pregnancy either precedes or accompanies the development of chorio-epithelioma malignum, and is essential to its development. Hence it is that the lesion is only found in women, and that, too, during the period of sexual maturity. In my analysis of 210 cases of hydatiform mole, I find that 16 per cent. became malignant. It is stated that about 42 per cent. of chorio-epithelioma malignum cases follow the expulsion of an hydatiform mole, 32 per cent. follow upon abortions, and 26 per cent. follow upon full-term labor. The time an hydatiform mole remains *in utero* has no influence upon the development of a malignant growth; there is the same liability to malignant transformation in the early as in the later moles.

In 124 cases collected by Ladinski the average age of the patient was thirty-two years—the extreme ages seventeen and fifty-five years. In 90 cases collected by the same author the average number of children born was 4.2; hence multiparity has no influence upon the development of the growth. The time of the development of the growth in relation to the expulsion of an hydatid mole, an abortion, or a full-term labor is two weeks to four and a half years.

Diagnosis. There is always a history of pregnancy and the expulsion of an hydatiform mole, an undeveloped fœtus, or a full-term fœtus, weeks, months, and even years before the appearance of a malignant growth.

The earliest symptom is *hemorrhage.* The loss of blood increases in amount and frequency, and very early causes profound anæmia. The usual means employed to check hemorrhage fail utterly, and may increase the flow. In curettage, the procedure must sometimes be abandoned because of the alarming hemorrhage. A *dirty, watery discharge* occurs, together with and in the intervals between hemorrhages. Later this discharge assumes a foul odor.

Pain is not a notable symptom. When present it is usually referred to the thighs and sacral region.

Cachexia is an early development following closely upon the anæmia. Loss of weight and strength are extreme.

Symptoms referable to metastasis are early present—so early as to almost characterize the disease. In order of frequency metastatic growths are found in the lungs, vagina, liver, spleen, kidneys, ovaries, intestines, brain, broad ligament, pleura, lymphatic glands,

pancreas, heart, stomach, and lymph glands of the pelvis. It is unusual for the metastatic growths to spread by way of the lymph glands, as is common with carcinoma. The cellular elements are, as a rule, conveyed by the blood stream, and in this respect behave like a sarcoma.

Fever of a low grade is commonly present, and may reach 104° F. The *pulse* is correspondingly rapid and feeble.

The above clinical signs are very significant, but not alone sufficient. The macroscopic and microscopic features of the growth must be considered before a diagnosis can be made with certainty.

The macroscopic appearances of the growth are not characteristic. The uterus is almost always enlarged, and is commonly described as soft. In advanced cases there may be irregularities on the outer surface as well as on the inner. The cervix is usually patulous to the index finger, and in the cavity of the uterus may be felt a soft, brain-like mass, friable, and bleeding profusely when handled. To the naked eye this soft mass resembles at times placental tissue, and at other times a vascular sarcoma. The color of the growth is mottled red, varying from a bright to a dark shade. Necrosis early develops. The primary growth is not always confined to the uterus. Cases have been recorded where the uterus remained free and a chorio-epithelioma malignum developed in the vagina and lung.

The *microscope* is indispensable in determining the true character of the growth. Under the microscope we recognize a rapidly proliferating structure composed of syncytium and Langhans' cells, which invade the uterine tissue in a most atypical manner and early extend to distant portions of the body by way of the blood stream.

After the expulsion of an hydatid mole the uterus should be explored by the finger to detect and remove any retained placental tissue. Two weeks later the uterus should be curetted and the scrapings examined microscopically. If in the decidua Langhans' cells and the syncytium are found to be proliferating, the uterus should be removed without delay. In every abortion or full-time labor when an unaccountable hemorrhage follows weeks and months afterward, an exploratory curettage should be done, in view of the possible finding of malignant placental tissue.

The microscopic picture is that of strands of protoplasmic masses, with nuclei and vacuoles forming a reticular structure. Polynuclear giant cells of syncytium are found in the network.

CHAPTER XX.

THE DIAGNOSIS OF MALFORMATIONS OF THE UTERUS.

As stated by E. C. Dudley, the developmental defects of the uterus form a large proportion of the genital malformations. They are arranged under two general headings:

1. Those due to imperfect development of Müller's ducts.
2. Those due to imperfect blending of the same.

UTERUS DEFICIENS.

It is very unusual to find in an adult a complete absence of the uterus. When found there is usually also an absence of the entire genital tract, or only a rudimentary development of the vulva, vagina, tubes, and ovaries. The round ligaments may be present, though poorly developed. If the ovaries are present the menstrual molimina will be experienced, and vicarious menstruation has been observed. There may or may not be sexual desire.

The differential diagnosis between a complete absence of the uterus and a rudimentary uterus is scarcely possible without making an exploratory incision. Placing a sound within the bladder and directing an assistant to hold it while proceeding with a recto-abdominal examination will demonstrate either an entire absence or a rudimentary development of the uterus.

UTERUS RUDIMENTARIUS.

As the name implies, the uterus is rudimentary in its development. It remains as a fibromuscular body, ill-formed and undersized. The walls may be so thin as to suggest the name *uterus membranaceous*. The cervix, adnexæ, ligaments, and vagina are likewise rudimentary or absent. The external genitals may be well-formed, though this is not probable. As stated in the above paragraph, a diagnosis cannot be made from complete absence of the uterus unless by abdominal section.

UTERUS FŒTALIS (Infantile Uterus).

The uterus and adnexæ fail to develop beyond that of fœtal life or early infancy—they are undersized. Aside from the size, the most striking feature of the fœtal or infant uterus is the disproportion between the cervix and body of the uterus. The cervix is

FIG. 70.

Normal position of the uterus. The uterus lies anteposed, anteverted, and slightly anteflexed when the bladder and rectum are empty and the patient in the upright position.

two-thirds the length of the whole organ, the body one-third. In the mature uterus the cervix is one-third the length of the whole organ, the body two-thirds. Again, the arbor vitæ in the fœtal or infantile uterus extends the entire length of the uterine cavity, while in the adult uterus the mucosa of the body is smooth and the arbor vitæ extends only the length of the cervix. Still another feature of the fœtal or infantile uterus is the absence of a fundus; the top of the uterus is either flat or depressed, while in the adult uterus it is convex.

FIG. 71.

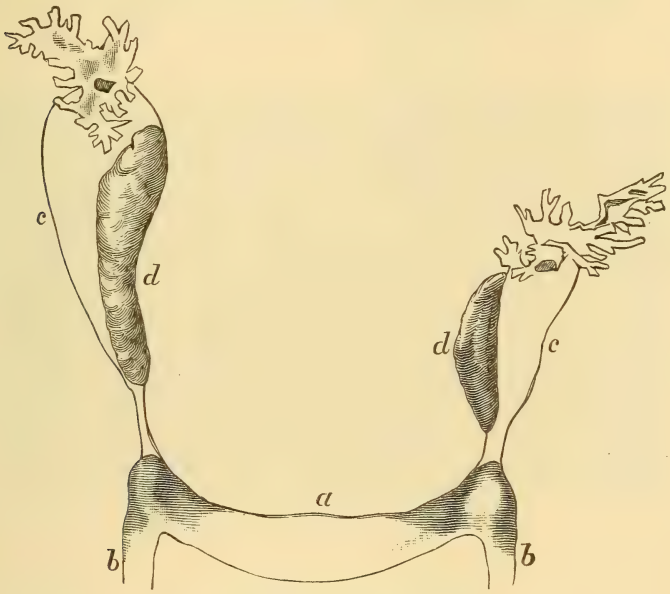

a. Ribbon-shaped rudiment of the uterus. *b, b.* Round ligaments. *c, c.* Fallopian tubes. *d, d.* Ovaries. (MANN.)

The vagina is usually shorter and narrower than is normal, but may be well-formed. The vulva may be poorly developed and the breasts likewise.

A general hypoplasia of the whole cardio-vascular system is said to be an underlying factor in this developmental failure. Chlorosis, scrofula, and the general wasting diseases are given as general predisposing causes. Cretins and dwarfs commonly possess fœtal or infantile uteri. Not infrequently there is perfect general physical development. It is probable that the developmental failure lies primarily in the ovaries.

The clinical diagnosis is not difficult. Primary amenorrhœa should always suggest the probable existence of an infantile uterus. Sterility is invariably present. If the patient has menstruated normally, or if she has ever been pregnant, there is no possibility of an infantile or fœtal uterus. A small vagina and vaginal portion of the cervix suggest a small uterus. A recto-abdominal examination under anæsthesia is preferred. When the uterine canal will admit a sound the measurement of the length of the uterus may be made, and an estimate of the thickness of the wall can be arrived at by a conjoined recto-abdominal examination, the sound remaining in the uterus.

Fig. 72.

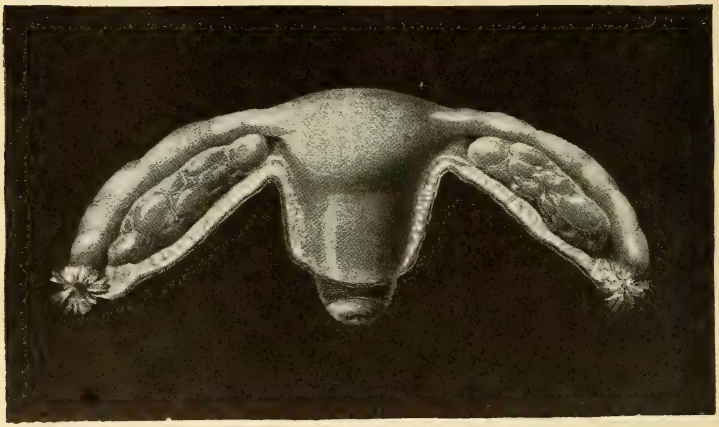

Uterus, Fallopian tubes, and ovaries of an infant one month old. Natural size. (Dudley.)

UTERUS UNICORNIS.

But a single horn of the uterus is developed; the opposite horn is either absent or rudimentary.

The explanation of this defect lies either in a partial or complete failure of one Müllerian duct to develop. The single horn tapers off into the tube. At the juncture of the horn and the tube the round ligament is given off. There is no fundus. The vagina and cervix are small, and may be divided partially or completely by a septum. The ovaries and tubes may be rudimentary or absent; so, also, the bladder and kidney may be undeveloped, or there may be absence of the kidney on the side opposite the single horn.

Sterility is the rule, though pregnancy in a rudimentary horn is

possible. Amenorrhœa is common, but the menstrual functions may proceed regularly. Where pregnancy exists in a rudimentary horn

FIG. 73.

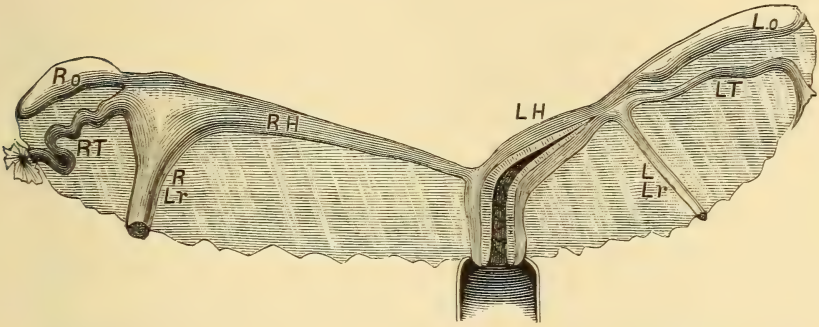

Uterus unicornis. *LH.* Left horn. *LT* Left tube. *Lo.* Left ovary. *RH.* Right horn. *RT.* Right tube. *Ro.* Right ovary. *RLr.* Right round ligament. *LLr.* Left round ligament. (MANN.)

FIG. 74.

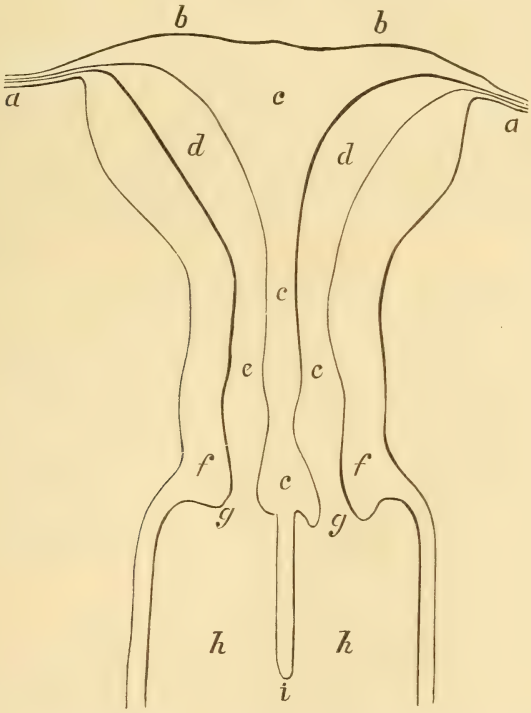

Uterus septus duplex (natural size), completely double uterus, and incompletely double vagina of a girl, twenty-two years of age. *a, a.* Tubes. *b, b.* Fundus of the double uterus. *c, c, c.* Partition of uterus. *d, d.* Cavities of the uterine bodies. *e, e* Internal orifices. *f, f.* External walls of the two necks. *g, g.* External orifices. *h, h.* Vaginal canals. *i.* Partition which divided the upper third of the vagina into two halves. (MANN.)

we have to deal with a condition not unlike tubal pregnancy in its clinical aspect. The dangers of rupture and of hemorrhage are the same. There is no way of making a distinction between these two conditions save by abdominal section, unless, as is possible in exceptional cases, the gestation sac is demonstrated by abdominal palpation to lie within the attachment of the round ligament. In tubal pregnancy the gestation sac lies external to the attachment of the round ligament.

UTERUS SEPTUS (Bilocularis).

The uterus is divided by a vertical septum extending a variable distance from the external os to the fundus. On the exterior there is no evidence of a septum.

The uterus is broader and more globular than is the perfectly developed organ. Not infrequently the vagina is septate. Various explanatory terms have been applied to the several degrees of the septate uterus—*i. e.*, *uterus biforis supra simplex*, where the septum is only found near the external os; *uterus subseptus unicorporens*, where the septum is found in only a part of the cervix and body; *uterus subseptus unicellis*, where the septum is found in the body, not in the cervix; and *uterus subseptus uniforis*, where the septum completely divides the body and cervix, there being a single external os.

UTERUS BICORNIS.

The two horns of the uterus are united to a limited and variable degree, the union taking place from below upward. The degree of separation varies from completely divided bodies with a single cervix to a union of the two horns, leaving but a notch in the fundus. The two horns are not always of equal size, and may not lie on the same plane. A septum may partially or completely divide the cervix and vagina. One or both horns may be imperforate. The external genitals are usually normal.

In addition to the anomalies in the development of the genital organs there may be maldevelopments of the urinary tract—*e. g.*, ectopia vesicæ, absence of or congenital atrophy of the kidney.

The behavior of the uterus bicornis is similar to that of the uterus septus. Menstrual disorders are common. Amenorrhœa may result from atresia of the lower genital tract, or from an

imperforate lumen in both horns of the uterus. The menses may flow simultaneously from the two horns or alternately at intervals of from two to four weeks. When one horn or one-half of a septate uterus is pregnant the opposite side may continue to menstruate or may become pregnant at any time during the period of gestation in the other side. A decidua may form in the non-gravid side and be discharged at labor. Pregnancy and labor may progress normally, and uterine contractions occur in both horns. This, however, is not the rule. The uterine contractions are seldom regular and strong; malpositions and malpresentations of the child are common; placenta prævia and premature detachment of the placenta may occur at any time, and rupture of the uterus during labor is always to be feared.

The presence of a uterus bicornis or uterus septus is often not suspected, even after marriage and childbirth. A double vagina or a double cervix will suggest the presence of a septate or bicornate uterus. When pregnancy does not exist the finger or sound will aid in the diagnosis. Under anæsthesia the separate horn may be detected by bimanual examination. Involution is rarely so perfect in the puerperium as in the normal uterus, and there are likely to follow displacements and subinvolution with all their remote consequences. Placental tissue is liable to be retained in the uterus and lead to infection and hemorrhage.

UTERUS DIDELPHYS (Uterus Duplex, Uterus Separatus).

Not only the uterine horns but the cervix as well is completely divided. Each half is equipped with a single tube, ovary, and round ligament. The vagina may be single, double, or partially divided. The two halves may be in different planes and of unequal size. One or both sides may be imperforate. All that has been said of the clinical features of a bicornate uterus will apply to a uterus didelphys.

UTERUS ACCESSORIUS.

This is the rarest of anomalies in the development of the uterus. Hollander and Skene each observed a case in which a small uterus was situated in front of a normal uterus, the two bodies joining at the internal os. The accessory uterus had no adnexa and no round ligaments. The explanation of this anomaly is probably

that a diverticulum of Müller's duct developed into an accessory uterus. Hollander's case gave birth to seven children. In an abdominal section placental tissue was found in the accessory uterus. Skene's case suffered from a leucorrhœal discharge from the accessory organ.

FIG. 75.

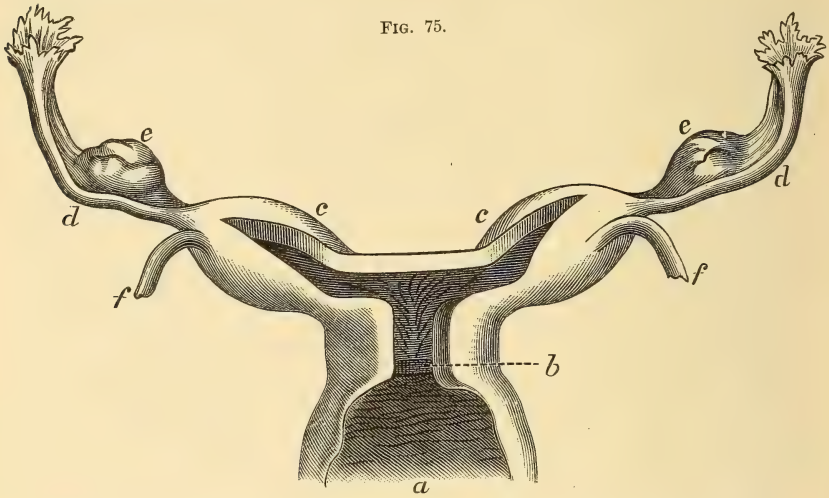

Uterus bicornis unicellis. *a*. Vagina laid open. *b*. Single cervix. *c, c*. Uterine horns. *f, f*. Round ligaments. *d, d*. Fallopian tubes. *e, e*. Ovaries. (MANN.)

FIG. 76.

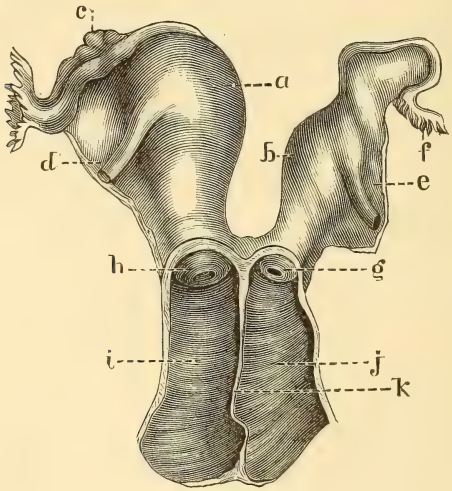

Double uterus, uterus didelphys. *a*. Right cavity. *b*. Left cavity. *c*. Right ovary. *d*. Right round ligament. *e*. Left round ligament. *f*. Left tube. *g*. Left vaginal portion. *h*. Right vaginal portion. *i*. Right vagina. *j*. Left vagina. *k*. Partition between the two vaginæ. (MANN.)

CHAPTER XXI.

THE DIAGNOSIS OF MALPOSITIONS OF THE UTERUS AND ITS NEIGHBORING ORGANS.

UNDER perfectly physiological conditions the uterus may occupy widely varying positions. In order that these physiological changes in position may occur, the uterine ligaments, pelvic peritoneum, and cellular tissue must possess their normal degree of elasticity. The normal position of the uterus varies with the attitude of the individual. It is crowded backward by a full bladder, forward by a loaded rectum, and forward and downward by increase in the intra-abdominal pressure from coughing, straining at stool, etc. By reference to Plate XX., fig. 2, it will be seen that the normal position of the uterus of a virgin in the erect posture, with the bladder and rectum empty, is one of anteversion, slight anteflexion, anteposition, and slight lateral position. The body of the uterus lies about 1 cm. behind the upper border of the symphysis pubis, the cervix points to the second sacral vertebra, and lies about 2 cm. in front of the sacrococcygeal articulation. In the virgin there is less anteflexion than in the multipara. The explanation lies in the fact that the small resisting vagina presses the slender cervix backward.

Pathological changes in the position of the uterus and its neighboring organs are more or less permanent. There is no tendency toward a spontaneous return to the normal position.

Pathological Mobility of the Uterus. The uterus becomes abnormally movable when the normal supports are weakened or have given way. A relaxation of the uterine ligaments, of the pelvic floor, and of the abdominal muscles will lead to abnormal mobility of the uterus. Under such conditions the uterus gravitates according to the position of the patient. In the upright position, with the bladder empty, it may fall forward and downward. In the dorsal position with the rectum empty the uterus falls backward into the hollow of the sacrum.

Pathological Fixation of the Uterus. An abnormally movable uterus may lodge in a position where it becomes fixed and immov-

able. It is thereby evident that the factors causing increased mobility of the organ may lead to a more or less permanent fixation. Fixation of the misplaced uterus will be considered in subsequent chapters. We will here discuss only fixation of the normally

FIG. 77.

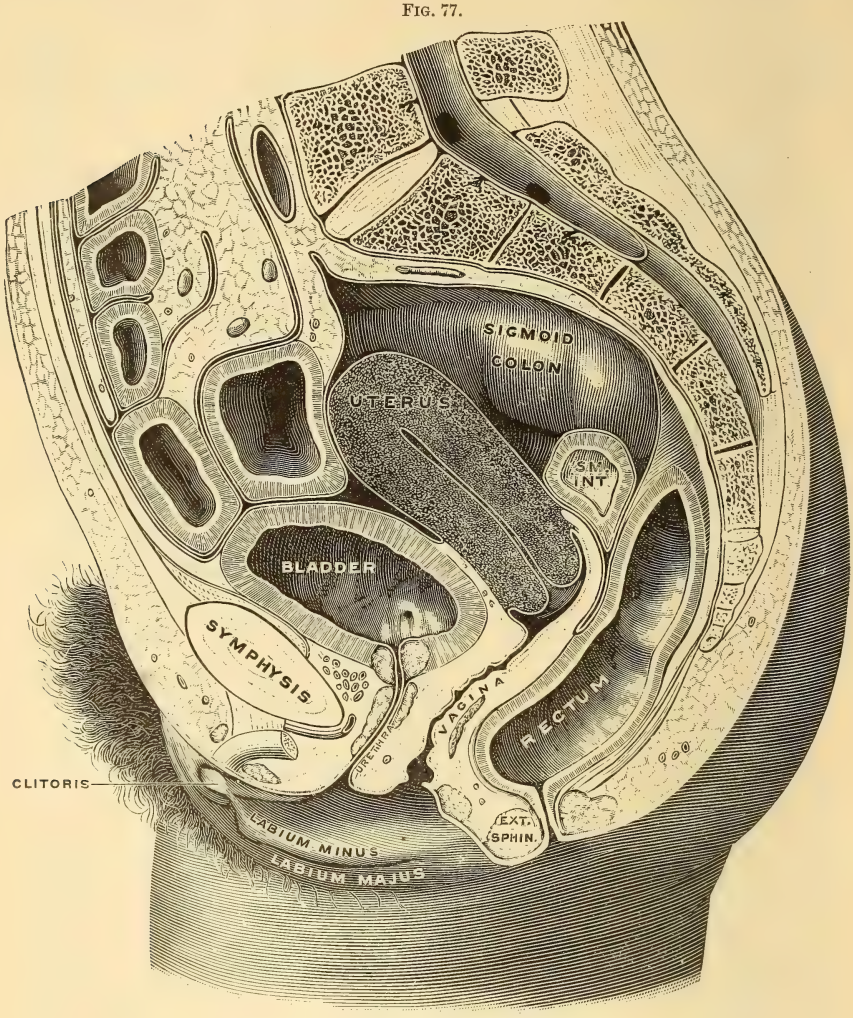

Sagittal section of the female pelvis. (TESTUT.)

placed uterus. By this we mean a uterus in normal position but lacking the degree of elasticity and mobility that is found in health.

Parametritis atrophicans (Freund) or parametritis posterior (Shultze) is a condition frequently overlooked. The uterosacral

PLATE XX.

Fig. 1.

Anteposition of the uterus. A retro-uterine hæmatocele fills the cul-de-sac of Douglas and the space between the uterus and sacrum. The uterus is crowded forward.

Fig. 2.

Anteposition. The loaded rectum crowds the uterus forward into anteposition when the bladder is empty. The cul-de-sac of Douglas is almost obliterated. When the rectum is empty the uterus will fall back into the normal position.

ligaments are firmly contracted and tender to pressure. By thickening and contraction of the uterosacral ligaments the cervix is drawn backward and the whole uterus restricted in its movements. A chronic metritis will diminish the normal flexibility of the uterus, as will also carcinoma and fibroids. Chronic cervical catarrh may stiffen the cervix.

ANTEPOSITION.

Anteposition is an exaggeration of the normal position. The uterus lies immediately behind the abdominal wall and symphysis pubis. Among the causes of anteposition of the uterus we have swellings behind, crowding the uterus forward, or adhesions attached to the anterior surface of the uterus pulling it forward. The latter condition is very unusual. The most common causes are tubal and ovarian swellings lying in the cul-de-sac of Douglas, retro-uterine hæmatocele, tumors of the uterus bulging from the posterior surface of the uterus, and new-growths of the rectum. Anteposition is often combined with elevation, anteversion, and anteflexion.

The diagnosis is seldom difficult. On bimanual examination the uterus is found lying close to the anterior abdominal wall. When caused by a retro-uterine swelling which cannot be outlined apart from the uterus the sound will be required to locate the position of the organ. A retro-uterine tumor crowding the uterus forward is recognized by its irregular outline and its consistency. Here, again, the uterine sound will be of service in locating the uterus. In every doubtful case an anæsthetic should be administered. The one symptom commonly present is frequent urination. (See Plate XX.)

In retroposition the uterus lies back of the normal position without change in the direction of its long axis.

RETROPOSITION.

As causes of retroposition we find either a swelling in front of the uterus or adhesions behind it. Among swellings in front of the uterus we find uterine fibroids, tumors of the bladder and anterior abdominal wall, and, occasionally, distended tubes and ovaries. Adhesions behind the uterus causing retroposition are largely confined to the peritoneal cavity, and involve the greater portion of the posterior surface of the uterus. These adhesions most frequently

result from extension of an inflammation from the tubes, which, when inflamed, commonly lie behind the uterus. In abnormal mobility of the uterus due to a relaxation of the normal supports the uterus falls into retroposition when the patient lies upon her back. (See Plate XXI.)

It is most important to recognize the cause of the displacement, inasmuch as retroposition *per se* is of little clinical significance. When no tumor mass or adhesions are found in the pelvis and the retroposed uterus displays an abnormal mobility the displacement is regarded as due to relaxation of the uterine supports.

It is not always possible to diagnose the presence of adhesions, even when the examination is made under anæsthesia. All operators of experience will testify to the frequency with which perimetritic adhesions are unexpectedly found after opening the abdominal cavity.

Perimetritic adhesions are confined to surfaces normally covered with peritoneum. They are found with greatest frequency about inflamed tubes and ovaries, and are therefore most commonly located beside or behind the uterus. The uterus is rarely absolutely fixed. The degree of mobility depends upon the location of the adhesions, their extent, length, and firmness. Adhesions binding the uterus to movable structures, such as bowel and omentum, usually permit more or less mobility on the part of the uterus. The diagnosis of a perimetritic exudate—that is, of an exudate lying within the peritoneal cavity and binding together the peritoneal surface of the uterus with the peritoneal surface of the adjacent structures from an exudate involving the pelvic cellular tissue—is made first of all by the location. A parametritic exudate lies low in the pelvis in close proximity to the vaginal wall, while a perimetritic exudate lies on a higher plane and is more difficult to palpate through the vagina. Furthermore, in parametritis the adhesive bands are firmer and larger than in perimetritis. The uterine sound may be of service in locating the position of the uterus apart from inflammatory exudates and new formations.

LATEROPOSITION.

Lateroposition is generally combined with retroposition, less often with anteposition and descensus. A limited lateral displacement of the uterus may be regarded as normal, and is explained by a short-

PLATE XXI.

Fig. 1.

Retroposition of the uterus. The distended bladder crowds the uterus backward into retroversion and retroposition. When the bladder is empty the uterus will fall forward into anteversion and anteposition.

Fig. 2.

Retroposition of the uterus. Peritoneal adhesions bind the posterior surface of the uterus to the sacrum and rectum, holding the uterus firmly in retroversion and retroposition.

ening of the broad ligament on the side to which the uterus leans. This congenital unilateral shortening of the broad ligament and also

FIG. 78.

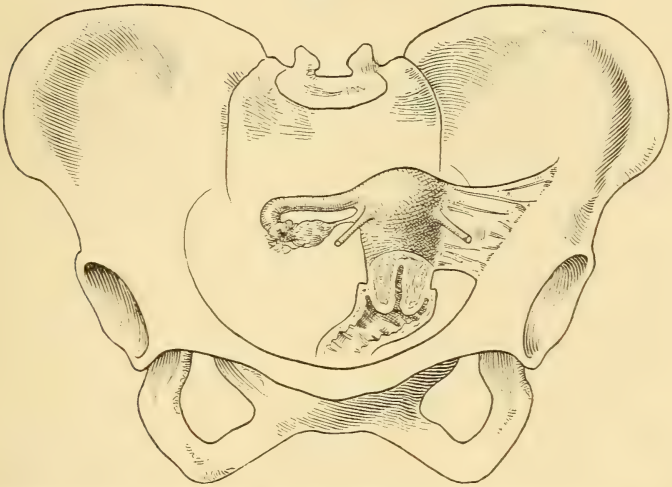

Left laterodisplacement of the uterus. The left broad ligament is thickened and contracted and has drawn the uterus to the left.

FIG. 79.

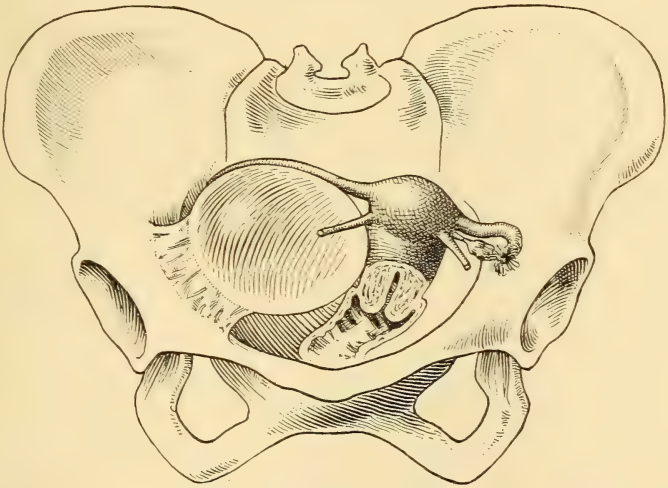

Left lateroversion of the uterus. The uterus is crowded to the left side of the pelvis, the long axis of the uterus inclines to the left. The cause of the displacement is a broad ligament cyst of the right side adherent to the wall of the pelvis.

of the uterosacral ligament accounts for the lateral displacement of the uterus not infrequently found in virgins.

The usual causes of lateral displacements of the uterus are inflammatory exudates and new formations; more rarely cicatricial contractions of the vaginal wall following lacerations and sloughs. Exudates at the sides of the uterus, when large, will crowd the organ to the opposite side of the pelvis. Later, as the exudate organizes and contracts, the uterus is drawn to the side occupied by the exudate (Fig. 78). If the exudate exerts its influence along the entire side of the uterus, as in Fig. 79, the uterus as a whole will be first pushed to the opposite side and later drawn to the same side. If the exudate involves the lower segment of the broad ligament, leaving the body of the uterus free and movable, the cervix will be drawn toward the side in which the exudate has collected and the body of the uterus tilted to the opposite side —a lateroversion or lateroflexion. Likewise, in case of tumor formations lying beside the uterus, if the force is distributed along the side of the uterus there will be a simple lateroposition; if pressure is exerted upon the fundus alone, there will be a lateroversion or flexion in which the body will be crowded to the opposite side, the cervix pointing to the side occupied by the tumor (Fig. 79).

Slight lateral displacements of the uterus are commonly overlooked. When found they should always lead to a careful bimanual examination, and, if necessary, under anæsthesia, in view of determining the cause of the lateral position. Reference to Figs. 78 and 79 will suggest in a general way the mechanism of the displacement. In a word, the displacement is due to traction on the one side or to crowding on the other.

ELEVATIO-UTERI.

In elevatio-uteri the uterus is raised above the normal plane and approaches the anterior abdominal wall. In uncomplicated elevatio-uteri the long axis of the uterus is straightened. As a matter of fact, it is unusual to find an uncomplicated elevation of the uterus, such a condition being, as a rule, associated with lateral, anterior, or posterior displacements. The position is physiological in pregnancy. The extent to which the uterus may be drawn upward is astonishing. A perfectly normal uterus may be raised to the level of the umbilicus.

Causes of elevation of the uterus may be classified under two general heads, namely, swellings below the uterus crowding it

PLATE XXII.

Fig. 1.

Retroposition of the uterus. The uterus is drawn backward into retroposition by peritoneal bands of adhesions extending from the supravaginal portion of the cervix to the sacrum.

Fig. 2.

Elevatio-uteri following a ventrosuspension of the uterus. Adhesions unite the fundus of the uterus to the abdominal wall and retain the uterus in an elevated position.

upward, or tumors and adhesions making upward traction upon the uterus.

Swellings beneath the uterus and crowding the uterus upward are tumors of the cervix, vagina, rectum, and hæmatocele. Adhesions binding the fundus to the abdominal wall may develop during pregnancy and the puerperium, leaving the uterus in elevation after the puerperium Fig. 78 represents the uterus suspended from the abdominal wall in an elevated position. A Cæsarean section had been performed, and subsequently adhesions developed between the scar in the abdomen and that of the uterus.

Fig. 135 represents a subperitoneal fibroid attached to the fundus and growing into the abdominal cavity. In this case either the pedicle must elongate or the uterus will be drawn upward, since the tumor, when it can no longer be accommodated in the pelvis, rises into the abdominal cavity.

Tumors of the ovary with short pedicles may operate similarly to the fibroid in Fig. 80. The vagina will be found greatly elongated and the cervix may not be within reach of the examining finger.

TORSION OF THE UTERUS.

In torsion of the uterus the organ is twisted upon its long axis. This displacement rarely exists singly, but is generally associated with anteposition, lateral position, or elevation. Within perfectly normal limits the uterus is slightly turned upon its long axis, due to a shortening of the broad ligament, which runs outward and slightly backward.

Causes of torsion may be traction on the one hand or pressure on the other. Adhesions running from the side of the uterus backward or forward may turn the uterus upon its long axis, as will also pressure made upon the side of the uterus by tumor formations.

Fig. 79 represents a pedunculated ovarian tumor lying in the abdominal cavity. The tumor has been turned upon its long axis, and with it the uterus has become twisted. It is even possible for the uterus to be severed by the twisting. The blood supply to the uterus may be shut off completely and cause gangrene, or partially and result in atrophy. Menstrual and intermenstrual secretions may be pent up in the uterus above the point of torsion.

As a rule, the displacement is not discovered until an exploratory incision is made to remove the cause.

Fig. 80.

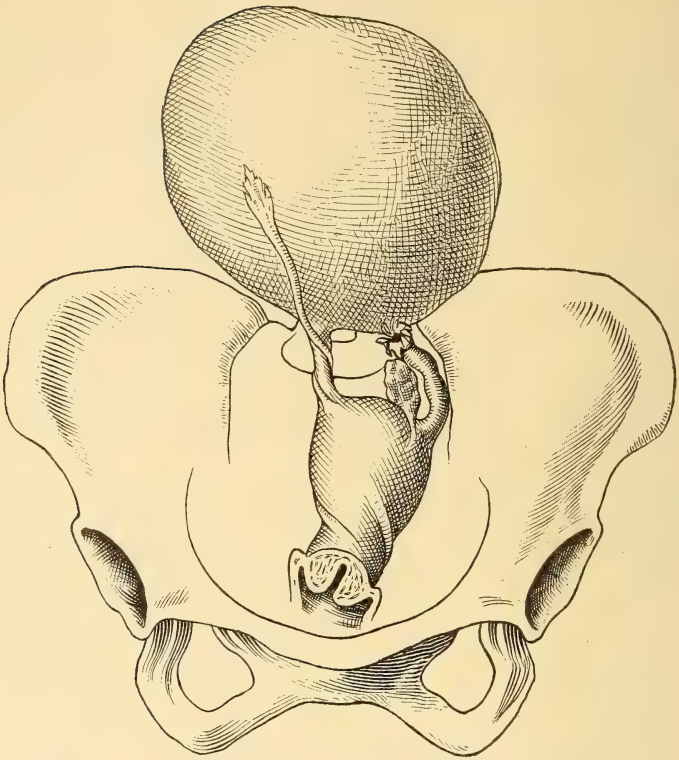

Torsion of the uterus caused by twisting of the pedicle of an ovarian cyst.

PROLAPSUS UTERI.

As suggested by Berry Hart, prolapsus uteri should be considered under the head of displacement of the pelvic floor. The displacement should be regarded as a hernia of the uterus, adnexa, bladder, rectum, and vagina. While the author is in accord with this view, it is thought best to consider the subject along with other displacements of the uterus, as is the custom with most text-books. Webster, in his text-book on *Diseases of Women*, holds that prolapsus of the uterus, vagina, urethra, and bladder is the result of failure on the part of the fascial and other tissues supporting these organs between the bony walls of the pelvis to resist intra-abdominal pressure and gravity. If the power of resistance is weakened, or the intra-abdominal pressure and weight of the uterus are increased, or if both factors co-operate, prolapsus will occur. Webster takes exception to the view of Hart, who regards the perineum as a fixed

segment for the support of the uterus, and of Thomas, who holds that the perineum is a supporting wedge. By anatomical dissections Webster has demonstrated that the pelvic fascia and not the perineum and levator ani muscle is the real support.

The various fascial tissues which meet in the perineum and give support to the pelvic viscera are: 1. The anterior and posterior triangular ligaments. 2. The visceral layer of the rectovaginal fascia. 3. The anal fascia. 4. The deep superficial fascia. Webster holds that the perineal muscles are of little value as a support compared to the pelvic fascia.

In the absence of actual rupture of the fascia it is possible for stretching alone to so weaken the support that prolapsus will occur.

Prolapsus uteri is a term implying not only a descent of the uterus, but also involvement of the bladder, rectum, vagina, and adnexa. Descent of the uterus may be checked at any point between the normal position and extreme prolapse.

Nomenclature. With Webster, the author will speak of (1) *descensus uteri*, when the uterus and vaginal walls do not descend beyond the vulvar outlet, and (2) *prolapsus uteri*, when the uterus and vagina descend beyond the vulvar outlet.

The posture of the patient most favorable to recognition of a downward displacement of the uterus is the erect (Fig. 7). In the recumbent position the uterus may resume in part or wholly the normal position. The erect position is awkward and embarrassing, and for these reasons is seldom used. With the patient in the lithotomy position, the uterus may be manipulated in such a manner as to effectively demonstrate the degree of descensus. Bimanual manipulation, and, if necessary, traction upon the cervix with a vulsella forceps, will bring the uterus down to its maximum degree. Under normal conditions it is not possible to draw the vaginal portion of the cervix beyond the vulvar outlet.

Anatomical Diagnosis. The diagnosis is almost wholly based upon the anatomical findings. It is at times possible to make a diagnosis from inspection alone.

Inspection of the vulva may disclose the uterus and vaginal walls protruding from the vulvar outlet. In nearly all such cases the perineum is lacerated, and there may be a prolapsus of the mucous membranes of the urethra and rectum.

Displacement of the Vagina. Inasmuch as the uterus is seldom displaced downward without a primary or secondary involvement

of the vagina, we will first consider descensus and prolapsus of the vagina.

1. **Descensus vaginæ** implies a downward displacement of the vagina to a point short of the vulvar outlet. Preceding the descent of the vaginal walls there is usually a relaxation or laceration of the pelvic floor. As a rule, the anterior wall of the vagina is first to descend; then follows the uterus as it is pulled upon by the sagging wall of the vagina, and, finally, the uterus in turn carries with it the posterior wall of the vagina. It is unusual for the anterior and posterior walls of the vagina to descend simultaneously and equally. Yet more unusual is the primary descent of the posterior vaginal wall. A limited degree of descensus vaginæ may exist without displacing the uterus. The descent occurs from below upward; seldom from above downward.

2. **Prolapsus vaginæ** implies a protrusion of the vaginal walls beyond the vulvar outlet, and is always associated with downward displacement of the uterus. In primary descent and prolapse of the uterus the vaginal walls are inverted from above downward, there being no pouching of the vaginal walls as in secondary prolapse of the uterus. The lower segment of the vaginal wall may prolapse, the upper segment invert, and the intervening one remain unchanged. The prolapsed anterior vaginal wall pouches into the vagina, dragging the bladder with it, and forming what is known as a cystocele. The bladder is so intimately attached to the anterior wall of the vagina it is quite impossible for the vagina to descend without carrying the bladder with it. The vaginal wall loses its usual elasticity, becomes glistening, dry, and leathery. Decubitus ulcers may form and show little tendency to heal. Between the posterior wall of the vagina and the rectum there is not that intimate attachment found between the bladder and vagina—a fact which explains why, in prolapse of the posterior vaginal wall, the rectum does not always descend with the vagina (rectocele.)

Descensus and prolapsus vaginæ are recognized by inspection and palpation of the vagina. Holding the labia apart the vaginal pouch with its transverse folds is seen to bulge into the introitus. Inversion of the vagina is recognized by a corresponding shortening of the vaginal wall, together with a descent of the uterus.

Displacements of the Uterus. After inspection and palpation of the vulva and vagina, the position of the uterus is to be determined. The vaginal walls may be prolapsed to an unusual degree

PLATE XXIII.

Fig. 1.

Primary prolapse of the uterus. The uterus lies wholly outside the vulva. The vaginal walls are completely inverted; the cervix is not elongated.

Fig. 2.

Secondary descent of the uterus. The uterus is retroverted and lies on a plane lower than normal. The cervix does not extend to the vulvar outlet. The anterior vaginal wall is prolapsed, and the posterior vaginal wall is partially inverted.

without altering the position of the uterus, though this is rare. Having observed a prolapse of the vagina we expect to find a secondary descent of the uterus. The descent of the uterus may be either primary or secondary.

1. **Primary descent and prolapse of the uterus** are commonly the result of relaxed uterine supports, of added weight to the uterus, or of increase in the intra-abdominal pressure. As the uterus descends the anterior and posterior walls of the vagina become inverted from above downward, and near the outlet of the vagina the walls are relaxed. In exaggerated cases the vaginal walls may be completely inverted, thereby permitting the uterus to protrude beyond the vulvar outlet. (See Plate XXIII., Fig. 1.)

2. **Secondary descent and prolapse of the uterus** follow upon a primary prolapse of the vaginal walls. As the walls of the vagina descend, traction is made upon the uterus at the point of attachment of the vagina. If the supports of the uterus offer little or no resistance, the walls of the vagina, assisted by gravity and intra-abdominal pressure, will bring about a descent of the uterus. If, however, the normal supports of the uterus, assisted by adhesions and new-growths, retard the descent of the uterus, there will result an elongation of the cervix in its supravaginal portion. Furthermore, since the anterior wall of the vagina is first to prolapse, the anterior lip of the cervix will be elongated to a greater degree than will the posterior lip. If there is a simultaneous prolapse of both vaginal walls, the two lips of the cervix will be equally elongated. Hence, it is that in secondary prolapse of the uterus there is usually an elongation of the cervix, while in primary prolapse there is no such change.

In complete prolapsus uteri, with inversion of both walls of the vagina, the cervix having been previously elongated, will retract more or less and may be materially shortened. The direction of the long axis of the uterus varies with the descent. The usual position in descensus uteri, when the uterus lies in the pelvis, is that of retroversion, and this position is exaggerated as the uterus descends.

The *adnexæ* are drawn down by the uterus, and in complete prolapsus are found in a funnel-like depression formed of peritoneum.

The *bladder* is so intimately connected with the anterior vaginal wall and cervix that it must necessarily share in the displacement

of the uterus. As the anterior wall of the vagina pouches it drags upon the base of the bladder. In this manner a cystocele is formed, which, in complete prolapsus of the vagina, may include the greater portion of the bladder, causing it to protrude from the vulvar orifice. The exact limitations of a cystocele are determined by the catheter or sound.

FIG. 81.

Prolapsus uteri. The external os is lacerated and eroded. On the side of the prolapsed uterus is a decubitus ulcer. (Case of J. C. Webster's.)

When the bladder is distended the cystic mass is felt and seen to protrude into the vagina, and its outlines are usually determined by inspection.

The *rectum* is more loosely connected with the vaginal wall than is the bladder. The loose connective tissue may permit a complete prolapse of the posterior wall of the vagina without displacing the rectum. More often there is a pouching forward of the rectum into

the vaginal pouch (rectocele). By direct palpation through the rectum the location and extent of the rectocele are determined.

The anatomical changes occurring in the prolapsed tissues are largely the result of disturbance in circulation, of exposure to the influence of air, and of friction of the thighs. There is first congestion and œdematous infiltration, and this is followed by induration (hyperplasia) of the tissues. Decubitus ulcers, slow in healing, may form on exposed surfaces. Where the lips of the cervix are retracted, the exposed mucous membrane of the cervix may be transformed into stratified epithelium.

Clinical Diagnosis. The diagnosis of descensus and prolapsus uteri is seldom difficult. It is very unusual to find a prolapsed uterus in a nullipara. Byea estimates that prolapsus uteri in nulliparæ occurs in not more than one per cent. of all cases.

When upon physical examination the pelvic floor is found relaxed or lacerated, and there is also found a retocele and vesicocele, it is highly probable that the uterus will be found more or less prolapsed. A positive diagnosis can only be made by locating the fundus of the uterus in a bimanual examination. The patient being under anæsthesia, firm traction upon the cervix with the vulsella forceps will determine the exact extent of the displacement. The finding of the cervix at a lower level than is normal will not suffice for a diagnosis. Such a finding is not seldom due to an elongation of the cervix, either with or without a descent of the uterus. Without having located the fundus it cannot be said that the uterus, as a whole, has descended. By a rectal examination it is often possible to locate the point of juncture of the cervix and uterine body, and estimate with some degree of accuracy the length of the cervix. Measuring the depth of the uterus by the sound will give exact information.

It is more difficult to determine whether it is the supravaginal or infravaginal portion of the cervix that is elongated. This is ascertained by noting the depth of the vault of the vagina. If decreased in depth, the supravaginal portion of the cervix is elongated; if it remains at the normal level, the infravaginal portion of the cervix is elongated. Both the infravaginal and supravaginal portions of the cervix may be increased in length, in which event there will be little change in the depth of the vault of the vagina.

When the uterus is completely prolapsed, it is possible to approximate the hands over and above the body of the uterus, having

merely the vaginal walls and bladder between the fingers. By so doing it is possible to absolutely exclude all other conditions.

Can the displacement of the vagina and uterus be corrected? This question will naturally arise before the diagnosis is complete. An attempt to replace the uterus may be made without anæsthesia, but where there is much tenderness or where great difficulty is encountered an anæsthetic should be given. Among hinderances to the replacement of the uterus may be mentioned pelvic tumors,

FIG. 82.

Bimanual palpation of the prolapsed uterus.

adhesions, inflammatory exudates, and swelling from œdema and induration of the uterus and vagina.

While the clinical symptoms cannot be relied upon in the diagnosis of prolapsus uteri, they are fairly constant and deserve consideration.

Backache is the most common complaint, but is more often due to diseases of the adnexæ and to inflammatory exudates complicating prolapsus.

Feeling of weight, pressure, and *traction* is to be accounted for by the increased size of the uterus, by pressure upon neighboring structures, and by traction upon adhesions and the natural supports of the uterus.

Leucorrhœa and *menorrhagia* are the result of passive congestion of the uterus, which in turn is the result of the displacement.

FIG. 83.

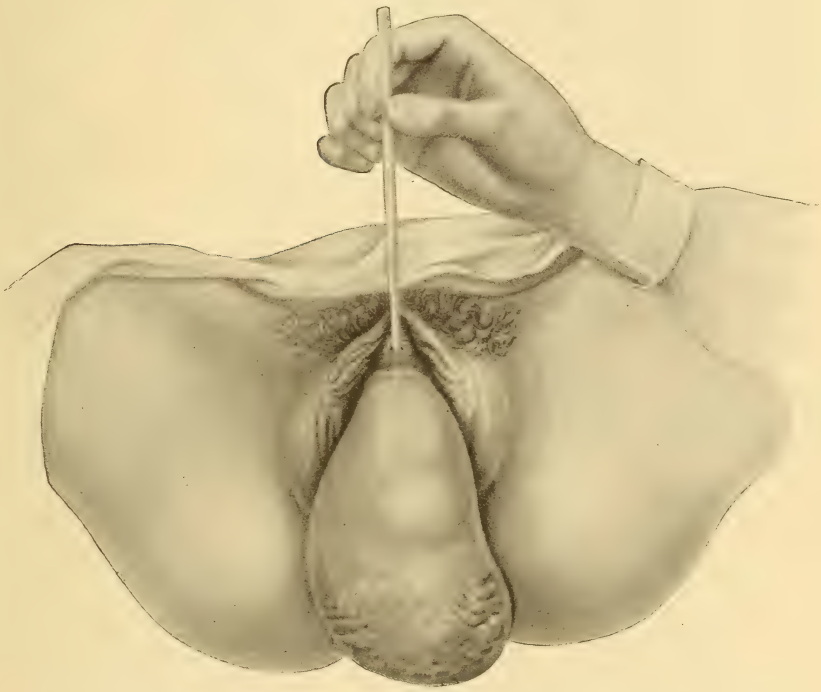

Prolapse of the third degree. Uterus protruding through the vulva. Sounds demonstrate the bladder to be in complete descent with the uterus. (SCHAFFER)

Sterility is due to mechanical hinderances and to complicating lesions in the uterus and adnexæ. Pregnancy in a prolapsed uterus will either terminate spontaneously or go on to full term. *Abortion* is most likely to occur about the fourth month, when the pregnant uterus can no longer be accommodated in the limited space of the pelvis. If, however, the uterus does rise into the abdominal cavity, the prolapsus is relieved for the period of pregnancy. Involution in the puerperium is likely to be retarded, and the lochial discharge may remain bloody an unusually long time.

Disturbances of the bladder functions are almost constant, and are explained by pressure upon the bladder and the displacement of the bladder and urethra. Retention of the urine is possible even to the point of rupture. Cystitis may develop.

The *rectal functions* are generally disturbed, though not to the extent and frequency found in the case of the bladder. Constipation, rectal tenesmus, and hemorrhoids are the result of pressure made upon the rectum by the prolapsed uterus.

FIG. 84.

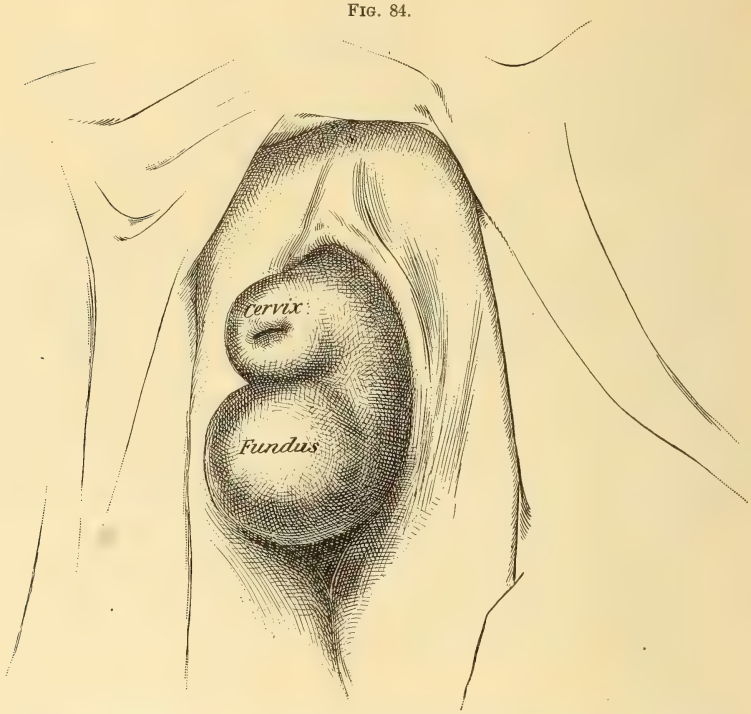

Prolapse of the third degree. Retroflexed uterus protruding through the vulva. Fundus covered by the posterior vaginal wall. (DUDLEY.)

Differential Diagnosis. Prolapsus uteri is most often confused with an elongated cervix. The differential diagnosis has been considered in a previous paragraph. The vaginal portion of the cervix may be so enormously enlarged as to resemble a prolapsed uterus.

Complete prolapsus uteri with atresia of the cervix may be mistaken for an inverted uterus. The finding of the fundus will clear up the diagnosis.

PLATE XXIV.

Fig. 1.

Secondary prolapsus uteri with elongation of the cervix. Both vaginal walls are completely inverted. The cervix protrudes from the vulva. Neither the bladder nor the rectum are found in the protruding structures.

Fig. 2.

Complete inversion of the uterus.

A large cyst of the vagina may protrude from the vulva, and on superficial examination be mistaken for a prolapsed uterus. Such cysts do not lie in the median line; they fluctuate, and are covered with thin mucous membrane. A recto-abdominal examination, under anæsthesia if necessary, will enable the examiner to locate the body of the uterus in its normal position.

A pedunculated submucous fibroid protruding into the vagina, or a pedunculated fibroid of the cervix, may be mistaken for a prolapsed uterus. The absence of the external os in the advancing body, the finding of the fundus within the pelvis at its normal level, and the passage of a sound into the uterine cavity will clear the diagnosis.

INVERSION OF THE UTERUS.

Inversion of the uterus is the partial or complete turning inside out of the organ.

Etiology and Mechanism. Puerperal inversion is by far the most common form. It occurs in the puerperium nine times more frequently than at any other time. Traction upon the cord in retained placentæ is the usual way by which the accident occurs. (See Plate XXIV., Fig. 2.)

In 192,000 labors at the Rotunda Hospital in Dublin, but one case is reported. Kehrer's estimate is 1 in 2000 labors. The one essential condition in all inversions of the uterus is atony of the musculature in some part of the uterine body. Predisposing factors to atony of the uterus are frequent childbearing, protracted labors, hydramnios, twin pregnancy, precipitate labors, and repeated miscarriages. With these conditions operating to fatigue and relax the uterine musculature, it only needs such procedures as traction upon the cord and compression of the fundus to effect an inversion.

Spontaneous inversion may occur during or immediately following the third stage of labor, the mechanism being not unlike that of intussusception of the bowels. Of 100 cases of inversion of the uterus collected by Beckmann, 54 were spontaneous, 21 were directly caused by traction upon the cord, and 25 were from unknown causes. Of the spontaneous cases many were accounted for by the presence of short cords or cords twisted about the neck of the fœtus. Immediately upon expulsion of the child a vacuum is created in the uterus, and, if in addition there is atony of the fundus, the intra-abdominal pressure may produce an inversion.

It is difficult to account for inversions occurring late in the puerperium. Those due to tumor formations in the body of the uterus are of rare occurrence. Such tumors operate first by weakening the uterine wall, and, second, by making traction upon the atonic area. Pedunculated fibroids arising from the fundus are forced through the cervix into the vagina by the contractions of the uterus. If there is a relaxation at their point of insertion this action may cause an inversion of the fundus.

FIG. 85.

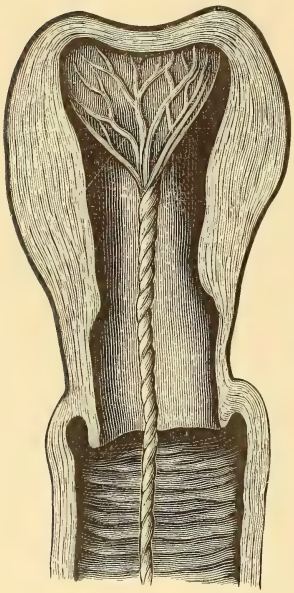

Beginning inversion of uterus, placenta attached. (Modified from RIBEMONT-DESSAIGNES and LEPAGE.)

FIG. 86.

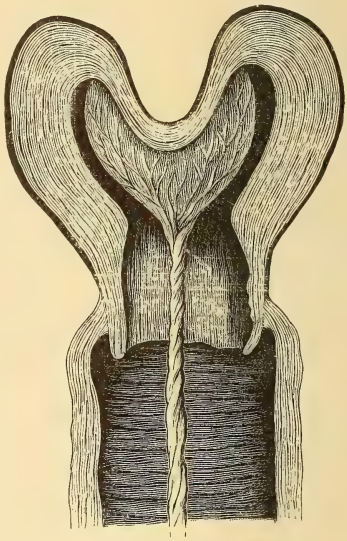

Cup-shaped depression of fundus. (Modified from RIBEMONT-DESSAIGNES and LEPAGE.)

Therefore, we may divide inversion of the uterus from an etiological point of view into :

1. Puerperal inversion.
2. Inversion due to tumor formations.

Olshausen reported a case of inversion in a girl, aged eighteen years. There was no assignable cause. This is one of the very few cases of spontaneous inversion occurring independent of labor and new-growths.

Anatomical Diagnosis. Three grades of inversion are recognized:

1. Where the fundus lies within the uterine cavity.
2. Where the fundus lies within the vagina.
3. Where the entire uterus protrudes from the vulva.

In the depression formed by the inverted fundus are found the tubes, ovarian ligaments, and part of the round and broad ligaments. The ovaries are rarely found within the depression. The mucosa

FIG. 87.

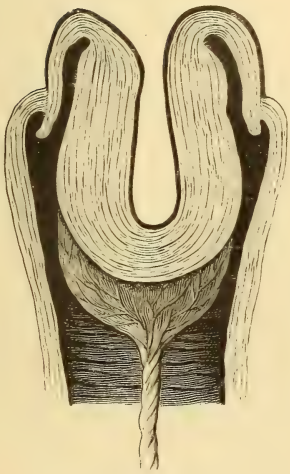

Partial inversion of uterus. (Modified from RIBEMONT-DESSAIGNES and LEPAGE.)

FIG. 88.

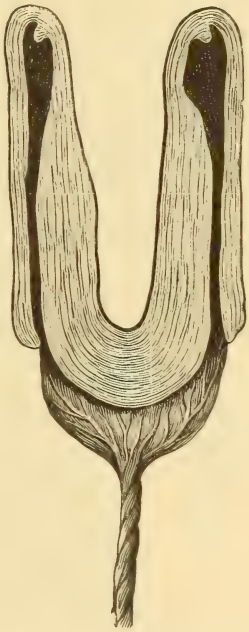

Complete inversion of uterus. (Modified from RIBEMONT-DESSAIGNES and LEPAGE.)

covering that portion of the inverted fundus lying within the vagina and external to the vulva undergoes retrogressive changes. In the beginning there is marked congestion; later erosions and true ulcers may develop, and the covering of columnar epithelium may be converted into many layers of stratified squamous cells.

Sloughing and gangrene of the inverted uterus may result from interference with the circulation.

Following the congestion of the inverted body is an enlargement of the uterus from hyperplasia, which, when of long standing and

far advanced, may prevent replacement of the inverted fundus. From the tubes infections may travel to the ovary, pelvic connective tissue, and peritoneum. Adhesions may bind together the tubes, ovaries, and coils of intestines within the funnel-shaped depression.

Clinical Diagnosis. The diagnosis can only be made with certainty by a physical examination. Subjective signs awaken no more than a suspicion of the accident. The inversion may take

FIG. 89.

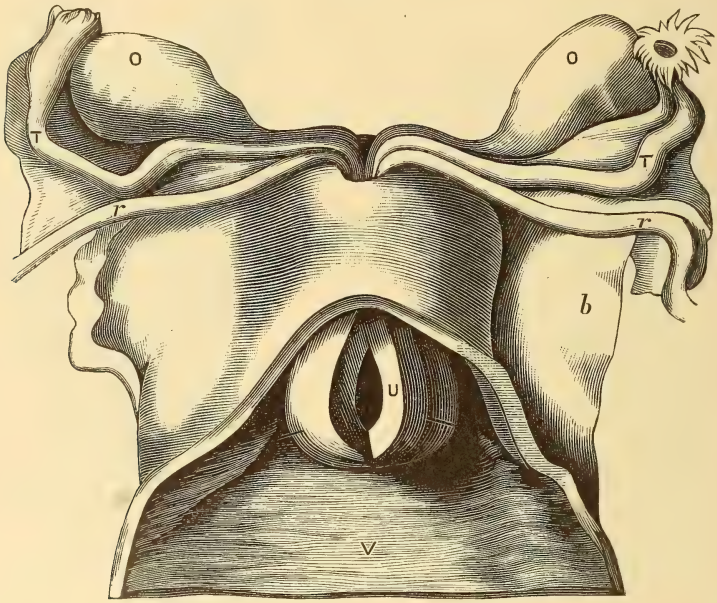

The inverted uterus *U*, lying in the vagina *V*, is cut open to show the peritoneal sac, which does not contain the ovaries *O*. Bristles are passed into the uterine orifice of the tubes. *b*. Broad ligament. *r*, *r*. Round ligament. *T*, *T*. Tubes. (HART and BARBOUR.)

place suddenly or slowly, and is referred to as acute or chronic. There is a sensation of something giving way in the pelvis, and this is immediately followed by hemorrhage. The loss of blood may result fatally, or may be limited in amount and merely prolong the menstrual flow. In the intervals of the bloody flow there is a profuse serous or seropurulent discharge. Partial inversion may occasion no symptoms and may escape notice. The functions of the bowel and bladder are disturbed, and general physical exhaustion follows.

Under favorable conditions for making a bimanual examination it is possible to demonstrate by the hand over the abdomen or in the rectum the absence of the fundus and in its place a funnel-shaped depression. By the fingers in the vagina the inverted fundus is felt bulging into the cavity of the uterus, into the vagina, or beyond the vulvar outlet. A sound placed within the bladder may assist as a guide in the bimanual examination. The finger in the rectum may be made to meet the sound in the bladder or the

FIG. 90.

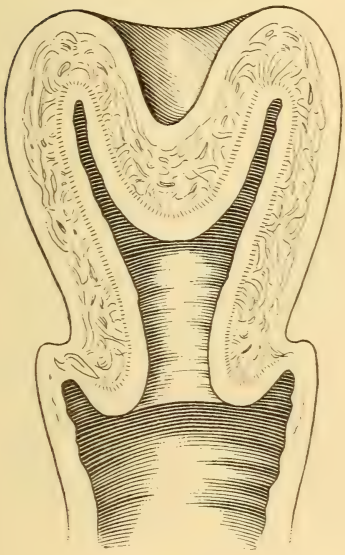

Partial inversion of the uterus: the inverted fundus lies within the cavity of the uterus.

FIG. 91.

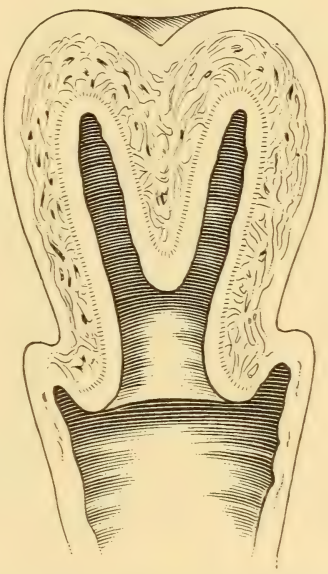

The uterus is divided by a septum from the fundus to the internal os.

hand on the abdomen, thereby demonstrating the absence of the uterine body.

In the protruding fundus are seen the tubal openings, there being no external os. Where the inversion is not complete the cervix may form a contraction ring about the presenting fundus.

By drawing upon the fundus with one hand, the fingers of the other hand in the rectum may be hooked over the margin of the funnel-shaped depression.

A sound passed into the vagina and between the protruding fundus and cervix will extend a limited distance and equally so

around the entire circumference. In puerperal inversion the free, rounded, bleeding mass, with its soft, shaggy surface protruding into the vagina, should suffice for a diagnosis when associated with the disappearance of the usual abdominal tumor.

Differential Diagnosis. **Pedunculated fibroids and polyps lying within the vagina** are to be differentiated from inversion of the second degree by locating the fundus of the uterus within the pelvis by a recto-abdominal examination; second, by passing a sound into the uterus and finding the cavity of normal or increased depth; third, by the absence of tubal openings in the protruding mass.

Submucous polyps and fibroids lying within the cavity of the uterus show by the passage of the sound an increase in the depth of the

Fig. 92.

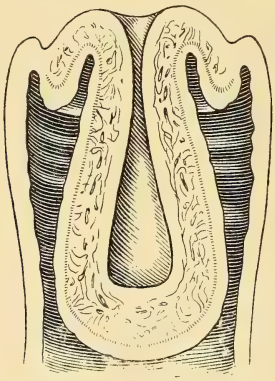

Complete inversion of the uterus.

cavity of the uterus, and by a recto-abdominal or by a vagino-abdominal examination the fundus is located within the pelvis. Care must be taken in passing the sound that the growth does not obstruct the passage of the instrument, giving the impression that the uterine cavity is shortened.

A partially divided uterus with a depression in the fundus may, in the passage of the sound and palpation of the fundus, give the impression of a partial inversion.

Submucous fibroids with partial inversion may not be recognized from a simple inversion before operating for the removal of the tumor.

Prolapsus uteri is distinguished from an inversion by the obliteration of the vaginal fornices, by finding the external os at the bottom

of the protruding mass, and by the absence of a cup-shaped depression in the fundus. A sound passed through the cervix will sink to the depth of the normal uterine cavity.

FIG. 93.

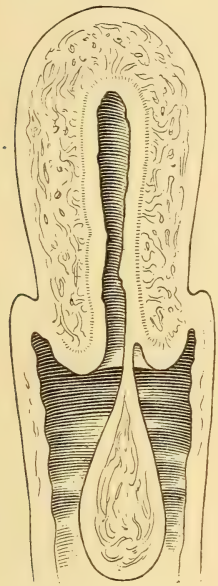

FIG. 94.

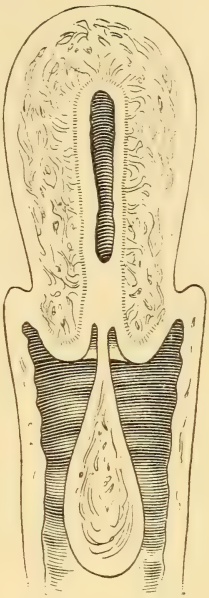

FIG. 93.—Cervical polyp, possible to mistake for an inverted fundus. The differential diagnosis is made by passing a sound into the uterine cavity and by locating the fundus in a bimanual examination.

FIG. 94.—Cervical polyp with atresia of the cervix. A sound cannot be passed into the uterus, but the fundus is located within the pelvis by a conjoined examination.

ANTEVERSION OF THE UTERUS.

No sharp distinction can be drawn between a physiological and a pathological anteversion of the uterus. Within perfectly normal limits the long axis of the uterus is turned forward upon an imaginary transverse axis. A permanent exaggeration of this condition may be regarded as pathological.

Etiology. A temporary and physiological anteversion is found when the rectum is distended and the bladder empty, and also in the early months of pregnancy.

Chronic metritis is the most common cause of pathological anteversion. The increased weight of the uterus causes the body to fall forward, the cervix to turn backward.

Contraction of the uterosacral ligaments from a retro-uterine

cellulitis will draw the cervix backward and tilt the body forward. Here retroposition is commonly associated with anteversion.

More rarely adhesions bind the anterior surface of the uterus to the bladder or abdominal wall.

Any swelling behind the uterus may exert pressure upon the uterus in a manner that will produce an anteversion.

A mural fibroid located in the anterior wall of the uterus may cause the uterus to revolve forward by increasing the weight of the body.

The *diagnosis* is made by a conjoined examination. The cervix points backward, or backward and upward, and the body is palpated through the anterior wall of the vagina lying well upon the bladder and behind the symphysis. So extreme may the version be that the body may press down upon the anterior vault of the vagina, forming a rounded swelling not unlike a cystocele in appearance. In such a case the external os will be difficult to touch with the examining finger.

When for any reason the position of the uterus cannot be located by a conjoined examination, the sound will determine the direction of the uterine canal.

There are no characteristic symptoms. Frequent urination is the most constant complaint. Where other symptoms exist they are usually caused by complications rather than by the simple displacement.

After locating the uterus in anteversion, the next step is to determine the cause of the displacement.

ANTEFLEXION OF THE UTERUS.

As with anteversion, so with anteflexion of the uterus; it is not possible to draw a line between the normal and the abnormal position. In anteflexion the uterus is bent forward upon its long axis. The cervix is directed downward and forward and the body forward, thereby forming an angle at the junction of the body and cervix.

In an abdomino-vaginal examination the body should be engaged between the two hands and the angle of flexion felt by the finger within the vagina. When the anteflexed uterus lies in retroposition, the flexion may be best found by the finger high in the rectum feeling the angle upon the posterior surface of the uterus as the body bends forward upon the cervix. This examination will

PLATE XXV.

Fig. 1.

Anteversion of the uterus. The cervix points backward to the sacrum, the body forward upon the bladder and anterior vaginal wall. The long axis of the uterus is straight.

Fig. 2.

Anteflexion of the uterus. The uterus is bent forward upon its long axis. There is very little alteration from the normal.

PLATE XXVI.

Fig. 1.

Retroversio-flexion of the uterus with adhesions. The body is adherent in the cul-de-sac. The long axis of the uterus is bent backward, and the cervix is directed downward.

Fig. 2.

Incarcerated subperitoneal fibroid on the posterior wall of the uterus. The fibroid may be confounded with the body of the uterus.

be materially facilitated by an anæsthetic. The sound will be of special service when it is otherwise impossible to outline the uterus because of tumors and inflammatory exudates encroaching upon it. The size, shape, and consistency of the uterus will usually serve to distinguish the uterus from all such swellings.

Having determined the position of the uterus, and before any treatment is proposed, it is essential to clearly define the cause of the displacement. Is the uterus fixed or free and movable? If free and movable the fault may be a hypoplasia of the uterine wall at the point of flexion, and is, in all probability, a congenital defect. If the uterus is restricted in its movements, the cause may be a congenital or an acquired shortening of the uterosacral ligaments; new formations and exudates lying behind the body of the uterus and crowding it forward; less frequently an increase in the weight of the body of the uterus.

An intramural fibroid lying in the anterior wall of the uterus may form an angle with the cervix, which to the examining finger resembles an anteflexion. The form and consistency of the tumor, together with the passage of the sound, will locate the uterus apart from the tumor. (See Plate XXV., Fig. 2.)

Anteversion and anteflexion are frequently combined.

The subjective signs of anteflexion of the uterus are frequent urination, dysmenorrhœa, and sterility. It is not likely, as is generally believed, that dysmenorrhœa is due to obstruction to the outflow of the menstrual blood. The angle of flexion can scarcely be so acute as to interfere with the flow of blood. The explanation probably lies in the accompanying inflammatory lesions in and about the uterus and possibly also in spasmodic contractions of the internal os. Sterility can probably be accounted for by the accompanying inflammatory lesions rather than by the flexion. When the cervix points well forward the spermatozoa cannot so readily gain access to the cervix as when directed toward the posterior wall of the vagina.

RETROVERSIO-FLEXION OF THE UTERUS.

In *retroversion* the long axis of the uterus revolves backward upon an imaginary transverse axis. Such a position is physiological when the bladder is full and the rectum empty.

In *retroflexion* the uterus is bent backward upon its long axis. There is no physiological retroflexion of the uterus.

The two positions, retroversion and retroflexion, are caused by the same factors. The two are commonly combined, retroflexion following retroversion. Because of their intimate association they will be discussed together. In virgins and in chronic metritis the uterus is seldom flexed, but remains in retroversion rather than in retroversio-flexion.

Etiology. Shultze gives five causes for retroversio-flexion, namely:

1. Failure in development.
2. Fixation of the portio-vaginalis on the anterior pelvic wall.
3. Unilateral posterior fixation of the cervix.
4. Shortening of the posterior or lengthening of the anterior uterine wall.
5. Relaxation of the supporting uterine ligaments and muscles.

1. Among the **developmental failures** contributing to retroversio-flexion may be mentioned the proportionately long cervix and short vagina. In the presence of such a condition an increase in the abdominal tension or a sudden fall would be sufficient cause for a retroversio-flexion.

2. **Fixation of the portio-vaginalis upon the anterior pelvic wall** may be the result of cicatricial contraction of the anterior wall of the vagina. Hence it is that retroversio-flexion is frequently found in large vesicovaginal fistulæ and in stenosis of the vagina.

3. **Unilateral posterior fixation of the cervix** occurs in about 6 per cent. of all cases of retroversio-flexion (Shultze). The cause is retro-uterine cellulitis or peritonitis, more often confined to one sacro-uterine ligament.

4. **Shortening of the posterior wall or lengthening of the anterior wall of the uterus** is a rare finding.

5. **Relaxation of the supporting uterine ligaments and muscles** is by far the most frequent cause of retroversio-flexion. When these supports are weakened the long axis of the uterus first revolves backward upon an imaginary transverse axis (retroversion), and later, through the force of intra-abdominal pressure, the long axis of the uterus is bent upon itself (retroflexion). The stretching and tearing of childbirth largely account for the relaxation of the supporting uterine ligaments and muscles. Retroversio-flexion due to violent exertion or to a fall is difficult to establish, though not impossible. The cause of retrodisplacements of the uterus in the nullipara is difficult of explanation in the absence of swellings

crowding the uterus backward or adhesions pulling it backward. Tight lacing and habitual overfilling of the bladder will account for a limited number of these cases. Not a few are congenital, as is shown by anatomical dissections of infants. Salin found as many nulliparæ as multiparæ with retroversio-flexion. He estimates the frequency of this displacement in all cases at 18 per cent.

Heredity probably plays no rôle, though mother and daughters are often similarly affected.

During the puerperium, when the uterus is large and soft, the ligaments relaxed, and the patient lying on her back, all the conditions favoring retroversion are present. This retroversion may go on to the development of a retroflexion through the influence of intra-abdominal pressure. Rising too early from childbed favors malpositions, as well as does lying too long in the dorsal position. It is for the purpose of avoiding such malpositions that the patient is instructed to lie in bed until the uterus and ligaments are well contracted and retracted. It is obvious that the patient should not lie constantly in the dorsal position, but should from time to time assume the knee-chest position, or at least lie upon the side or face.

As to the frequency of retrodeviations of the uterus, the statistics of Winckel, Löhlen, and Sänger show an average of 17.74 per cent. of all gynecological cases (Reed).

Anatomical Diagnosis. When the cervix is crowded forward the anterior vaginal wall is relaxed, while the posterior wall is *taut.* In retroversion the cervix points forward or forward and upward, sometimes lying above the level of the symphysis. In retroflexion the cervix is directed downward and backward. When the body of the uterus lies in the hollow of the sacrum, the cervix must necessarily lie well forward to the symphysis. If, as is often found, retroversio-flexion is associated with descensus uteri, the cervix may be elongated. If a bilateral laceration of the cervix is present the vaginal walls will draw the lips of the cervix wide apart, exposing the mucous membrane of the cervical canal.

In retroversion the body of the uterus approaches the promontory, and may be found low in the pouch of Douglas. There is no angle of flexion between the body and cervix. The cervix and body lie in a straight line. In retroflexion the body may form an acute angle with the cervix. Often the uterus in retroversio-flexion inclines to the left or right, and in extreme cases is almost invariably more or less prolapsed.

Œdema and passive congestion, leading to hyperplasia of the endometrium and myometrium, are the almost inevitable results of the displacement. We, therefore, find endometritis and metritis associated with long-standing retroversio-flexion. Not seldom do diffuse peritoneal adhesions bind the uterus, tubes, ovaries, and bowel together. The tubes and ovaries lie at a low level and suffer congestion and hyperplastic changes, leading to catarrhal salpingitis and chronic ovaritis.

The bladder may be directly pressed upon by the cervix, causing frequent urination. In the retroflexed gravid uterus there may be retention of urine.

The rectum is compressed, and may be obstructed by the body of the uterus.

Clinical Diagnosis. The great number of cases of retroversio-flexion in which no symptoms are present speaks for the unreliability of subjective signs. E. Shroeder reports 411 cases examined, in which 188 (28.7 per cent.) had retroversio-flexion of the uterus, and of this number 25 per cent. were free from symptoms. He reasons that uncomplicated retrodisplacements of the uterus cause no symptoms; that those so frequently ascribed to such displacements are due to complicating lesions. Yet how often do we find extensive adhesions fixing the uterus in malpositions without causing either local or general disturbances? On the other hand, the disappearance of local disturbances immediately upon the correction of a non-complicated displacement cannot be wholly explained on the ground of suggestive treatment.

1. **Menstrual irregularities** are common, and usually take the form of an increase in the menstrual flow. This is explained by the passive congestion of the uterus. Extreme anæmia may result from the loss of menstrual blood. The menopause may be delayed because of the passive congestion. During pregnancy and the period of lactation occasional hemorrhage may be similarly accounted for.

2. The **habit of abortion** is in many instances explained by the uterine congestion.

3. **Leucorrhœa** in the form of a hypersecretion of the glands of the uterus is almost invariably present, and is caused by passive congestion of the uterus.

The congested uterus is a favorable nidus for micro-organisms, and so it happens that the glandular secretion is often mixed with pus and micro-organisms.

4. **Dysmenorrhœa** of the so-called congestive type is seldom absent. It is not probable that the menstrual flow is obstructed at the point of flexion. The occurrence of pain is probably explained by the addition of the menstrual congestion to the already congested uterus.

5. **Sterility** is a not uncommon result of retroversio-flexion of the uterus. The incapacity for childbearing should be credited not so much (if at all) to the flexion of the uterus as to the inaccessibility of the cervix to spermatozoa when crowded forward and upward, to endometritis, and to complicating lesions in the adnexa and perimetrium.

6. **Disturbances of the functions of the bladder and rectum** are accounted for by direct pressure.

7. **Pain** in the pelvis referred to the groin, thighs, and back is the most constant of the subjective signs, but cannot be regarded as of great importance from a diagnostic standpoint, because pain is not an invariable symptom and does not differ from that caused by other lesions of the pelvic viscera. Backache is a common complaint and is referred to the coccyx (coccygodynia), to the lumbar region, or to the area between the scapulæ; rarely to the cervical region. The absence of pain in many extreme retrodisplacements of the uterus suggests a doubt that the displaced uterus *per se* is the cause of the pain. Certainly the accompanying lesions, such as ovaritis, salpingitis, and perimetritis, account in large measure for the pain. Pressure upon the sacral plexus of nerves is the explanation of the pain referred to the thighs, and since the uterus is rarely found in the median line these referred pains in the lower extremities are for the most part unilateral.

8. **Reflex symptoms**, such as headache, neuralgia, dyspepsia, hysteria, and neurasthenia, are often attributed to the displacement, but it seems impossible to demonstrate such to be a fact with any degree of positiveness.

It is clear that a diagnosis cannot be based upon the subjective signs. Too many cases exist in their absence, and the complaints of the patient are those found in almost any of the lesions of the pelvis. A physical examination is therefore required to establish a diagnosis. A diagnosis includes not only the location of the uterus, but also the condition of the adnexæ and neighboring structures. Here, as in the diagnosis of all displacements of the uterus, it is first necessary to locate the uterus, and, second, to determine the

underlying cause of the displacement, and the existence of complicating lesions within the pelvis and abdominal cavity.

In making a bimanual examination the position of the vaginal portion of the cervix may be an indication of the position of the uterine body. For example, if the cervix lies in its normal position pointing downward and backward toward the second sacral vertebra, the body must lie in the normal position or retroflexed; it would be impossible for a retroversion to exist with the cervix pointing downward and backward. If the cervix lies in front of its normal position and pointing directly downward, one of two positions is present, a retroflexion or an anteposition. It is sometimes possible to recognize a retroflexion in a simple vaginal palpation by feeling the angle of flexion through the posterior fornix. Where conditions are not favorable a positive diagnosis of the position of the uterus can only be made by a conjoined examination under anæsthesia. A recto-abdominal or recto-vagino-abdominal examination afford better means of palpating the uterus when lying far back against the rectum.

The use of the sound should be restricted, but it is occasionally called into service when a bimanual examination will not suffice.

Is the Uterus Fixed or Movable? First of all we must have clearly in mind what constitutes normal mobility of the uterus. It is not enough that the uterus should permit the usual excursions when manipulated, but it must return to its normal position when pressed out of place. Failing to do so constitutes a pathological condition.

The fixity of the uterus is determined by the effort to replace it. Sensitiveness and thickness of the abdominal wall may render an anæsthetic necessary.

The technic of replacing a uterus in retroversio-flexion is briefly outlined as follows:

The bladder and rectum are empty. The patient lies in the lithotomy position. One, and where possible without pain, two fingers are inserted into the posterior vaginal fornix, and moderate, steady pressure is made upon the uterine body in an upward and forward direction. The hand over the abdomen presses steadily in the effort to pass over and behind the fundus, as it is forced upward and forward by the fingers in the vagina. Sometimes the body will rotate forward by the finger pressing backward upon the cervix. With the middle finger in the rectum, it is possible to exercise more

direct pressure upon the body of the uterus in extreme retroflexion. Traction upon the cervix by a tenaculum will bring the uterus more within reach of the fingers in the vagina and rectum. An anæsthetic is usually advisable. Formerly, in reposition of the uterus, a sound was advised, but the dangers of perforation are too great to justify its general use. *Certain it is that the sound should not be used where the uterus is fixed.* In replacing the uterus force must not be used for fear of tearing existing adhesions, causing hemorrhage, and injuring adherent viscera.

Having determined the position of the uterus and the fact that it is not replaceable, it next becomes necessary to determine the cause of the inhibition. As possible causes may be mentioned adhesions and pelvic exudates, inflammatory contractions of the ligaments, and pelvic tumors. Peritonitic adhesions (peritonitis) for the most part arise from extension of infection through the tubes and are most often found about the tubes and ovaries. Since infected tubes commonly lie in the cul-de-sac of Douglas, the surrounding adhesions may bind the uterus to the rectum in retroversion or retroflexion. Peritoneal adhesions are recognized by their location on surfaces covered with peritoneum and by the ease with which they may be broken up as compared with parametritic adhesions.

Parametritic adhesions correspond in location to cellular tissue of the pelvis which is found between the layers of the broad ligament, underneath the pouch of Douglas, and to a limited extent in front of the uterus beneath the vesico-uterine fold of peritoneum.

Retroversio-flexion may be brought about by adhesions in the cellular tissue of the vesico-uterine space drawing the cervix forward and rotating the body backward—this, however, is quite unusual.

Retro-uterine parametritis, when involving only the supravaginal portion of the cervix, tends to produce an anteversion by drawing the cervix backward and rotating the body forward. In extreme cases the uterorectal fold of peritoneum may be crowded upward and permit the parametritic adhesions to adhere high up upon the posterior surface of the uterus, and by traction upon the body a retroversion is caused. Parametritic adhesions are thicker and firmer than they are in parametritis. They are found on a lower level, are more accessible through the vagina, and are located where the cellular tissue of the pelvis is found.

Pregnancy in a retroflexed uterus may prove a serious condition.

No special difficulty is experienced in the first two months, but in the third and fourth months the uterus, no longer able to accommodate itself to the small pelvis, is prevented from rising into the abdominal cavity. As a result pregnancy will be interrupted, or pressure symptoms will become increasingly severe and demand operative interference. On bimanual examination the large, soft, and elastic uterus may be found to bulge into the posterior vaginal fornix even to the introitus. The cervix is forced high behind the symphysis, and is directed forward or forward and downward. The soft cervix and softer lower uterine segment may be felt to connect at an angle with the large, rounded, soft, and elastic body of the uterus. Because of the great softening the uterine body may appear detached from the cervix, and in case the cervix is hypertrophied it may be mistaken for the entire uterus and the body may be thought to be a new-growth.

Differential Diagnosis. Retroversio-flexion is most often confounded with *retroposition.* In the latter the cervix lies in the posterior segment of the pelvis, while in retroversio-flexion it lies anterior to the normal position. In both conditions the body of the uterus lies far back in the pelvis, but in the latter the long axis of the uterus is no longer in the normal line of direction.

Anteflexion may be mistaken for retroversion. The cervix points in the same direction—forward and downward—and the body may be small and therefore overlooked or mistaken for the supravaginal portion of the cervix. If on bimanual examination the body of the uterus cannot be located a sound may be passed.

A retro-uterine subperitoneal or interstitial fibroid may form an angle with the cervix that can be mistaken for the body flexed upon the cervix. The body of the uterus is recognized by its size, form, consistency, and direct relation to the cervix. Such a fibroid should present a circumscribed area of firmer consistency and produce an irregularity in the uterus. Where the bimanual examination will not suffice for a diagnosis, the uterine sound may be used.

Swellings of the tubes and ovaries lying behind the uterus, retro-uterine hæmatoma and hæmatocele, and parametritic exudates are all to be differentiated from retroversio-flexion by a consideration of the clinical history and by finding a mass behind the uterus that differs in size, form, and consistency from the uterus, and which, by the use of the sound, is found to be separate from the uterus. For further discussion, see respective chapters on these subjects.

HERNIA OF THE UTERUS (HYSTEROCELE).

Hernia of the uterus is of rare occurrence. The rupture usually occurs through the inguinal canal, less often through the crural ring. The only two recorded cases of crural hernia are those of Bowen and Duges. Fifteen cases of inguinal hernia of the uterus were collected by Küstner; of these, eight were pregnant. The explanation of the development of the hernia is usually given as traction made upon the uterus by adhesions binding the hernial sac to the uterus and drawing the uterus within the sac. There is generally some associated anomaly in development.

The diagnosis is made by palpation and by an exploratory incision.

Hernia of the uterus through the linea alba may follow ventro-suspension. Plate IX. represents a hernia of a uterus in the fourth month of pregnancy.

CHAPTER XXII.

THE DIAGNOSIS OF DISEASES OF THE VULVA.

For a detailed description of the anatomy of the external genital organs, the reader is referred to text-books on gynecology and human anatomy.

ANOMALIES IN THE DEVELOPMENT OF THE VULVA.

Absence of the Vulva. This condition is very rare, and is, as a rule, associated with a congenital absence of the internal organs of generation. Absence of one or more of the component structures of the vulva is not of such rare occurrence, and may be found associated with well-formed internal organs of generation.

Double vulva is an extremely rare condition. The clitoris may be absent, bifid, small, or large.

Atresia of the vulva may be found associated with a communication between the rectum, bladder, and genital canal. The fœtus is rarely viable, but may be found in mature years.

The infantile type of the vulva may be maintained after puberty.

The entire vulva, or one or more of the component parts, may fail to mature to the full sexual type. Cretins and dwarfs mostly retain the infantile type. The vulva may mature at the time of puberty, and subsequently undergo atrophic changes involving part or all of the vulva. Causes for such atrophy are found in the wasting diseases, in certain nervous disorders, such as epilepsy, and after removal of the ovaries. A physiological atrophy occurs after the menopause.

Hypertrophy of the vulva rarely involves all structures composing the vulva. The clitoris is most commonly affected, it sometimes assumes the proportions of the penis, and has been mistaken for it.

Congenital Fissures of the Vulva. (*a*) *Epispadias* is caused by failure of closure on the part of the anterior abdominal wall, together with a dehiscence of the anterior wall of the alantois. The alantois thus communicates with the outer world.

(*b*) *Hypospadias* is formed by a persistence of the urogenital sinus. The urethra and vagina open high up in the vestibular canal. The perineum is well-developed. The urethra may be

FIG. 95.

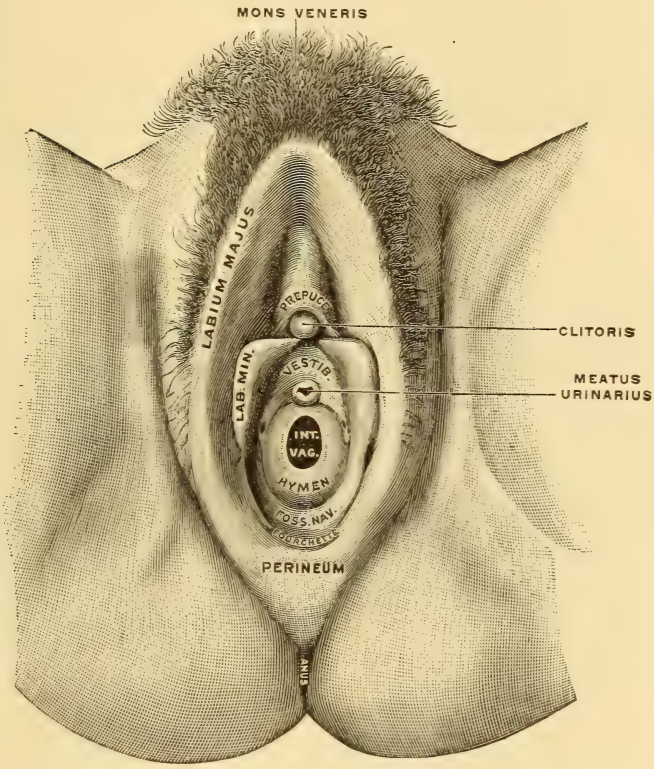

Vulva of a virgin. The labia have been widely separated. (TESTUT.)

absent and the bladder communicate directly with the vagina. Here the urogenital sinus has disappeared, and the bladder and vagina open directly into the vestibular canal.

HERMAPHRODITISM.

True hermaphroditism has not as yet been proven to have an existence. Nagle says that it is not likely that the ovaries and testicles can coexist, and without their coexistence true hermaphroditism is impossible.

In *pseudohermaphroditism* the vulva presents the appearance of the male genital organs. The hypertrophied clitoris resembles the

penis; the coalescence of the labia majora and minora hiding the vagina suggests the scrotum. One or both ovaries may descend into the coalesced labia and be mistaken for the testicles within the scrotum.

On the other hand, there are males in whom the external genitals resemble those of the female. The testicles may either be absent or not descended; there may be a small penis, no larger than the clitoris, and the scrotum may present a median depression. Where the urogenital sinus persists, the male type may be closely simulated. In such cases the urethra opens at the base of a very small penis, and running from the urethra to the base of the penis is a frænum. Rudimentary labia and hymen lie below the urethra, and above this a vagina of variable extent. The uterus and tubes are present, but are often quite rudimentary. The general development of the pelvis, larynx, and breasts suggests the feminine type. Such individuals commonly pass for females, and the true condition may not be recognized even after marriage.

VULVITIS.

Etiology. In seventy examinations of the secretions found in the vestibule, Menge found the streptococcus three times, the staphylococcus twice, and the bacterium coli communis once; in all cases saprophytic bacteria were found. Menge accounted for the infrequency of pathogenic bacteria on the ground of bactericidal action of the vaginal secretion. The tubercle bacillus has been demonstrated in the secretions of the vulva by Menge, Chiari, Dechamps, and Demure. Diphtheritic vulvitis has been identified many times by the finding of the specific organism.

It has been estimated that 75 per cent. of the cases of vulvitis are caused by gonorrhœa. The leptothrix and oidium have been demonstrated by Wenkel.

In addition to the above-named essential factors, may be mentioned certain exciting causes, such as excessive sexual intercourse, masturbation, uncleanly habits, irritating urine, and vaginal secretions.

The following varieties are recognized:

Vulvitis furunculosa, in which multiple small abscesses are found upon the labia majora, less frequently upon other portions of the vulva. These abscesses are usually found in the sebaceous and

sweat glands. Of all the glands of the vulva, the Bartholinean glands are most commonly infected, and gonorrhœa is the cause in a great majority of the cases. As a rule, the glands are not extensively involved. The mouths alone of the glands may be involved, giving rise to the so-called "maculæ gonorrhœica" of Sänger. Gebhard affirms that when suppuration occurs in the gland there is always a mixed infection of the gonococcus and staphylococcus. It is very unusual to observe Bartholinitis in infants. The size which these infected glands may attain is from that of a split pea to a man's fist.

FIG. 96.

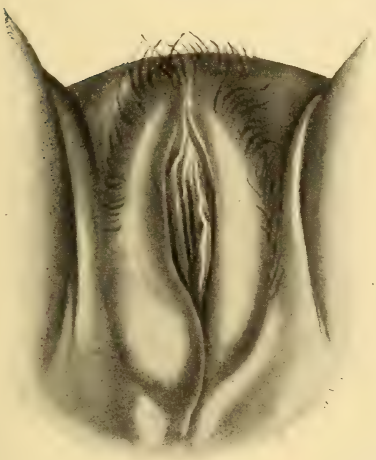

Enlargement of the vulvovaginal gland by cyst or abscess. (SCHAFFER.)

FIG. 97.

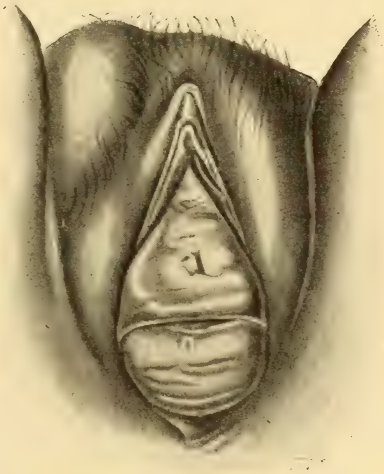

Right inguinal hernia simulating vulvovaginal cyst or abscess. Eversion of anterior and posterior vaginal walls. (SCHAFFER.)

The infected Bartholinean gland is located in the labia majora; is round or oval, firm or fluctuating, and may or may not be tender to pressure.

It is to be differentiated from hernia into the labium (Figs. 96 and 97). The latter is not tender to pressure, is elongated, tympanitic on percussion, and may be made to disappear by taxis. When reduction of the hernia is impossible, and when strangulation and gangrene of the gut have occurred, the usual symptoms of intestinal obstruction will suggest the probable nature of the swelling. Evidence of gonorrhœal infection elsewhere in the genito-urinary tract will be suggestive.

Puerperal vulvitis occurs as a result of an irritating lochial discharge. A diffuse erythema and ulceration may arise. The ulcers are usually superficial, with a gray or brownish colored base and an infiltrated margin. A false membrane may cover the ulcerated surface, suggesting in appearance a diphtheritic ulcer. The organism commonly found in these ulcers is the streptococcus. Very rarely the Klebs-Loeffler bacillus is obtained.

Erysipelatous vulvitis may arise from a primary infection of the vulva by the streptococcus of erysipelas. It is frequently observed in the newborn. In a case of the author's it spread from the vulva to the vagina, uterus, tubes, and peritoneum.

Tuberculous vulvitis is a rare lesion. Irregular ulcerations are found at any point in the external genitals. These ulcers have a ragged, undermined margin, with an irregular base covered with pus and studded with grayish tubercles. Fistulæ may lead to the bowel. Extensive cicatrization, causing deformity of the vulva, may follow the ulceration. The tubercle bacillus is difficult of demonstration in the secretion. The outpour from the involved structures will show giant cells and tubercles, more rarely the tubercle bacillus.

Syphilitic vulvitis occurs in the primary, secondary, or tertiary stages. In the primary stage the chancre may be found at any point on the vulva. The lesion varies in proportion to the associated œdema and cellular infiltration, the greatest swelling occurring in the labia majora, where the cellular tissue is loosest and most abundant. In the secondary stage the vulva is often covered with condylomata, which early ulcerate and are covered with a slimy secretion of a highly infectious nature. In the tertiary stage gummata are rarely found.

The so-called soft chancre (ulcus molle) has its favorite seat in the frænulum and labia minora. The ulcer formed from the soft chancre is round, with a sharp border and a smooth base covered with pus. In the neighborhood of the ulcer the vessels are markedly dilated.

CIRCULATORY DISTURBANCES OF THE VULVA.

During pregnancy, and in the case of pelvic tumors and inflammatory exudates, the veins of the vulva may be widely distended. Thrombosis of the veins and calcareous deposits in the coagula (vein stones) are not of infrequent occurrence.

PLATE XXVII.

Vulva of non-parous woman, closed. (Jewett.)

PLATE XXVIII.

Vulva of non-parous woman, open, hymen intact.
(Jewett.)

PLATE XXIX.

Vulva of parous woman, closed. (Jewett.)

PLATE XXX.

Vulva of parous woman, open. (Jewett.)

Angioma vulvæ is a term applied to polypoid protuberances formed from dilated veins and blood extravasations. The mass is of a bluish color. Rupture of the veins may result seriously.

Hæmatoma of the vulva may arise from rupture of the veins during labor or from direct injury. Such accumulations of blood may attain the size of a man's head. While suppuration of the blood clot may occur, gradual absorption is the rule.

Œdema of the vulva may arise from an obstruction to the general circulation in diseases of the heart, kidney, liver, etc., but it is more often the result of local interference from pressure of the pregnant uterus, pelvic tumors, and exudates. The swelling may be bilateral or confined to one side, and may be as large as a child's head.

Gangrene of the vulva has been observed in weakly children, in the course of septic febrile diseases, and following pregnancy.

Hypertrophy of the Vulva. The clitoris and labia majora may undergo simple hypertrophy, either as a congenital or as an acquired lesion. The increase in size may or may not be inflammatory in origin. Of hypertrophic lesions due to inflammation the most common are the *condylomata acuminata*, which are almost invariably of gonorrhœal origin.

The latter growth is particularly rapid during pregnancy and is said to be caused by the irritating vaginal discharge. In the early stage of development these warty outgrowths are pale red or gray. Later the papillary projections become confluent and may assume the proportions of a man's fist. Occasionally the growth is pedunculated. They are found distributed over part or all of the vulva, vagina, and the neighboring skin surface of the mons veneris, groin, buttocks, and perineum. The lesion is essentially an overgrowth of the papillæ. The greater part of the growth is due to an increase in the epithelial covering of the papillæ. In general appearance such a growth is not unlike a cauliflower carcinoma. The distinction is made by the frequent occurrence of the growth during pregnancy; by the history of gonorrhœa, and the presence of gonococci in the secretions, together with other evidences of gonorrhœa; by the age of the individual, and, finally and conclusively, by the microscopic examination of an excised piece in which there is an absence of epithelium invading the underlying connective tissue.

Elephantiasis. In the early stage of development the growth is not unlike simple hypertrophy, but as it progresses it tends to

become more and more pedunculated and may extend to the knees, weighing several pounds. When the surface is smooth it is known as *elephantiasis glabra;* when nodular, *elephantiasis tuberculosa,* and when covered with warty excrescences, *elephantiasis condylomata.* The surface may be more or less ulcerated.

FIG. 98.

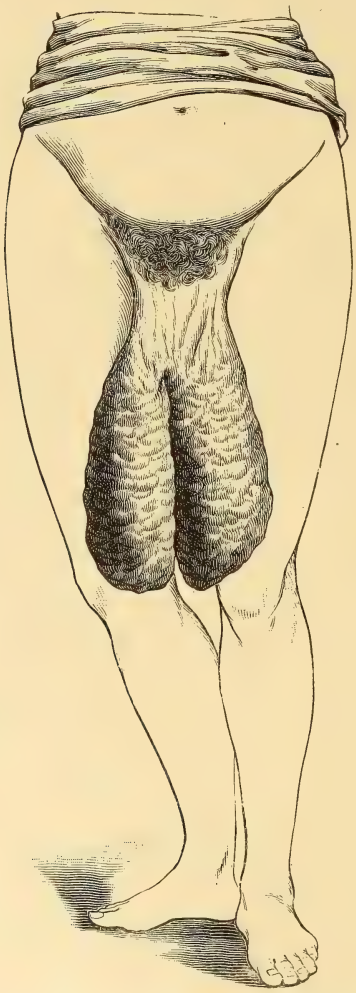

Elephantiasis of the vulva. (BONNET and PETTIT.)

The point of origin may be the labia majora, labia minora, mons veneris, or clitoris. It is unusual for the growth to arise simultaneously from two or more of these surfaces.

The greater portion of the growth is of connective tissue, with œdematous infiltration of the connective tissue spaces. There is a scant blood supply to these growths.

The essential cause is as yet unknown. Elephantiasis sometimes arises from the base of old ulcers and suppurating buboes. Stenosis or occlusion of the lymph channels is undoubtedly an underlying factor, but the cause of obstruction to the lymph channel is unknown.

The patient consults the physician because of the weight of the growth and its interference with walking and coition.

The diagnosis will involve little difficulty. It is distinguished from carcinoma by the absence of friability, the slow growth, and, finally, by a microscopic section showing an absence of epithelial invasion of the connective tissue and the presence of connective tissue hyperplasia. There are no constitutional effects.

Urethral caruncle is a localized inflammatory hypertrophy of the urethral mucosa located near the external meatus. These elevations are usually single, rarely multiple. They attain the size of a hazelnut, are red or bluish-red in color, sensitive to pressure, soft, and attached by a broad base or pedicle. The surface is smooth or folded, and bleeds but slightly on handling.

The growth consists in large part of connective tissue infiltrated with small round cells, with here and there blood extravasations. The surface is commonly covered with several layers of the flat epithelium of the vestibule. Tubular glands invade the structure, and are lined with epithelium varying in form from flat to columnar. Neuberger believes gonorrhœa to be an underlying cause. The lesion is frequent in old age. Urination and sexual intercourse are painful, because of the great sensitiveness of the caruncles.

ATROPHY OF THE VULVA (Kraurosis Vulvæ).

After the menopause there occurs a physiological atrophy of the vulva, in which the labia majora lose their plumpness, the labia minora diminish in size and may wholly disappear, the clitoris is shortened, the mucous membrane becomes dry and pale, and the vulvar orifice is narrowed.

Kraurosis vulvæ is a term applied to a specific form of atrophy of the vulva, the cause of which is unknown. The extent of the atrophy may be greater than the atrophy of old age. The labia majora are flat and flaccid, while the mucosa may be so friable as

to be injured by the examining finger. The labia minora and clitoris may wholly disappear. In addition to the dryness of the surface there is extreme sensitiveness. Dyspareunia is a common

FIG. 99.

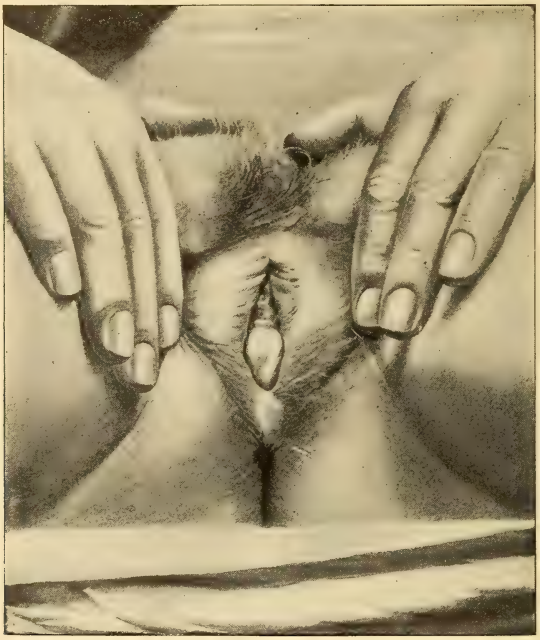

Kraurosis vulvæ. Clitoris and labia minora completely atrophied; the labia majora flattened and wrinkled. (GEBHARD.)

FIG. 100.

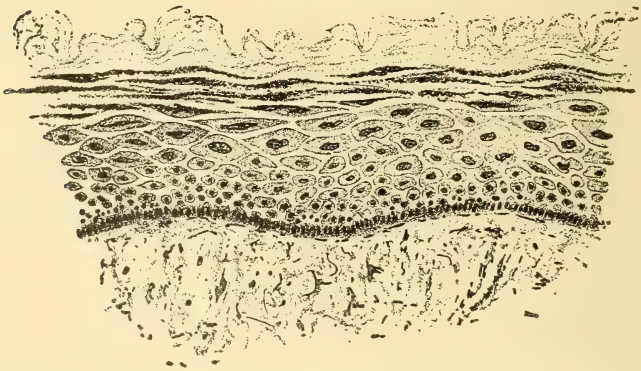

Kraurosis vulvæ. Marked hornification of the corium, with round-cell infiltration; papillæ are absent. (GEBHARD.)

complaint, and when associated with itching and a sense of dryness in the vulva the possibility of kraurosis is to be borne in mind. Kraurosis occurs chiefly in women of advanced age; in women who have borne children and have become sterile; in the married, and in the widow. The lesion sometimes follows removal of the ovaries. That it is due to syphilis and gonorrhœa is quite improbable.

The lesion is probably of inflammatory origin. The glandular structures of the affected area disappear; the papillæ are poorly developed, and the corium is atrophied.

NEW FORMATIONS OF THE VULVA.

Benign tumors of the vulva are of rare occurrence.

Fibromata arise from the subcutaneous connective tissue of the labia majora and minora, rarely from the clitoris. They are slow in their growth, firm, round, and sharply circumscribed. The overlying skin is not adherent to the tumor. They are known to grow to the size of the patient's head and hang by a pedicle as low as the knees. The microscope shows the tumor to be composed of connective tissue intermixed with a limited amount of smooth muscle fibre. Cystic degeneration and calcareous deposits have been described.

Lipoma arises from the subcutaneous fat of the mons veneris and labia minora. They are not so frequently found as are fibromata. They are usually circumscribed, soft in consistency, sometimes apparently fluctuating, and are attached either by a broad base or pedicle. I am able to find only twenty-two cases of lipoma of the vulva in the literature. They are found anywhere from the fifth month of infancy to the fifty-first year.

Enchondroma has not been demonstrated beyond doubt.

Neuroma have been described as sensitive papillæ or warts, though the descriptions leave some doubt as to their identity.

Peckham described a cyst of the clitoris weighing 60 gms., and filled with a chocolate-colored fluid.

Sebaceous cysts are found in the labia, the base of the prepuce, and at the base of the hymen. They appear in the form of small, yellowish, semitransparent elevations filled with sebaceous material. Small, soft-walled cysts lying at the free margin of the hymen may be regarded as lymph cysts.

Dermoid cyst of the vulva is of rare occurrence.

Vulvar cysts have little clinical significance. An accompanying pruritus may disclose their presence.

CANCER OF THE VULVA.

The vulva is strangely exempt from infection and malignant degeneration. In 1147 cancers of the female genitalia Schwarz found 30 to be primary in the vulva. Wenkel tabulated the report of 54 cases, in which he found 6 before the age of forty, 16 between forty and fifty, 20 between fifty and sixty, and 20 over sixty years of age.

The site of predilection is the outer skin surface of the labia majora; less frequent points of invasion are the frænum, clitoris, Bartholinean glands, anterior and posterior commissure, and urethral opening. The labia minora are seldom a primary site. (See Plate XXXI.)

The lesion is characterized by superficial infiltration, by ulceration, and by early involvement of the inguinal glands. The growth may be diffused or circumscribed. The circumscribed growths rarely fail to rise above the level of the skin surface. They are commonly round or oval, the surface smooth, nodular, or papillary. They may grow to the size of a man's fist. At first firm in consistency, sooner or later they disintegrate and form ulcers more or less superficial. The diffuse form may not be evident to the naked eye, and is recognized by its rigid, firm feel. Superficial ulceration is usually not long in appearing. There is nothing unusual in the appearance of the ulcer, the base is uneven, bleeding freely to the touch, and covered with a purulent, foul-smelling secretion; the margins of the ulcer are irregular, hard, and elevated. In advanced cases the ulceration may extend to deep crater-like excavations, with markedly infiltrated borders.

Schwarz found the inguinal glands infiltrated with cancer cells eleven times in twenty-three cases. The rate of growth is often slow. The direction to which the growth extends varies. Most commonly the extension is to the vagina and from the vagina to the rectum, bladder, and pelvic connective tissue. In not a small percentage of cases the opposite labium is invaded (contact metastasis).

The microscopic characters of vulvar carcinoma differ somewhat

PLATE XXXI.

Cancer of the Vulva.

Irregular columns of epithelium project from the surface into the connective tissue. Isolated cancer nests and pearls are distributed through the connective tissue. There is a round-cell infiltration throughout and hyaline degeneration of the pearls.

from those of cancer of the vagina and cervix. There is an unusual tendency on the part of the epithelial projections to branch; cancer pearls are said to be relatively rare, although in two specimens, one removed by Dr. Reuben Peterson, the other by Dr. J. Clarence Webster, I found an unusual number of cancer pearls. The extension of the cancer cells along the lymphatics gives the appearance of veins of marble. Cancer of the glands of Bartholin is rare. The gland may assume the size of a man's fist, become hard and nodular, with a movable, normal appearing overlying skin. The diagnosis without the aid of the microscope may be impossible. The lesions to be considered in making a diagnosis are the benign new formations (lipoma, fibroma) with ulcerated surface, ulcus rodens, tuberculosis, syphilis, and elephantiasis. In making the diagnosis we rely upon the age of the individual, the general effect upon the system, early and superficial ulceration, involvement of the inguinal glands, and above all upon the microscopic examination of an excised piece of the tumor. The prognosis is relatively good. Schwarz saw ten recoveries in twenty-three cases.

SARCOMA OF THE VULVA.

This is a very rare lesion. Hunter Robb has described a myxosarcoma of the clitoris. Melanotic sarcoma of the vulva is an intensely malignant growth. Bailley reported a melanosarcoma in a woman, aged seventy-two years.

Recurrence is almost certain. Mueller removed from the labium minor a melanosarcoma as large as a walnut. There was no recurrence until the end of three years. Fisher reports a recovery in a woman, aged fifty-six years, from whom a melanosarcoma the size of a walnut was removed from the labium major.

CYSTS OF THE VULVA.

Cysts of the Bartholinean gland are by far the most frequent of the cysts of the vulva. They are not to be regarded as new formation, but rather as retention cysts. Gonorrhœa is the usual exciting cause, and hence they are inflammatory in origin. A diagnosis of gonorrhœal infection can be made to a moral certainty from the presence of a Bartholinean cyst. Both glands are commonly involved, but the lesion is seldom equally advanced on the two

sides. In the early stage of infection the openings of the glands are reddened, and it may be possible to express pus from the gland. As the infection extends into the glands they become swollen and tender, and if the outlet of the gland is occluded a retention cyst is formed. A chronically inflamed cyst may lie quiescent for an indefinite period, when through the influence of some mechanical insult or secondary infection an acute exacerbation occurs. As the gland distends the deep connective tissue is invaded. The infection may extend beyond the gland to the loose connective tissue between the rectum and vagina, and vagina and urethra.

The cyst wall is of fibrous tissue lined within by compressed epithelium. The wall is usually thin. The contents of the cyst are mostly of a thin, serous character, sometimes colloid, purulent, or of a dark red color from admixture with blood. In the contents may be found blood corpuscles, blood pigment, cholesterin, pus cells, leucocytes, epithelium, micro-organisms, and detritis. Veit reports three cases in virgins with an intact hymen, the probable result of a vulvovaginitis.

Retention cysts of the glands of Bartholin may be unnoticed by the patient or discovered accidentally. When there is an inflammatory reaction in and about the gland pain may be intense.

It is scarcely possible to confuse cysts of the glands of Bartholin with any other lesion. Inguinal hernia and cysts of the round ligament lie at a higher level and can be traced to the inguinal canal. Solid tumors of the labia majora may be excluded by an exploratory puncture or incision and by the inflammatory character of the growth.

Cysts of the labia minora are seldom reported. Agnes Bloom, in reporting two cases, gives the following classification :

1. Cysts arising from the normal structures of the labia minora (idiopathic).

2. Cysts arising from pathological conditions of the labia minora.

3. Cysts arising from Gärtner's ducts. While they are commonly quite small, they have been known to grow to the size of an orange. They are single or multiple, unilocular or multilocular. The contents vary, being serous, mucous, or purulent.

ULCERS OF THE VULVA.

Rodent Ulcer. Virchow was the first to describe this lesion. The ulcers present elevated, soft, œdematous margins; are very slow to heal, and tend to form fistulous communications with the vagina and rectum. When the ulcers invade the urethra strictures and fistulæ may follow. The ulcers grow to the size of a silver dollar. There is nothing characteristic in the microscopic findings. Giant cells suggestive of tuberculosis have been demonstrated.

The cause is unknown. That they bear no relation to tuberculosis and syphilis has been conclusively demonstrated. Koch is of the opinion that these ulcers arise from lymph stasis following suppuration and cicatricial contraction of the inguinal glands.

The diagnosis presents many difficulties. The lesion is often found in combination with elephantiasis, and by many is considered a part of this affection.

Tuberculous ulcers are distinguished by the presence of the tubercle bacillus. Carcinomatous ulcers are not easy to exclude. The microscopic examination is essential to a positive diagnosis.

Syphilitic ulcers are recognized by the history of infection, by the general evidence of syphilis which follows, and by the effect of treatment. The accompanying elephantiasis is suggestive of ulcus rodens.

PRURITUS VULVÆ.

Pruritus vulvæ is a term applied to an itching of the vulva accompanied by swelling of the parts and nervous irritability.

The most frequent area involved is the clitoris; next in order of frequency are the labia, vestibule, mons veneris, perineum, and anus.

In nearly every instance the lesion is symptomatic, but there is a small proportion of cases in which it appears to be idiopathic. As a symptomatic lesion the underlying causes are largely attributable to mechanical and infectious irritations of the vulva. As mechanical irritations, may be mentioned masturbation and excessive sexual intercourse, which may be the result as well as the cause of pruritus; also, the wearing of filthy pessaries, uncleanliness of the vulva, irritating urine in vesicovaginal fistulæ and diabetes, and the irritating discharge from malignant growths. Of the infectious agencies may be mentioned parasites, including the oidium albicans, pediculi, and intestinal worms. Any condition

bringing about passive congestion of the pelvis may cause pruritus vulvæ in the same manner as hemorrhoids cause pruritus ani.

It is certain that many of the pelvic lesions may reflexly cause itching of the vulva. Pruritus vulvæ associated with dryness and sensitiveness of the skin suggests the presence of kraurosis of the vulva. Disorders of the blood may account for some cases. Finally, a small number must be attributed to neurosis, though a mechanical cause is always to be sought.

The *diagnosis* of pruritus vulvæ may be made from the patient's complaint of itching, but it is most essential that the cause of the pruritus be determined by a general as well as local physical examination.

As a general proposition we may consider pruritus vulvæ a symptom of some general or local lesion. Every case of pruritus should suggest the possibility of diabetes, and should call for a urinalysis. The presence of irritating vaginal discharges, of worms, and of parasites are to be sought. The sexual habit of the patient should be a subject of inquiry.

The one dominating symptom is itching over part or all of the vulva. So distressing is this itching that the patient becomes irritable and nervous; she shuns society, and may even develop into a maniac or suicide. The itching is always worse at the menstrual period, during sexual intercourse, in warm weather, and after physical exertion.

Local changes in the skin surface of the vulva are commonly present and are largely due to scratching.

Webster and Sänger independently studied the histological changes of the skin removed from the affected area. Webster found the genital corpuscles of Krause in the clitoris, and called them tactile corpuscles. Nerve endings in the form of end bulbs were found in large numbers. A fibrosis of the corpuscles of Krause, the end bulbs, and nerves were found by Webster and confirmed by Sänger. There was a marked small round-cell infiltration in the subepithelial tissues and the superficial epithelium was largely removed.

THE HYMEN.

A physiological rupture and stretching of the hymen occurs from sexual intercourse and childbirth. It is possible for the hymen to be merely stretched in admitting the penis or in the passage of the child.

The lacerations occurring from the first coition are usually radial, and do not extend to the base of the hymen. It is possible for the hymen to be partly torn from its base without tearing its

FIG. 101.

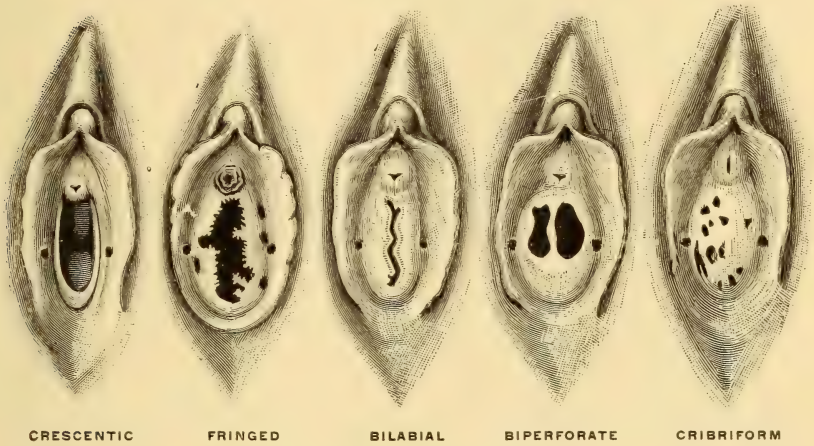

Different forms of hymen. (TESTUT.)

FIG. 102.

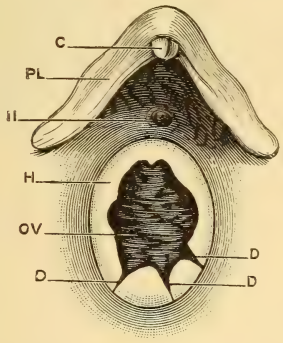

Hymen after coitus. (TESTUT.)

FIG. 103.

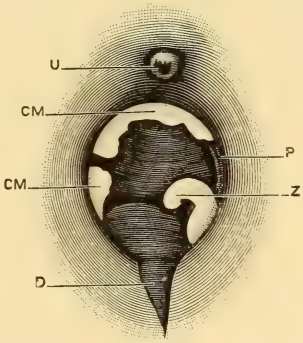

Hymen after parturition. (TESTUT.)

FIG. 102.—C. Clitoris. PL. Nymphæ. U. Meatus urinarius. OV. Vaginal orifice. H. Hymen. D. Rent in hymen.

FIG. 103.—U. Meatus urinarius. P. Nympha. CM. Carunculæ myrtiformes. Z. Portion of hymen, detached and floating. D. A tear through the fourchette.

free margin. As a rule, there is a circular opening. After childbirth the hymen is completely severed in many places, leaving isolated tags (carunculæ myrtiformes). These lacerations often extend into the vagina and perineum.

The question of the existence or absence of a hymen is of medico-legal importance. It is self-evident that the hymen is not a reliable guide in judging virginity. The hymen may be present and intact after sexual intercourse and even after childbirth; while, on the other hand, it may be totally wanting or but partially developed in virgins. It is possible for a lacerated hymen to heal so perfectly that no evidence of a previous laceration is visible.

CYSTS OF THE HYMEN.

Little is known of cysts of the hymen. Wenkel made the first report in 1883. Palm describes a cyst of the hymen measuring 8 cm. in diameter. The average diameter is about 1 cm. Many do not exceed 1 mm. in diameter. They are usually congenital, though they may not be observed until late years. One or more cysts are located near the free margin of the hymen.

These various sources explain the presence of a variety of epithelium lining the cyst cavity. As a rule, the epithelium is squamous and stratified, but is occasionally cylindrical, and in a few instances endothelium is found.

The origin of the cysts of the hymen is in many cases the epithelial projections. These projections become constricted off, and form an epithelial wall of a space which fills with serum. A few cases apparently arise from Gärtner's duct, from dilated lymph spaces, and from retention of the secretions of sebaceous glands.

CHAPTER XXIII.

THE DIAGNOSIS OF DISEASES OF THE VAGINA.

MALDEVELOPMENTS AND MALFORMATIONS.

INASMUCH as the vagina is partly developed from the ducts of Müller, developmental failures, analogous to those found in the uterus and tubes, are to be found in the vagina. There may be a complete absence or a partial development of the vagina; the ducts of Müller may fail to coalesce, giving rise to a double vagina; the ducts of Müller may coalesce, but fail to be absorbed, leaving a partial or complete septum, dividing the vagina in the median line.

Absence of the vagina may result either from a failure of the ducts of Müller to develop or from complete atresia. As a rule, the entire Müllerian tract fails to develop, hence the absence of the vagina, uterus, and tubes. The appearance of the external organs of generation may be misleading in determining the sex.

Atresia and Stenosis of the Vagina. As a rule, atresia of the vagina is incomplete. It is usually the lower segment that is closed. In extreme cases only a fibrous or fibromuscular band is found between the bladder and rectum. Back of the obstruction the menstrual blood collects in the vagina (hæmatocolpos); in the uterus (hæmatometra); in the tubes (hæmatosalpinx), and, finally, in the pelvis (hæmatocele).

The obstructing tissue may be stretched and crowded down, appearing at the vulvar outlet as a dark bluish-red membrane. The retained blood does not usually coagulate, but becomes dark in color.

Etiology. Atresia of the vagina may be congenital or acquired. It may be difficult to determine whether the malformation developed in intra-uterine or in extra-uterine life. In very young infants a vaginitis may form adhesions of the vaginal surfaces without giving rise to symptoms. Whether a fœtal vaginitis can account for congenital atresia of the vagina has not been demonstrated.

The usual cause of stenosis and atresia of the vagina occurring during the period of sexual maturity is trauma incident to labor.

FIG. 104.

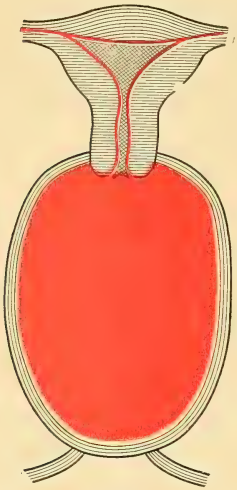

FIG. 105.

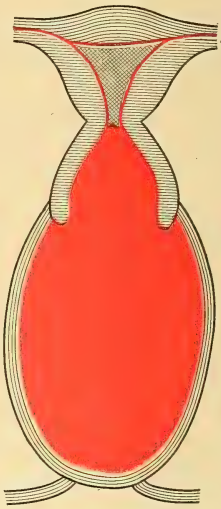

FIG. 104.—Atresia at the vulva first causes distention of the vagina, producing hæmatocolpos. (SUTTON and GILES.)

FIG. 105.—Atresia at the vulva. Hæmatotrachelos has followed hæmatocolpos. (SUTTON and GILES.)

FIG. 106.

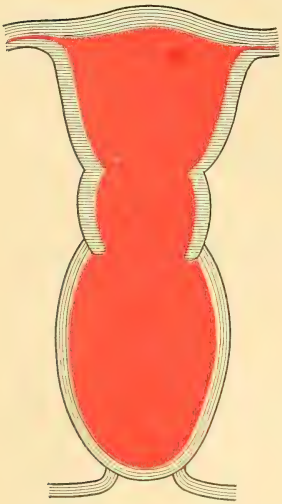

FIG. 107.

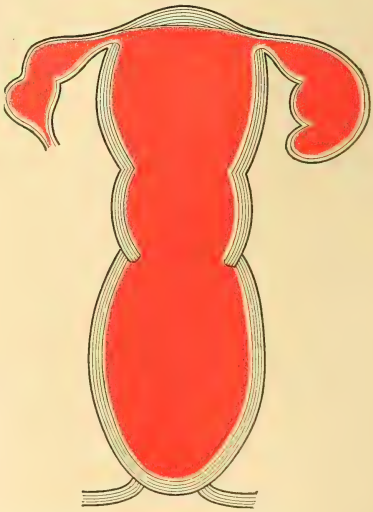

FIG. 106.—Atresia at the vulva has caused hæmatocolpos, then hæmatotrachelos, and then hæmatometra. (SUTTON and GILES.)

FIG. 107.—Atresia at the vulva. In addition to the conditions in Fig. 106, there is added hæmatosalpinx. (SUTTON and GILES.)

In the postclimacteric stage an adhesive vaginitis may narrow or obliterate the vagina. Gonorrhœa is the usual underlying cause of senile vaginitis. In congenital atresia the obstruction is most often at the junction of the middle and upper third of the vagina, which is the lower limit of the Müllerian ducts. In the acquired form the obstruction is usually similarly situated.

The obstruction may be merely a half moon or annular ring, a partial or complete septum with perforations, or a membrane varying in thickness even to filling the vagina completely. Two, three, and even four atresic points have been described.

Fig. 108. Fig. 109. Fig. 110.

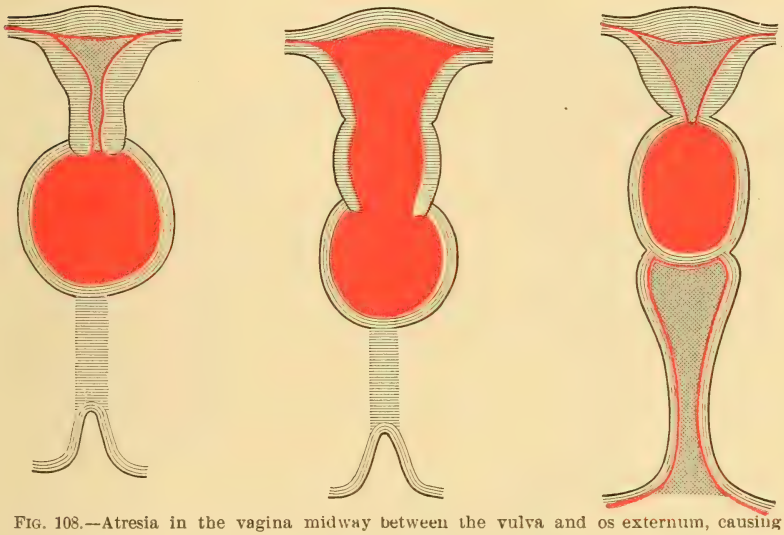

Fig. 108.—Atresia in the vagina midway between the vulva and os externum, causing hæmatocolpos in the upper half of the vagina. (Sutton and Giles.)

Fig. 109.—Same as in Fig. 108, except that distention of the whole uterus has followed the partial hæmatocolpos. (Sutton and Giles.)

Fig. 110.—Atresia at the os externum, producing a hæmatotrachelos. Corpus uteri not yet distended. (Sutton and Giles.)

The *diagnosis* of stenosis and atresia of the vagina should present few difficulties. When a girl at the time of puberty fails to menstruate, but suffers from pain in the pelvis, which increases in severity at the time of each monthly period, atresia of the vagina or cervix is suspected. If, in addition, a pelvic tumor develops and distinctly fluctuates, the diagnosis is highly probable, but must be confirmed by a vaginal examination. Vicarious menstruation rarely occurs. In an attempt to make a digital examination of the

vagina the finger will meet the obstruction. The extent of the closure is best determined by the finger in the rectum. If the obstruction lies high in the vagina and does not bulge downward it is not likely that there is any considerable secretion pent up above the point of obstruction.

Hæmatometra is not easy to demonstrate, because of the difficulty in palpating the elevated uterus through the rectum. The uterus usually lies near the median line, and is rounded, tense, possibly fluctuating, and somewhat increased in size.

FIG. 111.

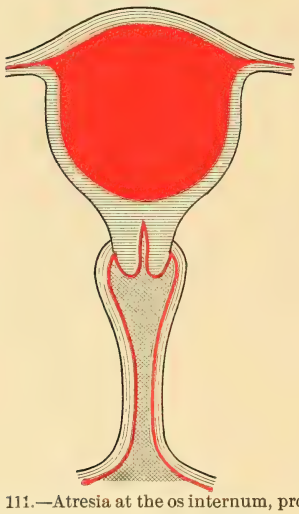

FIG. 112.

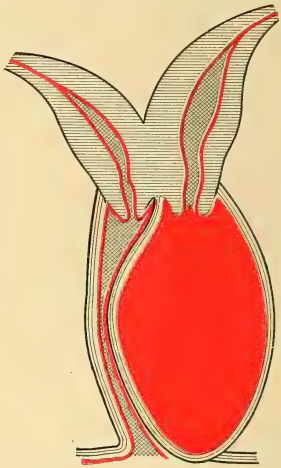

FIG. 111.—Atresia at the os internum, producing hæmatometra. Fallopian tubes may become distended later. (SUTTON and GILES.)

FIG. 112.—Atresia at the vulva on one side of a double uterus and vagina, causing hæmatocolpos on the affected side. (SUTTON and GILES.)

Double vagina is the result of failure on the part of the Müllerian ducts to perfectly fuse. From this cause a septum divides the vagina in part or throughout. The vaginal canals usually lie side by side, the septum running antero-posterior. The canals may be unequal in size. The septum rarely runs transversely, so dividing the vagina that one lies in front of the other—this can only be accounted for on the supposition that the Müllerian ducts had rotated prior to their fusion. All degrees of development may be observed in the septum, from a slight ridge to a complete partition composed of fibrous tissue, mingled with some muscle fibres and covered on either side with mucous membrane. The cervix and uterine body are usually divided.

If both canals are pervious no symptoms need arise until labor, when there may be an obstruction to the passage of the child.

VAGINITIS (Colpitis).

Vaginitis rarely exists singly. As a rule, it is associated with vulvitis and endometritis, and not infrequently with a similar involvement of the entire genital tract.

Etiology. With few exceptions vaginitis is due to bacterial invasion. Mechanical and thermic irritants are accountable for a small number of cases.

Of the micro-organisms causing vaginitis the gonococcus is by far the most frequent. A purulent discharge from the cervix containing the gonococcus may fail to infect the vagina because of the protecting epithelium, which, when intact, resists all bacterial invasion.

If, however, the epithelium of the vagina is lost or its vitality is lowered infection will follow. We, therefore, find primary gonorrhœal vaginitis less frequently in the young than in advanced years, when the epithelium has lost its full power of resistance and is more or less desquamated. Repeated attacks of vaginitis may result from contamination by the secretions of the uterus, tubes, and urethra.

Injudicious exercise and sexual excesses may be the explanation of exacerbations.

Puerperal vaginitis is nearly always caused by the staphylococcus and streptococcus. The Klebs-Loeffler bacillus is rarely the cause of vaginitis. The streptococcus of erysipelas is occasionally found, particularly in infants. The presence of the oidium albicans and leptothrix has been demonstrated. Entozoa can invade the vagina from the rectum. Ascarides and similar parasites of the intestines may invade the vagina and set up a vaginitis.

Infections from the bowel, as from dysentery and typhoid fever, may invade the vagina. Infection may also travel from the bladder to the bowel. An irritating and infectious discharge from the uterus or from a pelvic abscess opening into the vagina will infect the vagina. It is highly probable that maceration of the epithelium by fluids used in douching favors infection from such discharges.

The secretions from malignant growths of the uterus are particularly irritating to the vaginal mucosa.

Trauma from ill-fitting and foul pessaries, from tampons saturated with irritating secretions, and from masturbation predisposes to infection.

Shultze has correctly claimed that decomposition of stagnated menstrual blood behind the hymen in chlorotic girls is not infrequently a cause of vaginitis.

Tumors lying within the vagina may act as mechanical irritants to the vaginal mucosa.

Anatomical Diagnosis. The following morphological forms are recognized:

1. **Catarrhal vaginitis** is recognized by a reddening, swelling, and increased secretion of the vaginal mucous membrane. These changes are proportional to the degree of acuteness and intensity of the infection. The surface is rarely uniformly red, but rather mottled red and gray. In the chronic stage slight reddish elevations stud the surface. These elevations are particularly prominent in old age, when contrasted with the smooth, pale gray background.

The microscope shows a diffuse round-cell infiltration, and capillary congestion of the subepithelial connective tissue. There may be more or less desquamation of the surface epithelium. The deep layers of connective tissue are rarely involved. In the senile variety punctate hemorrhages are particularly liable to occur in the connective tissue. Gebhard speaks of a variety called croupous vaginitis, in which there is formed on the surface a false membrane composed of fibrin, leucocytes, desquamated and degenerated epithelium. He observes that a similar lesion is often found in the bowel, and reasons that there is a specific cause underlying both conditions.

2. **Ulcerative Vaginitis.** It is possible for ulcers to develop in the advanced stage of catarrhal vaginitis; this, however, is exceptional. The loss of epithelium is usually superficial, and in healing does not lead to cicatrization.

a. Puerperal ulcers of the vagina arise from infection of abrasions and lacerations acquired in labor. A diphtheritic membrane of a gray or yellowish-gray color forms over the ulcerated surface. The lesion may extend deeply into the vaginal wall and into the paravaginal connective tissue. Pelvic abscesses and suppurative peritonitis may follow from extension of the infection. A diffuse tumefaction and reddening of the vaginal mucous membrane may extend from the ulcers, giving the appearance of erysipelas.

Stenosis and atresia of the vagina may follow healing by cicatrization, particularly when the paravaginal tissues are involved.

b. True diphtheritic ulcers of the vagina, in which the Klebs-Loeffler bacillus appears, is a rare finding, and almost always develops during the puerperium.

c. Tuberculous ulcers of the vagina are of rare occurrence. Such ulcers are shallow, with irregular undermined margins. The base and margins are studded with miliary tubercles, in which the tubercle bacillus may be demonstrated.

d. Syphilitic ulcers in the primary stage with elevated indurated margins are more common than those of the secondary or tertiary stage.

Ulcers of the vagina complicating the infectious diseases, as, for instance, typhoid fever and smallpox, are occasionally seen.

e. Decubitus ulcers arising from pressure by foreign bodies in the vagina show great variation in extent and form. The common cause of decubitus ulcers is the wearing of ill-fitting pessaries, which, through pressure, causes a superficial slough of the mucosa. The necrosis may extend deep into the tissues and result in the development of a vesicovaginal fistula. Such ulcers may attain the size of a saucer.

3. **Tuberculous Vaginitis.** But one case of primary tuberculosis of the vagina has been reported (Friedländer). The usual tuberculous lesions are found—that is to say, local or general dissemination of tubercles, larger tuberculous nodules, and caseous masses with ulcers.

The microscope reveals the usual structure of tubercles: giant cells, small round cells, endothelioid cells, and tubercle bacilli.

By far the greater number are secondary to tuberculosis of the uterus, tubes, vulva, cervix, rectum, and bladder. The lesion may very rarely be conveyed by the blood. Primary infection may be acquired by direct infection from the husband and from the examining finger and instruments.

4. **Emphysema vaginæ** (colpitis emphysematous). As the result of some sort of an infection numerous small cysts filled with gas are found in the subepithelial connective tissue. The lesion usually appears in pregnancy and the puerperium. As a rule, the cysts disappear within three months after labor.

Wenkel first described them as retention cysts formed from vaginal glands. Zweifel first demonstrated them to be the result of fermentation. Eisenlohr proved the presence of gasogenic bacteria

in the connective tissue spaces of the submucosa and of the lymph spaces. There can be no doubt as to the microbic origin of the lesion.

Through a speculum the vesicles appear dark, bluish-red in color. Pressure causes them to temporarily disappear. If the vagina is partly filled with clear fluid and the vesicles punctured with a needle, gas will escape in bubbles.

5. **Condylomatous Vaginitis.** Groups of warty excrescences are found in the vagina as further extension of a similar growth of the vulva. The whole vaginal surface may be covered with the warty growth.

Clinical Diagnosis. In all forms of vaginitis there is an excessive secretion, varying in quantity and character. The secretion is derived in part from the uterus and cervix. It is serous, mucous, or purulent. This so-called leucorrhœa ("whites") is usually the first symptom. Following this is itching and burning, which is aggravated by exercise. When caused by gonorrhœa these symptoms may appear within twenty-four hours from the time of the infection. In addition to the above symptoms there is usually burning and smarting on urinating, caused by a urethritis.

When pus can be expressed from the urethra the diagnosis of gonorrhœa is made with reasonable certainty. If in addition the Bartholinean glands are infected, there can be little doubt as to the gonorrhœal origin of the lesion.

Vesical and rectal tenesmus are present in the acute stage. In the mild forms and in the chronic stage the patient may not complain.

The diagnosis has to do, first, with the recognition of the vaginitis; next, with the possible extension of the lesion to neighboring structures; and, finally, with the underlying cause of the infection.

Direct inspection should determine the presence of vaginitis. The Sims speculum should be used with the patient in the Sims position. There is more or less sensitiveness to the touch of the examining finger, and a roughness of the surface may be detected.

The recognition of extension to the upper genital tract involves the diagnosis of endometritis and salpingitis. To determine whether the secretion is from the vagina or from the uterus the Shultze method is employed. The vagina is cleansed with a douche of sterile water, a plug of sterile cotton is placed against the cervix, and after remaining there several hours it is removed. If the secre-

tion is collected on the top of the plug, the discharge comes from the uterus; if it collects around the plug, the discharge is from the vagina.

Recognition of the cause of the infection is not always possible. Gonorrhœa is so frequently the cause that it must first be excluded before considering other possible causes. In the acute stage the gonococcus can usually be found in the secretion, but not often in the chronic stage. When beginning a few days after marriage and associated with burning on urinating, it is highly probable that gonorrhœa is the underlying cause.

PARAVAGINITIS.

By paravaginitis is understood an inflammation involving the connective tissue immediately surrounding the vagina. As a rule, it is a staphylococcus infection leading to the formation of localized abscesses. Other possible causes are wound infections following operations and attempts to induce abortion; ill-fitting pessaries, which have ulcerated through the vaginal wall; infectious diseases, such as dysentery and typhoid fever, where the infection is conveyed through the bowel or bladder into the paravaginal connective tissue, and in all inflammatory diseases of the rectum and bladder extending to the vagina.

Veit describes a peculiar form which he designates as *paravaginitis phlegmonosa dessecans.* But few cases have been recorded. One was ascribed to gonorrhœa; others may have been due to criminal abortion, and in two instances no cause was assigned. Undoubtedly the lesion may arise as a complication of contagious and infectious diseases. Cicatricial contraction of the vagina is the final result.

NEW FORMATIONS OF THE VAGINA.

Cysts of the Vagina. Cysts of the vagina are not of great rarity. Nengebauer found thirty-six cases in 600 observations.

Histogenesis. The fact that the epithelial lining of the cysts varies in form suggests various origins. Veit believed them to develop from remains of the Wolffian ducts. The ducts of Gärtner do not ordinarily extend below the vault of the vagina, but instances are known in which they extended as far as the urethral opening along the lateral and anterior walls of the vagina. In

these ducts muscle fibres and cylindrical epithelium are observed, and so it is that cysts located in the sides or in the anterior wall of the vagina and containing muscle fibres and epithelium are assumed to arise from the ducts of Gärtner. As further evidence of this origin, may be mentioned their occasional elongated form with their long axis in a line corresponding to the long axis of the vagina. Still more significant is the rosary-like arrangement of two or more cysts along the line of Gärtner's duct.

Preuschen suggests that the origin of vaginal cysts may be the glands of the vagina. Cysts lying in the posterior wall of the vagina are thus explained. They are regarded as retention cysts. Davidson holds that the glands of the vagina are purely misdevelopments. Those in the upper segment of the vagina are misplaced from the cervix and maintain the character of cervical glands, while those in the lower segment of the vagina are from the vulva. Retention cysts arising from these glands are usually multiple, of small size, and lined with a single layer of columnar epithelium. Cysts may arise from partial adhesion of the folds of vaginal mucous membrane enclosing spaces lined with flat epithelium.

Freund believes that cysts of the vagina arise from rudimentary ducts of Müller. Furthermore, it is apparent that the lymph spaces may distend into cysts lined by endothelium.

Cysts of the vagina are rarely of large size, ranging from that of a pinhead to a hazelnut. In exceptional cases they are found the size of a child's head. They are slow in growth. The sites of election are the anterior and lateral walls, rarely the posterior wall of the vagina. They lie immediately underneath the epithelium, and bulge into the vagina. The consistency is elastic; the contents clear, watery, or mucoid. Occasionally the contents are milky from the presence of degenerated epithelium; sometimes chocolate color from admixture with blood. Cheron reports the presence of a stone in the cysts. Cholesterin crystals are occasionally found. As a rule, the cysts are simple, but they may be multilocular. The cyst wall is composed of fibrous tissues, occasionally mingled with some muscle fibres. The inner surface is lined with a single layer of cylindrical epithelium, sometimes with several layers of cylindrical or flat epithelium; rarely are endothelial cells found.

They are seldom of clinical interest, but are known to interfere with sexual intercourse and with childbirth.

FIBROMYOMA OF THE VAGINA.

Richard R. Smith collected 101 cases from the literature. They commonly occur between the ages of twenty and forty years, and have been observed as early as one and one-half years and as late as seventy-eight years. The largest one recorded weighed ten pounds. They are usually round and attached by a broad base or pedicle. The surface is smooth or nodular, and is covered with vaginal mucous membrane. They are seldom of soft consistency. Their origin is in the submucous connective tissue. They are rarely multiple, and are most often located in the anterior wall of the vagina. The usual forms of degeneration common to fibroids are possible.

The diagnosis is not difficult. A soft fibroid might be mistaken for a cyst, a cystocele, or a rectocele. The bluish, semitransparent color of the cyst is of special significance.

CARCINOMA OF THE VAGINA.

Etiology. Less than 1 per cent. of all cancers in women are of vaginal origin (Williams, Bristol). Küstner collected twenty-two cases of primary cancer of the vagina, and estimates that about 0.02 per cent. of cancers of the genital tract arise primarily in the vagina.

As a rule, primary carcinoma of the vagina arises between the ages of fifty and sixty ; two cases are reported at twenty years of age. Childbearing does not influence the development of the growth, and heredity plays a minor rôle. A number of cases have been recorded where ill-fitting pessaries have caused ulceration and eventually malignant degeneration. Prolapse of the vaginal walls subjects the vagina to mechanical insults, and upon the injured surface may be engrafted a carcinoma.

Anatomical Diagnosis. In 123 cases 71 were found on the posterior vaginal wall, 13 on the lateral walls, and 16 were annular. The growth may be papillary, nodular, or infiltrating. To the unassisted eye cancer of the vagina usually presents a thickened, ulcerated area. The margins are irregular, hard, and elevated. The base of the ulcer is uneven, bleeds freely on handling, and is covered with a foul-smelling secretion. Surrounding the vagina

the tissues show an inflammatory reaction, and secondary nodules may be seen distributed over the surface. Rarely does the growth attain the size of a man's fist. Extension into the paravaginal tissue is rapid. Reaching the lymph spaces of the connective tissue, the cancer cells are rapidly carried to the retroperitoneal glands. The inguinal glands are enlarged when the lower segment of the

Fig. 113.

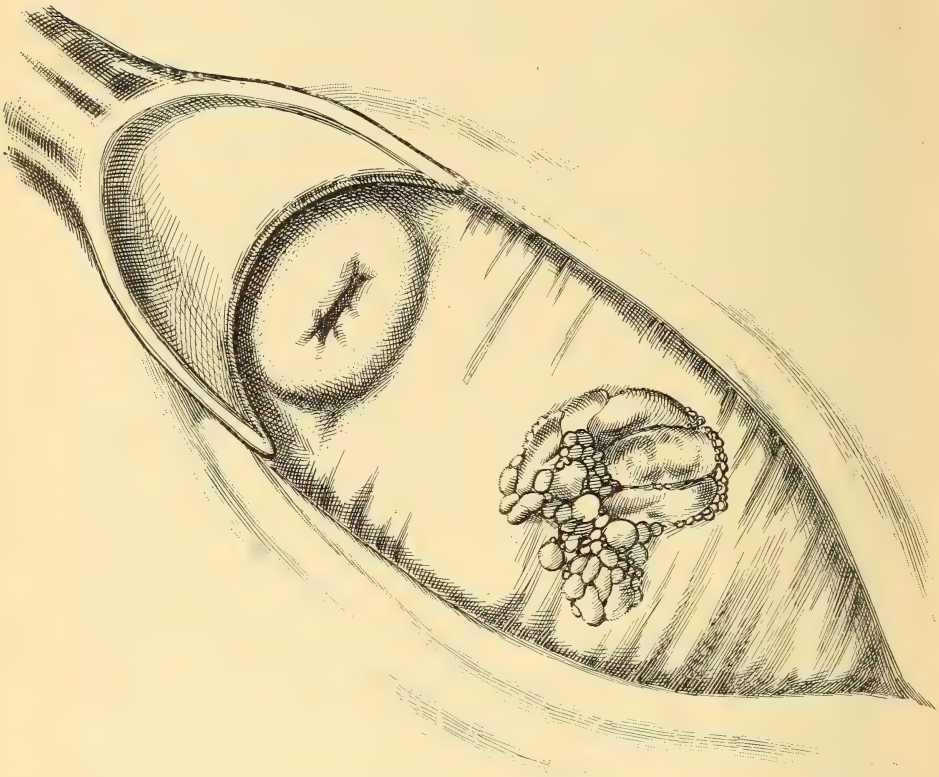

Carcinoma of vaginal wall. (Dudley.)

vagina is invaded. As a rule, the uterus is not invaded so early as the vulva, and metastasis to distant organs is late. The microscope shows nothing unusual. It is a flat-cell growth, the cells are arranged in nests, and contain many pearls.

Clinical Diagnosis. The lesion may go unrecognized until far advanced. As with cancer of the uterus, all symptoms may be wanting until there is ulceration and sloughing of the growth.

Hemorrhage, pain, and a foul-smelling discharge are the cardinal symptoms, but in no way do they differ from the same group found in cancer of the vulva or uterus. Pain is rarely present until the growth has extended into the paravaginal tissue. All observers have noted the absence of pain in the early stage.

Stenosis of the vagina may hide a growth lying above the point of constriction, and render the early diagnosis very difficult.

Secondary cancer of the vagina is of frequent occurrence. Cancer of the cervix is especially liable to extend to the vagina, and normal tissue may intervene between the primary growth in the cervix and the secondary growths in the vagina. Cancer of the bladder and rectum more rarely invade the vagina. Metastatic growths from the ovary are seldom found in the vagina.

Wahn, Fisher, and Kalkenbach report implantation of cancer cells upon eroded surfaces in the vagina through the medium of a leucorrhœal discharge. The secondary growths take the same histological forms as the primary growth.

The average duration of primary cancer of the vagina is said to be sixteen months, but may last several years.

Differential Diagnosis. **Decubitus ulcers** caused by ill-fitting pessaries may be mistaken for carcinoma, and have known to be its starting-point. The hard, elevated margins friable, and bleeding when handled, are distinctive of malignancy. Where doubt exists a microscopic examination of an excised piece, or a scraping from the suspected portion, will determine the diagnosis.

Syphilitic and tuberculous ulcers of the vagina are recognized by the clinical history, by evidences of lesions elsewhere in the body, and by microscopic examination of excised pieces. Friability and bleeding of the suspected tissue are suggestive of carcinoma.

SARCOMA OF THE VAGINA.

Sarcoma of the vagina is found in all ages, from the first to the eighty-second year. Six so-called congenital cases are reported. Of forty cases reported by Williams, thirty-six occurred before fifteen years of age.

The growth is usually polypoid, of a yellowish-gray or chocolate color. Rarely is there a diffuse infiltration of the vaginal walls. The surrounding structures are early invaded. Distant metastasis is late, and often does not occur. There is a tendency to early

necrosis of the tumor mass, together with infection of the necrotic mass by pyogenic micro-organisms leading to cystitis, pyonephritis, and peritonitis. Late in life sarcoma is usually smooth rather than rough and polypoid as in early life.

Histologically, the growth is demonstrated to be a fibrosarcoma, myxosarcoma, round-cell or spindle-cell sarcoma, or, finally, a melanosarcoma.

The diagnosis of sarcoma apart from carcinoma cannot be made without the aid of the microscope.

SYNCYTIOMA VAGINÆ.

Syncytioma malignum (or, as better named, chorio-epithelioma malignum) occurs with relative frequency as a secondary growth in the vagina.

Schmidt lately reported two cases of primary growths in the vagina. In both cases the uterus remained perfectly normal.

I am indebted to Dr. Frank Pierce for the microscopic section from which Plate XXXII. was drawn.

All new-growths of the vagina developing weeks and months after labor should be excised and examined, with special regard for malignant proliferation of the syncytium.

To the unaided eye the tumor is usually round and elevated. It is of a bluish color. Ulceration is rare. On cross-section the tumor is exceedingly bloody, and may resemble a blood clot.

ENDOTHELIOMA OF THE VAGINA.

Endothelioma of the vagina is an exceptional growth. The first case was reported by Klein. By the naked eye the growth cannot be distinguished from a carcinoma. Microscopically the tumor is found to be composed of cells resembling flat epithelium arranged in a thick meshwork of connective tissue. The cells arise from the endothelium of the blood or lymph spaces. In distribution they resemble veins of marble.

PLATE XXXII.

Chorio-epithelioma Malignum of the Vagina.

A nodule appeared in the wall of the vagina several months after an apparently normal labor. The case was reported by Schmidt, of Vienna. The accompanying illustration was drawn from a section of the nodule loaned from the collection of Dr. Frank D. Pierce. It represents a covering of normal stratified squamous epithelium. Beneath this is a variable thickness of connective tissue overlying a large clot of blood in which are seen two villous stems covered by proliferating syncytium. Syncytial cells are seen to invade the blood clot.

CHAPTER XXIV.

ENDOMETRITIS.

MATTHEWS DUNCAN once said in a lecture: "Who can tell what any one means by endometritis? Often its use is the parent or child of ignorance and confusion; often it is the cloak of confusion." There is yet to be proposed an exact and practical classification of endometritis. In the light of our present knowledge we are unable to harmonize our clinical, macroscopic, and microscopic forms of endometritis. In making a diagnosis from prominent symptoms and evident etiological factors we are unable to foretell the naked eye and microscopic findings. One and all of the pathological forms of endometritis may exist without clinical signs. On the other hand, any of the pathological lesions of the endometrium may give the same clinical manifestations as endometritis. Furthermore, these symptoms may be present in the absence of an evident pathological change in the endometrium.

It is evident that a clinical classification cannot be universally applied. While appropriate to the majority of cases, there will be a minority which can only be recognized by direct examination of the endometrium with the naked eye or with the microscope. Indeed, it not infrequently occurs that the absolute diagnosis is reserved for a microscopic examination of scrapings removed by the curette. In view of what has been said there will be given both a clinical and an anatomical classification.

Clinical Classification. Endometritis may be acute or chronic. The distinction between these forms is usually not difficult to make.

1. **Acute Endometritis.** In acute infections of the endometrium the constitutional disturbances may be mild or severe. Fever may exist, but is not always proportionate to the extent and intensity of the inflammation. The pulse rate corresponds to the degree of general intoxication, and is to be regarded as a more reliable indication of systemic infection than is the temperature. The menses are lessened or suppressed. The uterine discharge is at first serous,

later seropurulent. There is backache, nausea, a sense of weight in the pelvis, rectal and vesical tenesmus, and pain in the hypogastrium. Bimanual examination reveals a uterus tender to pressure, not perceptibly increased in size, and perfectly movable. The external os may be slightly patulous and softer than is normal. Inspection through the speculum shows a congestion of the cervix which is particularly evident at the external os. From the cervical canal flows a seropurulent or mucopurulent secretion, rarely it is clear serous or mucous. A sound introduced into the uterus would cause some pain and bleeding, and should not be used.

2. **Chronic Endometritis.** For practical clinical purposes we will adopt a classification of endometritis based upon the prominent clinical symptoms—hemorrhage, leucorrhœa, and pain, and will speak of hemorrhagic, catarrhal, and dysmenorrhœic endometritis.

Clinical Forms of Chronic Endometritis. 1. **Hemorrhagic endometritis** is characterized by an unusual loss of blood during and sometimes between the menstrual periods. Inasmuch as the normal limits of menstruation vary widely, it is difficult to fix the exact limitations of the normal and the abnormal flow of blood.

The normal limits in time may be fixed from two to eight days; a flow continuing longer than eight days may be regarded as pathological. The average normal quantity of menstrual blood is six to eight ounces. Intermenstrual bleeding is always pathological and demands careful inquiry into the cause. It is unusual for endometritis to cause intermenstrual bleeding. Physical exertion may excite hemorrhage, but the loss of blood is never considerable. In hemorrhagic endometritis, leucorrhœa and pain may be present, but are symptoms of less prominence than is the hemorrhage.

2. **Catarrhal endometritis** is characterized by an excessive serous or seropurulent discharge from the uterus. The amount of secretion is not proportionate to the extent and degree of inflammatory change found in the endometrium. If mucus is found in the secretions the cervix is involved, there being no mucous secretion from the body of the uterus.

To differentiate a uterine discharge from the secretions of the vulva and vagina the Shultze method should be adopted. (See page 228.)

Not infrequently women complain of a leucorrhœal discharge during pregnancy, and immediately preceding and following the

menstrual flow. Such are within normal limits, and are to be regarded as hypersecretions of the congested uterus, vagina, and vulva.

The most excessive discharge is found in gonorrhœal endometritis. Nothing can be ascertained respecting the essential cause of the infection from the macroscopic appearance of the discharge. Cover-slip preparations may contain the gonococcus.

3. **Dysmenorrhœic endometritis** is characterized by painful menstruation. Pain is little to be relied upon in the diagnosis of endometritis. The diagnosis is arrived at by excluding all other possible causes of pain. The pain of endometritis is described as being of a cramping, bearing-down character, and associated with a feeling of weight in the pelvis. However, there is nothing characteristic in the pain. More often it is caused by such complicating lesions as salpingitis, ovaritis, and perimetritis.

While the above-named symptoms—hemorrhage, leucorrhœa, and pain—are commonly present in endometritis, and while one of the three symptoms usually dominates and justifies the terms as given above, it is not uncommon for endometritis to give rise to no symptoms. Furthermore, carcinoma, sarcoma, submucous polyps, and retained placental tissue may closely simulate endometritis in their clinical manifestations.

In addition to the above clinical forms of endometritis may be mentioned several varieties which are not only hemorrhagic, catarrhal, or dysmenorrhœic, but are deserving of special designation because of some point of interest relating to their etiology, time, and manner of occurrence. The following forms are ordinarily recognized :

Tuberculous endometritis often follows a primary infection of the tubes. Where tuberculous salpingitis is recognized, and there develops a catarrhal discharge from the uterus, the extension of the tuberculous process to the endometrium is suspected. Cover-slip preparations should be taken from the secretions and an exploratory curettage may be made, with the view of finding giant cells, tubercles, and the tubercle bacillus in the scrapings.

Gonorrhœal endometritis can be recognized with absolute certainty only by finding the gonococcus in the catarrhal secretion. It is not always possible to demonstrate the presence of the gonococcus in the secretions; this is particularly true of the long-standing cases. When a leucorrhœal discharge appears shortly after mar-

riage, and when in addition to leucorrhœa there is burning on urinating and infection of the urethra and glands of Bartholin, little doubt can be entertained as to the nature of the infection. No other form of endometritis causes such profuse discharge.

Decidual endometritis is a term applied to the inflammation of the endometrium of pregnancy. The lesion can only be suspected during pregnancy. A positive diagnosis is made by a microscopic examination of the decidua after the expulsion of the fœtus.

FIG. 114.

Uterus from patient dying on tenth day from a mixed infection—streptococcus and colon bacilli. (JEWETT.)

Gonorrhœa is the usual cause. The symptoms are hemorrhage, which varies in amount and may continue throughout pregnancy; leucorrhœa of a serous character, sometimes known as hydrorrhœa gravidarum; and pain of a cramping or bearing-down character. Decidual endometritis may arise previous to pregnancy and is one of the potent causes of abortion.

Puerperal endometritis occurs in the puerperium as the result of instrumental or digital infection. It is not infrequently of gonorrhœal origin.

PLATE XXXIII.

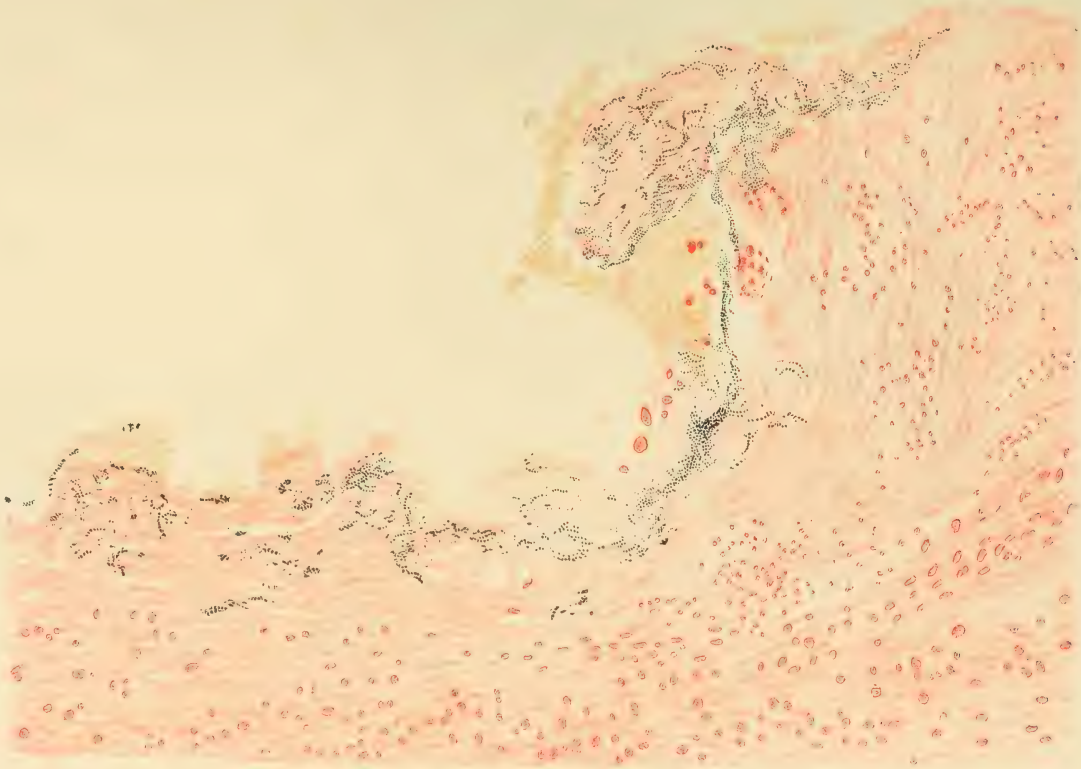

Section through decidua and uterine wall, showing streptococci. (Doederlein.)

Postabortive endometritis follows abortions usually as the result of instrumental or digital infection.

Exfoliative endometritis (membranous dysmenorrhœa) is recognized clinically by the periodic expulsion of a membrane from the uterus, either as a cast of the uterus or in the form of shreds. Expulsion of the membrane is accompanied by severe pain. For differentiation of this from other discharged membranes, see page 121.

FIG. 115.

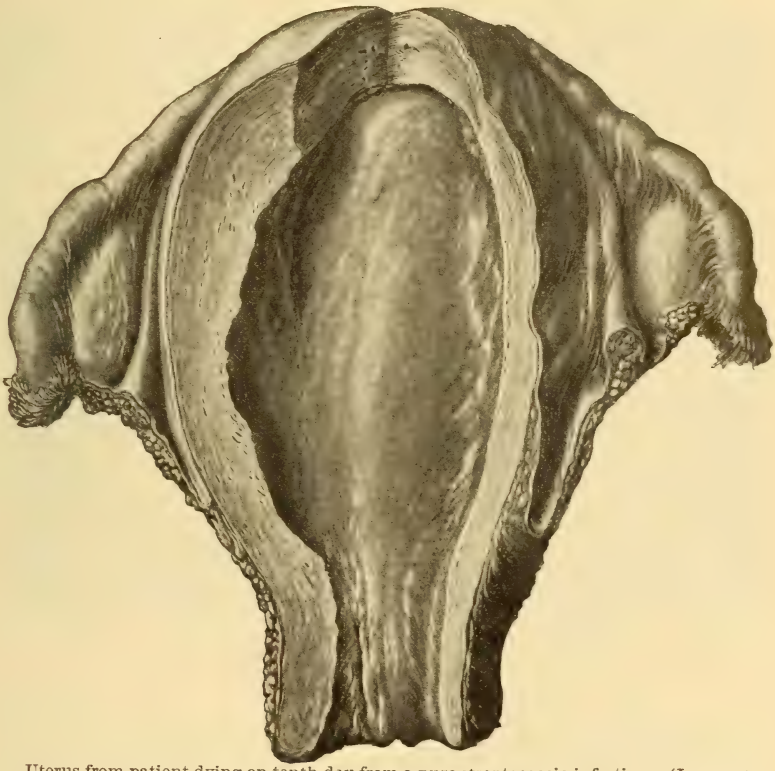

Uterus from patient dying on tenth day from a pure streptococcic infection. (JEWETT.)

Senile endometritis, as the name implies, occurs in advanced years, and in its clinical manifestations (hemorrhage, leucorrhœa, and pain) may very closely simulate carcinoma. There is no satisfactory explanation of the etiology of senile endometritis.

Fungous endometritis (Olshausen) differs clinically from other forms by the presence of severe hemorrhage, and the absence of pain and usually of leucorrhœa.

While the above forms are commonly recognized without difficulty, there is a minority of cases in which endometritis is only distinguished by anatomical (gross and microscopic) observations. It is evident that an additional classification based upon anatomical findings will serve where the clinical signs fail.

Anatomical Classification. A variety of forms of endometritis is recognized by the microscope and the unaided eye.

Fig. 116.

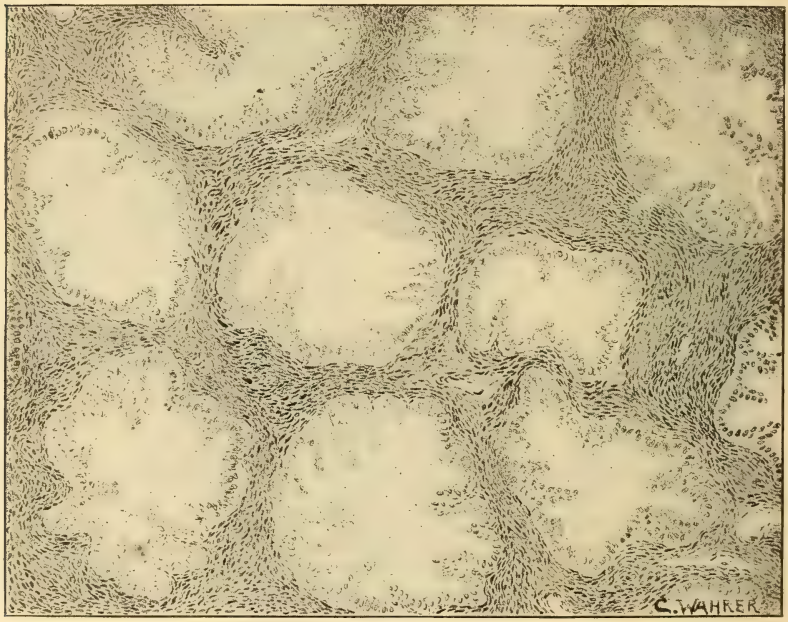

The endometrium is thickened, soft, and folded. In the cervix are several distended glands, forming a cystic protrusion.

I. **Macroscopic forms of endometritis** are diagnosed after the uterus is removed and opened. Such findings may be wholly unsuspected in the absence of all clinical symptoms of endometritis. The following forms are recognized by the unaided eye:

a. **Hypertrophic endometritis,** in which the endometrium is thickened and soft.

b. **Fungous endometritis,** in which the endometrium is thrown into folds and fungosities.

c. **Villous endometritis,** in which the surface of the endometrium is covered with shaggy villosities.

d. **Polypoid endometritis,** in which one or more mucous polyps project from the endometrium.

e. **Ulcerative endometritis,** in which true ulcers are formed in the endometrium. These ulcers show either a virulent form of infection or malignant degeneration.

f. **Pseudodiphtheritic endometritis,** following labor and abortion. On the surface of the endometrium is a necrotic layer formed of

Fig. 117.

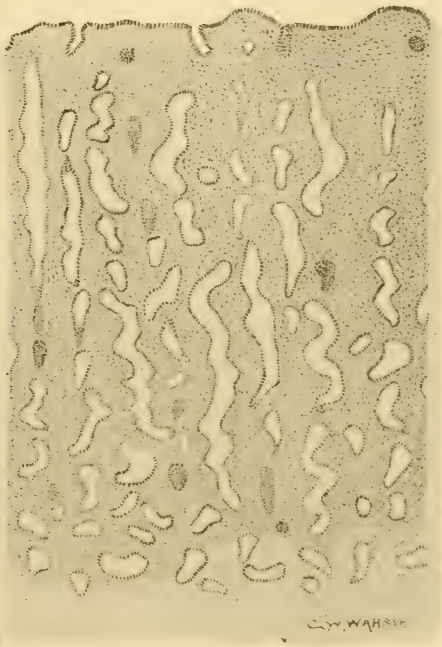

Normal endometrium of a young woman. The surface is covered with a single layer of low columnar epithelium. The glands are tubular, wavy, lined with columnar epithelium similar to that of the surface, and extend to the musculature. They run almost at right angles with the surface of the endometrium. The connective tissue is embryonal in type, and contains but few small bloodvessels, difficult to demonstrate.

fibrin, degenerated epithelium, leucocytes, blood, and micro-organisms.

II. **Microscopic Forms of Endometritis.** The importance of the microscope in the diagnosis of endometritis has been alluded to. It may be said that the microscope affords the only means of making a positive diagnosis of these cases. Without the aid of the microscope and relying upon clinical signs and symptoms, not only may

the diagnosis and prognosis be faulty, but the uterus may be sacrificed in the treatment of what appeared to be a malignant growth. Furthermore, life may be sacrificed from failure to remove a malignant growth in which the characteristic symptoms were absent or suggestive of endometritis. In order that no serious oversight be made, it is important that a systematic microscopic examination be made of all uterine scrapings.

Two general forms of endometritis are recognized by the microscope—the glandular and the interstitial. The two forms are very commonly associated.

a. **Glandular endometritis** is characterized by an increase in size or number, or both, of the glandular elements. The surface of the endometrium is thrown into irregular elevations, forming folds, fungosities, villi, or polyps.

By the increase in size and number of the secreting epithelial cells the glands become enlarged and irregular in their course. The interglandular spaces are decreased proportionately to the increase in the glandular elements. The glands which in normal conditions rarely penetrate into the musculature will, when hypertrophied, penetrate this region to a limited degree. The distortion of the glands may be extreme. In longitudinal sections the glands may appear to twist like a corkscrew. The inversion and eversion of the glandular epithelium may give to the gland a serrated appearance.

The glands are not only increased in size (*hypertrophic glandular endometritis*), but may be increased in number (*hyperplastic glandular endometritis*). The increase in the number of the glands is a result of a budding from preformed glands, or of invaginations of the surface epithelium.

If we fail to satisfactorily classify the established forms of endometritis, how much more difficult it is to draw the line sharply between inflammatory growths of the endometrium and true tumor formations.

Are we to recognize a benign adenoma of the uterus? Are the mucous polyps to be classified as new-growths or as polypoid forms of endometritis? In short, is it possible to define the so-called hyperplastic glandular endometritis from benign adenoma of the endometrium?

Referring to general pathology, we are unable to distinguish hyperplastic glandular growths of inflammatory origin from benign

PLATE XXXIV.

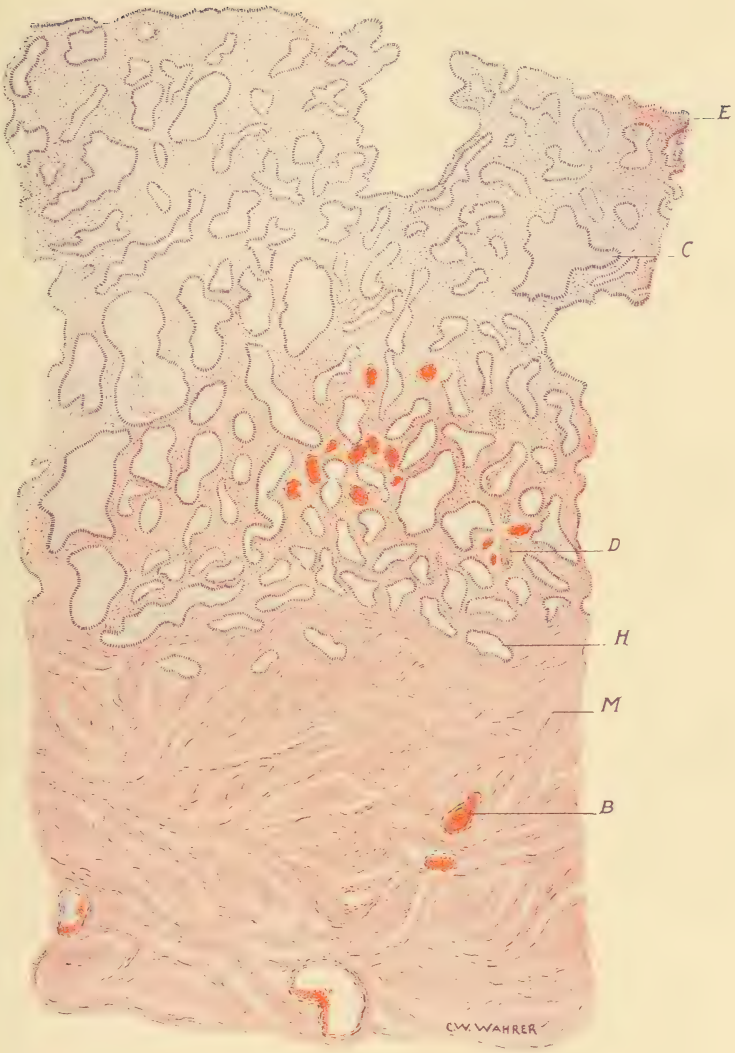

Cystic Hyperplastic Glandular Endometritis.

E. Surface epithelium.
C. Cystic space formed from a dilated gland, lined by a single layer of columnar epithelium and filled with serum.
D. Group of small round cells.
H. Cross-section of a gland lying within the musculature.
M. Musculature.
B. Congested bloodvessels.

adenomata. In reviewing the opinions of a number of authors it becomes evident that to separate the two would be impossible, and to admit of a connecting link between the two lesions is admissible.

Rindfleisch, Chiari, Weichselbaum, and Orth favor the view of simple inflammatory hyperplasia to the exclusion of benign adenoma of mucous surfaces. Thoma, Eppinger, and Ponfick recognize adenoma, while others, as Van Heukelom and Birch-Hirschfeld, believe in the existence of a connecting link between

Fig. 118.

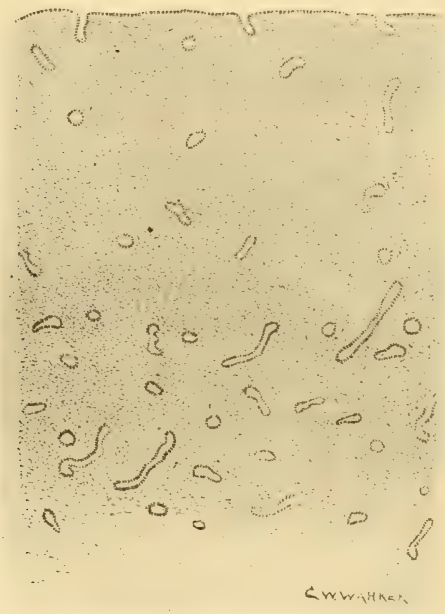

Normal endometrium of a woman in the postclimacteric period. The connective tissue is more compact and mature; the glands are small and far separated.

these lesions. All believe in the inflammatory origin of mucous polyps. Polyps of inflammatory origin are found in the stomach by Klebs. Birch-Hirschfeld, Petrow, and Landel describe diffuse and circumscribed growths of the gastro-intestinal tract due to catarrhal inflammation. By a careful analysis of their reports it is evident that inflammatory hyperplasia of mucous surfaces merges insensibly into tumor growths both benign and malignant. In a

large percentage of their cases carcinoma was associated in the same organ.

In the urinary tract Stoerck, Cahen, Rehn, and Kaufmann recognize papillomata of inflammatory origin.

Le Count says: "It is especially concerning tumors of the Fallopian tube that confusion has arisen; there has been quite a general failure to recognize that a diffuse hyperplastic inflammation is possible—a process that is strictly analogous to the polypous hyperplasia of other mucous surfaces—and that in certain typical examples it is as distinct from tumor growth as gastritis proliferans is from carcinoma of the stomach." He believes it to be fully demonstrated that there exists an imperceptible transition of hyperplastic processes of the tubal mucosa into those of true tumor growth, and that these may terminate in the production of benign tumors.

If, then, there is no unanimity of opinion among general pathologists, it is not surprising that the same discrepancy exists among gynecologists in reference to similar lesions in the endometrium.

We find Pozzi, Olshausen, Döderlein, Gebhard, and Ruge failing to recognize benign adenoma of the uterus, and classifying them all as inflammatory hyperplasia, reserving the term adenoma for malignant glandular growths.

Herman gives as his reasons for discrediting the inflammatory origin of these growths—first, that pus would be secreted if it were inflammatory; second, recovery would ensue if it were genuine endometritis; third, severe hemorrhage would not occur if it were endometritis. He, therefore, speaks of polypoid and hyperplastic or diffuse adenoma. The fallacies of his reasoning are too evident to demand consideration.

Landau tells us that the increase in the number of glands can only occur in adenomata, and never in endometritis; while Gebhard, Ruge, and Döderlein speak of this increase in the number of the glands as characteristic of hyperplastic glandular endometritis.

The conclusion is that the two lesions cannot be clearly differentiated; that a connecting link exists between them. Practically speaking, all are agreed that there exists a tendency on the part of inflammatory glandular growths to develop into benign and malignant new-growths, and when occurring in old age, or when recurring after repeated curettage, they are to be regarded with suspicion.

The buds from parent glands may again and again give off new glands. We speak of an *inverted gland* when processes of the

Fig. 119.

Fig. 120.



Fig. 121.

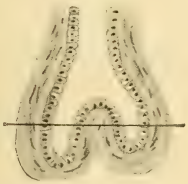

Fig. 122.



Fig. 123.



Fig. 124.

Fig. 125.



Fig. 126.

Explanation of scheme of gland invagination. Figs. 119 to 125 show longitudinal sections of invaginated uterine glands; Figs. 120 to 126 show cross-sections of the same gland. The glands shown in longitudinal section are crossed each by a line showing the plane at which the cross-sections are made. Fig. 119 shows the fundus of a gland invaginated with secondary eversion. Fig. 125 shows intraglandular papillary invagination of a gland epithelium from the side of the gland. Fig. 121 shows simple invagination of the fundus of a gland. Fig. 123 shows the inner and outer segments regular and the middle segment invaginated.[1]

[1] Amann. Mikroskopisch-Gynäkologischen Diagnostik.

gland protrude into the lumen; of an *everted gland* when the processes protrude from the lumen. In the inverted gland cross-sections will give the appearance of a gland within a gland—see the schematic drawing, page 245. More or less connective tissue invariably separates the glands—a fact to be remembered in differentiating this condition from malignant adenoma. In rare instances two or more layers of epithelium are found on the surface of the

Fig. 140.

Interstitial endometritis. The glands are decreased in size and far separated by mature connective tissue.

mucosa or in the glands. Many layers of squamous epithelium have been observed. Such proliferating epithelium is always superficial, never passing beyond the basement epithelium, as in malignant glandular growths.

Spontaneous healing of glandular endometritis is possible though not probable. At the time of the menopause the hypertrophied glands may diminish in size along with contraction of the interstitial connective tissue.

PLATE XXXV.

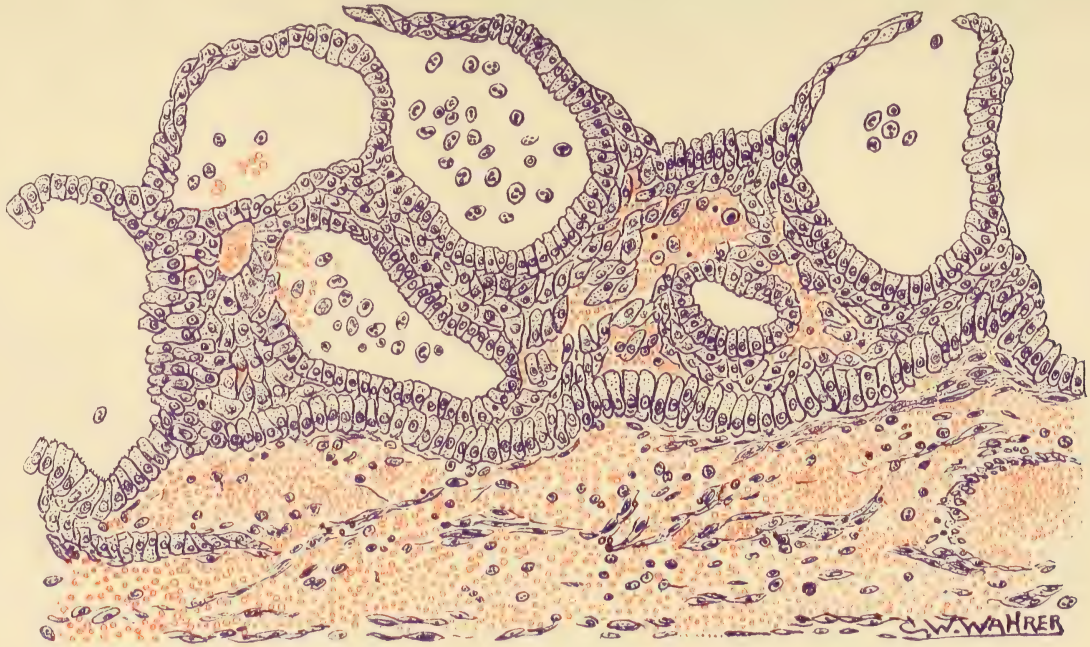

Proliferation of epithelium into gland structures in a hyperplastic glandular endometritis.

b. **Interstitial endometritis** is characterized by a hyperplasia of the interglandular connective tissue at the expense of the glandular elements. Two stages are recognized—the acute and the chronic.

FIG. 128.

Tuberculous glandular endometritis. Three giant cells are seen in the section. There is an extensive round-cell infiltration and degenerative changes.

Acute interstitial endometritis presents a small round-cell infiltration in the stroma, which may be diffused or circumscribed. The bloodvessels are congested and a serous or serosanguineous exudate permeates the connective tissue spaces. The glands are crowded apart by the widening of the interglandular spaces. They are irregularly compressed, causing them to be greatly distorted. Healing may be perfect from absorption of the exudate, or the acute stage may gradually merge into the chronic.

Acute senile endometritis is described by Dunning, who presents the following summary of the anatomical findings: The endometrium is thickened, the free surface is devoid of an epithelial covering; there is an increase in the vascularity with a peculiar arrangement of the small bloodvessels; there is a small round-cell infiltration; the glandular elements are diminished; the coats of the arteries of the muscularis are degenerated. The presence of diseased appendages in both cases reported by Dunning and of a mild form of pelvic peritonitis in one case seems to indicate that the inflammation tends to extend beyond the limits of the uterus.

Chronic Interstitial Endometritis. Newly-formed connective tissue separates the glands. The glands are irregularly compressed and may suffer pressure atrophy. In place of the embryonal connective tissue normally found in the endometrium, there is matured fibrous tissue which first thickens the endometrium and later contracts, resulting in a diffuse or localized atrophy of the mucosa. The surface of the endometrium becomes irregular. Retention cysts may appear in the endometrium from an obstruction at the outlet of the glands, causing the glands to distend with the secretions. In direct proportion to the distention of the glands, the epithelial cells lining them are compressed and may be quite flattened. The interglandular spaces may be greatly narrowed. When retention cysts are numerous the term *cystic glandular endometritis or cystic interstitial endometritis* is applied.

When the connective tissue spaces are filled and distended by a serous or serosanguineous exudate, the term *exudative interstitial endometritis* is applied. Thus, there may be a combination of these forms, and one may speak of an hypertrophic and hyperplastic cystic, exudative, glandular, and interstitial endometritis—a rather formidable name, but nevertheless suggestive.

Combinations of the glandular and interstitial forms of endometritis are the rule. It is unusual for either form to exist alone.

Rarely are the glandular and interglandular tissues uniformly involved (diffuse endometritis).

The diagnosis of uterine scrapings in endometritis is pre-eminently satisfactory and reliable. The loose texture of the endometrium permits easy removal of the mucosa by the sharp curette. It is true that the structures composing the mucosa are more or less distorted in the scrapings, and that the deep layers of the endometrium are seldom found in the removed particles. When we consider that the upper strata may show glandular changes and the lower, interstitial changes or the upper strata show an inflammatory reaction and the lower malignant degeneration, it is evident that the microscopic examination of scrapings is not always reliable.

Little can be definitely learned from the naked eye appearance of the scrapings. Large, friable masses, homogeneous in appearance, of a pale gray color, suggest malignancy. In cystic formations the open spaces may be detected by the naked eye. In general, it may be said that little that is positive can be learned from a macroscopic examination of particles removed from the uterus by the curette. Ruge says: "*Die Menge des Ausgekratzen, sei sie gering, sei sie reichlich, giebt neimals, für sich schon einer sicheren Anhalt für die Entscheidung, obwerklich malign oder ob nur benign.*"[1]

ENDOCERVICITIS (Endometritis Cervicalis).

Endocervicitis is an inflammatory lesion confined to the cervical canal. Part or all of the cervical endometrium may be involved, the extent of the lesion varying from a mere inflammatory zone about the external os to a diffuse inflammation of the entire surface, extending above the internal os and below the external.

The diagnosis should not be difficult, because of the accessibility of the lesion to direct inspection and exploration. The color of the inflamed mucosa varies from a bright red to a dull cyanotic hue. The surface may be smooth, but is more often granular or papillary. The arbor vitæ are rounded and partially obliterated. By touching the surface with the finger or sound slight bleeding may be excited, and it is even possible for spontaneous bleeding to occur. Tenacious, glairy mucus covers the surface and may effectually plug the cervical canal. The mucus accumulating within the cervical canal may cause pressure atrophy of the mucosa

[1] Winter's Gynäkologische Diagnostik.

and thus dilate the canal. The secretion may be clear, transparent mucus or may be milky from the addition of leucocytes and epithelium.

Mucous polyps of inflammatory origin protrude from the mucosa into the cervical canal and out through the external os into the vagina.

Microscopic examination of scrapings from the cervix is unsatisfactory, for the reason that the surface epithelium and glands are firmly embedded in connective tissue and are not readily scraped away, as is the endometrium of the uterine body. As in endometritis, we find in the cervix two microscopic forms—the glandular and interstitial.

EROSIONS OF THE CERVIX.

An erosion of the vaginal portion of the cervix is a mucous patch consisting of a layer of columnar epithelium and newly-formed glands lying beyond the external os and replacing squamous stratified epithelium. Formerly erosions of the cervix were believed to be true ulcers, and were vulgarly called "ulcers of the womb." We are indebted to Ruge and Veit for the demonstration of their true character. The red or bluish color of the mucous patch is in marked contrast to the surrounding pale and smooth vaginal epithelium. The margins are irregular but sharply circumscribed. The extent of the lesion is variable. In nulliparæ there is usually a mere zone about the external os, while in multiparæ the erosion may extend far up upon the vaginal portion of the cervix and even to the vault of the vagina. Isolated patches may be seen on the vaginal portion of the cervix, with normal vaginal epithelium intervening.

Classification. Erosions may be classified as simple, papillary, and follicular.

1. **A simple erosion** has a smooth surface covered with a single layer of columnar epithelium. Newly-formed glands may dip into the underlying connective tissue.

2. **A papillary erosion,** as the name implies, presents a papillary surface. In addition to the surface layer of columnar epithelium there are deep invaginations in the form of glands alternating with elevations composed of new-formed connective tissue and round cells. The new-formed glands vary greatly in number and size and secrete abundant mucus. The papillary elevations are in direct

proportion to the connective tissue hyperplasia and round-cell infiltration.

3. **A follicular erosion** is characterized by the presence of retention cysts, the so-called "Nabothian follicles." These retention

Fig. 129.

Transition of squamous epithelium of vaginal portion to columnar epithelium of cervical canal. (Abel.)

cysts arise from the occlusion of the mouths of the new-formed glands in the erosion. They are filled with inspissated mucus. To the touch of the examining finger they are likened to the feeling of shot under the skin; to the eye they appear as rounded eleva-

Fig. 130.



Papillary erosion of the cervix. The squamous epithelium has been partially replaced by columnar epithelium. The surface is uneven and papillary. The tissue is deeply infiltrated with small round cells, and new glands are formed by the invagination of the surface epithelium.

tions of a gray, blue, or yellow color. In number they range from one to a score or more, and may attain the size of a hen's egg, though it is unusual for them to distend to a size larger than a hazelnut. The epithelium lining the cyst becomes flattened and may be entirely lost.

The Healing of Erosions. *We speak of incomplete and of complete healing of erosions.* By this is meant the replacing of the mucous patch with squamous epithelium.

FIG. 131.

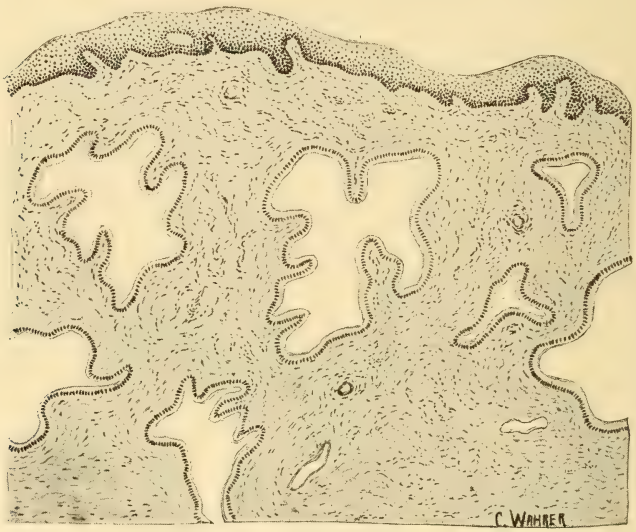

Healed erosion of the cervix. Mucous secreting glands are locked in by many layers of squamous epithelium. Formerly the surface was covered by a layer of columnar epithelium from which the glands dipped into the connective tissue. The surface epithelium became transformed into stratified squamous epithelium and the glands were buried beneath.

In *complete healing of an erosion* the surface epithelium and the glands of the erosion are completely replaced by squamous epithelium, thereby restoring the vaginal portion of the epithelium to its normal integrity.

In *incomplete healing of an erosion* the columnar epithelium on the surface of the erosion is replaced by many layers of squamous epithelium similar to that of the surrounding vaginal mucosa. The glands beneath are not obliterated, but are either locked in beneath the squamous epithelium or open directly upon the surface now covered with squamous epithelium.

Healing of an erosion may be effected by metaplasia of the cylin-

drical epithelium into many layers of squamous epithelium (see Fig. 132).

Differential Diagnosis of Endocervicitis. A clinical diagnosis of endometritis is commonly made from the mucous or mucopurulent secretion coming from the cervix. It is well to discriminate between a hypersecretion of the cervix due to passive congestion and a secretion which is the expression of an infection. This, however, is not always possible. A mucous secretion seen to leave

FIG. 132.

Incomplete healing of an erosion of the cervix. Between two sections of stratified squamous epithelium is a limited amount of columnar epithelium which is invaginated in the form of irregular glands. Numerous glands are locked in beneath the squamous epithelium.

In this case the surface was originally smooth and covered with stratified squamous epithelium; the squamous epithelium became destroyed and replaced by a single layer of columnar epithelium, from which glands were formed. Subsequently, through a healing process, part of the surface epithelium was transformed into stratified squamous epithelium and the glands were covered over, as seen above.

the cervical canal must necessarily come from the cervix, there being no mucus in the secretion of the uterine body or Fallopian tubes. When pus is mixed with the mucus, there can be no doubt as to the infectious origin of the secretion.

Erosions of the cervix may closely simulate carcinoma. The macroscopic appearance may be identical. The differential diagnosis is given in Chapter XXVI.

Ectropion of the lips of the cervix may closely resemble erosions. If the lips of the cervix are grasped by tenacula and approximated, the reddened surface will roll into the cervical canal and disappear. If an erosion is present, there will be no disappearance of the reddened zone.

ULCERS OF THE CERVIX.

True ulcers of the cervix are of rare occurrence. Formerly erosions were regarded as such.

Decubitus ulcers of the cervix are found in prolapsus of the uterus, and as the result of ill-fitting pessaries. Such ulcers may attain the size of a silver dollar. They are usually superficial with irregular outlines; the margins are not elevated; the base is granular, firm, and covered by a grayish-yellow secretion. The tendency to bleed is not great, as compared with malignant ulcers. Furthermore, in contrast with carcinoma, there is a marked tendency to cicatrization. Under the microscope the epithelium is seen to be lost. The base is thickly beset with distended capillaries embedded in the meshes of connective tissue and small round cells. This round-cell infiltration extends a variable distance into the underlying connective tissue. A structureless, necrotic material may collect upon the base of the ulcer.

Tuberculous ulcers will be described below.

Cancerous Ulcers. (See Chapter XXVI.)

TUBERCULOSIS OF THE CERVIX.

Tuberculosis of the cervix, as a primary lesion, is a rare finding. Beyra finds sixty-eight cases of primary tuberculosis of the cervix in the literature, and adds a single case. In nine of these cases the lesion was confined to the cervix; in the balance there was an invasion of adjacent structures. The greatest number occurred between the ages of twenty-one and forty years; the extreme ages were seventeen and seventy-nine.

Beyra divides the pathological forms into the ulcerative, hyperplastic, and miliary.

Tuberculous ulcers of the cervix may follow primary tuberculous infection of the endometrium; or, as is more often the case, a primary infection of the tubes with subsequent extension downward to the uterus and cervix. The diagnosis must be based upon the

finding of giant cells, of tubercles, and of tubercle bacilli in and about the ulcers. The margins of a typical tuberculous ulcer are irregular and undermined; the base of the ulcer is uneven and tends to heal by cicatrization.

Miliary tuberculosis of the cervix has been recognized but three times.

In general, it may be said that tuberculosis of the cervix closely resembles erosions and cancer. A positive diagnosis can only be made by the aid of the microscope. The clinical history and the finding of tuberculosis elsewhere in the body, particularly in the upper genital tract, is of importance in the consideration.

CHRONIC METRITIS.

Endometritis can scarcely exist without more or less involvement of the uterine musculature. In acute affections the muscularis is congested, and the connective tissue spaces are filled with a serous exudate and a round-cell infiltration. Abscesses may develop in the connective tissue spaces and infected thrombi may form in the blood spaces.

In the chronic stage there is a development of connective tissue between the muscle fibres. As the connective tissue forms and contracts the muscle fibres atrophy, and through this process the uterus becomes very firm.

The diagnosis is based upon the uniform enlargement of the uterus and upon the change in its consistency. In the chronic stage there may be no tenderness on pressure.

Chronic metritis may be regarded as a clinical term signifying a uterus that is uniformly enlarged, firm in consistency, and one which has lost its normal flexibility.

Chronic metritis is to be diagnosed from interstitial fibroids. (See Chapter XXV.)

CHAPTER XXV.

THE DIAGNOSIS OF FIBROMYOMA OF THE UTERUS.

Etiology. We know nothing of the essential cause of uterine fibroids. Heredity has been discussed as a possible etiological factor. While there are families in which two or more members are known to have fibroids of the uterus, the influence of heredity is not to be overestimated. Engstrom, in 530 cases of uterine fibroids, found a similar lesion in the mother or sisters thirteen times.

It is a matter of common observation that the negro race is more susceptible to fibroids than the Caucasian. Kelly and Williams deny this. In 357 cases reported by Williams, fibroids were only 2 per cent. more frequent in the colored race.

The time of occurrence is during the period of sexual maturity, the greatest number occurring between the ages of thirty and forty. It is most unusual for fibroids to arise before puberty or after the menopause. Müller reported 299 cases of uterine fibroids, of which number 120 were observed after forty-five years of age.

It has been observed that virgins and nulliparous married women show a greater disposition to fibroids than do multiparæ. On the other hand, sexual excesses are said to favor the growth of fibroids. Möller states that 67 per cent. occur in women who are not virgins.

As to the frequency of occurrence, Boyle holds that 20 per cent. of women who have reached thirty-five years of age have fibroids, while Klobs affirms that 40 per cent. of women who reach fifty years of age have fibroids of varying size and number.

In Veit's *Handbuch* we read: "So far as the common myomata (excluding the adenomyomata) are concerned, I hold that their origin from an embryonic inclusion has not been proven. It appears, however, that heredity plays a rôle therein; and one is also able to understand that irritation, acting chronically upon the uterus, may give rise to the formation of myomata, but the *modus operandi* of the latter is not yet clearly proven."

Histogenesis. According to Kleinwächter, fibroids originate from round cells found in bloodvessels, which later become obliterated. The round cells are converted into muscle and connective tissue fibres. Rösger believes their origin to be in the muscle

FIG. 133.

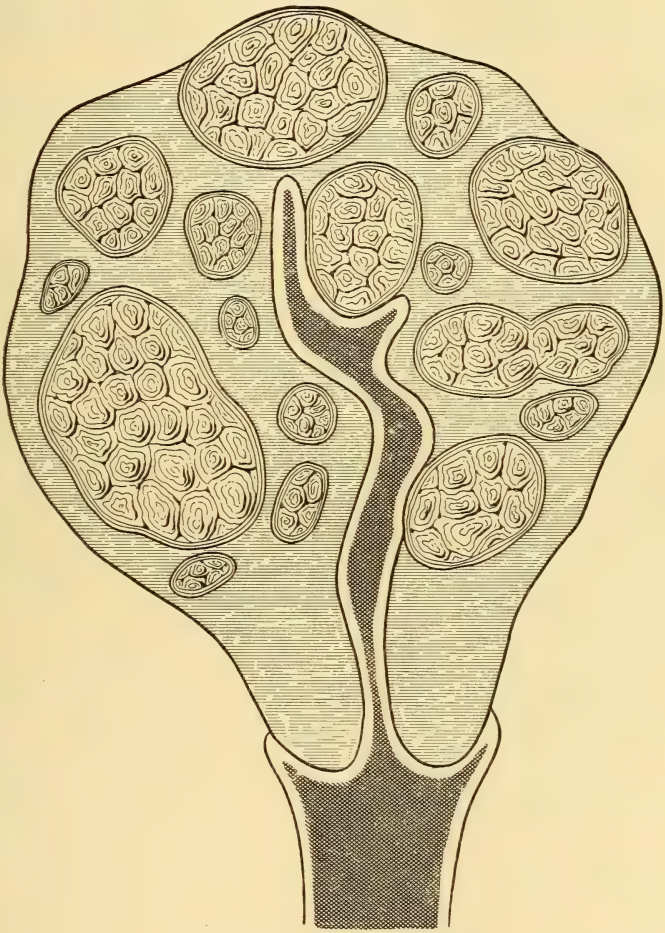

Multiple myomata. (DUDLEY.)

fibre of bloodvessels. Gottschalk is of the opinion that it is not the musculature of the bloodvessels that forms the matrix of the tumor. He observed amœbic movements in certain protoplasmic bodies which he interpreted to be parasites, and believed them to be the essential cause of fibroids. Vedeler believed he

discovered animal parasites in uterine fibroids. Virchow believed them to be a hyperplasia of the uterine musculature. Judging from the above conflicting opinions, it is evident that nothing is certainly known of the histogenesis of uterine fibroids.

The Anatomical Diagnosis of Uterine Fibroids. Under this head we will consider the size, form, consistency, rate of growth, number, and position of the tumor, and also the microscopic structure.

In *size* uterine fibroids vary from almost microscopic dimensions to the tumor reported by Hunter, weighing 140 pounds.

The *form* is smooth and rounded, or, as is more often the case, nodular.

In *consistency* fibroids vary from soft and semifluctuating to a stone-like hardness. Fibroids are classified as hard and soft. Hard fibroids consist largely of fibrous tissue with a relatively small amount of muscle fibre; the blood supply is not great. Soft fibroids are made up of a relatively large amount of muscle tissue and are very vascular.

The *rate of growth* of soft fibroids is more rapid than of hard fibroids. During pregnancy fibroids grow rapidly. After the menopause they usually decrease in size, though the menopause is often delayed three to ten years.

It is exceptional for fibroids to exist singly. As many as 400 separate and distinct tumors have existed in the uterus. We speak of fibroids as *single* or *multiple*.

The *position* of fibroids in relation to the uterine wall is of the greatest clinical importance. The terms submucous, intramural or interstitial, and subserous or subperitoneal are used to designate the location of the tumor. All fibroids are originally intramural, and as they increase in size they tend to grow in the direction of least resistance. For example, an intramural fibroid lying nearer the endometrium than the perimetrium will eventually become submucous. So long as a fibroid is completely enveloped by the musculature, no matter to what extent, it is intramural, but when the capsule of the fibroid is immediately covered with peritoneum or mucosa it becomes subperitoneal or submucous. When the growth sits upon the inner or outer surface of the uterus with a broad base, it is known as a sessile growth; when the base of attachment is constricted, it is known as a pedunculated growth. The more pedunculated the tumor the slower the growth, because

of the limited blood supply passing through the pedicle. The pedicle when long may so limit the blood supply to the tumor that atrophy will result. Twisting of the pedicle may completely interrupt the blood supply, in which case the fibroid will become gangrenous. If the tumor is adherent to neighboring structures, a requisite supply may be conveyed by the adhesions. A partial twist of the pedicle may be followed by atrophy or œdema of the tumor.

Spontaneous amputation of the tumor by lengthening or twisting of the pedicle is one of nature's means of effecting a cure in submucous growths.

FIG. 134.

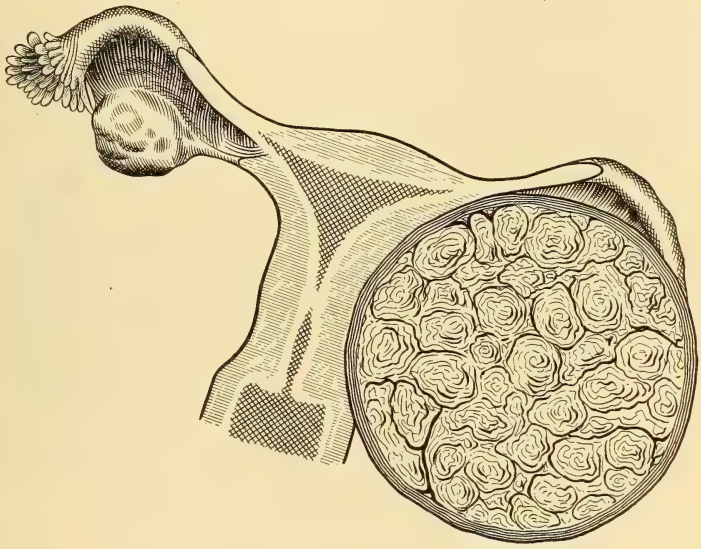

An intraligamentous myoma uteri. (DUDLEY.)

Fibromyoma of the cervix occurs in about 6 per cent. of all uterine fibromyomata.

a. Submucous fibromyomata bulge into the uterine cavity and are directly covered with mucous membrane. They are either pedunculated or sessile, single or multiple, and are seldom as large as the patient's head. The pedicle may permit them to protrude into the cervical canal or further on into the vagina. They usually possess a relatively large amount of muscle fibre and blood-vessels, and hence are soft in consistency and their growth is rapid. When large and soft their form is moulded to that of the uterine cavity. They are rarely spherical, but more often elongated. The

cervix may constrict them into an hour-glass shape. As the tumor increases in size the overlying mucosa may be atrophied; likewise, the opposing mucosa of the uterus may suffer pressure atrophy, and adhesions may form between the tumor and uterine mucosa. This explains the absence of hemorrhage in many of the large submucous fibroids. Leyden and Küster described a case in which a fibromyoma having become detached from the uterus adhered

Fig. 135.

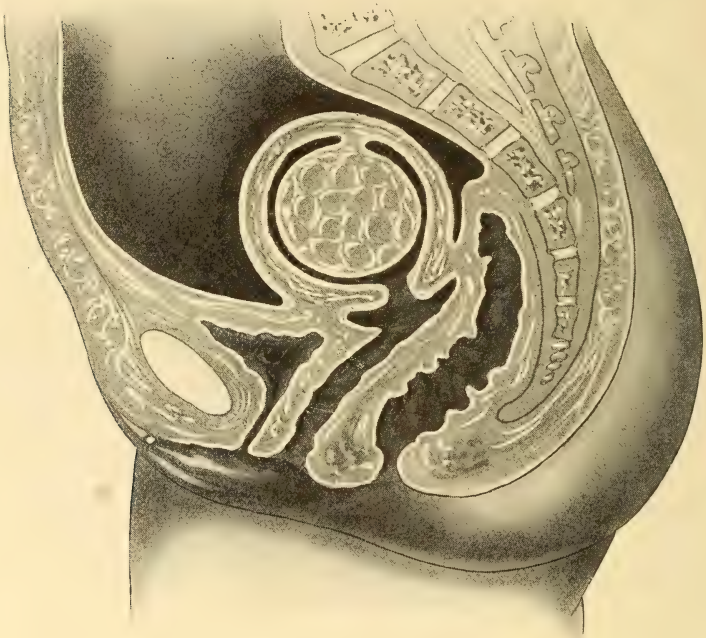

Submucous fibroid of the uterus. The uterus is evenly distended by a large fibroid.

firmly to the cervix. Partial inversion of the uterus may be caused by traction upon the fundus by a pedunculated submucous fibroid attached to the fundus. The effort on the part of the uterus to expel the fibroid causes the inversion.

b. Interstitial fibromyomata lie encapsulated within the uterine wall. Rarely are these growths ill-defined from the uterine musculature (diffuse fibromyomata). When large the growth bulges upon the mucous or serous surface or upon both surfaces. Such growths

are usually multiple and are seldom so firm in consistency as are subserous growths.

c. Subserous fibromyomata bulge upon the serous surface of the uterus. They are single or multiple, commonly firm in consistency, though sometimes soft and apparently fluctuating. When pedunculated they may be freely movable, or firmly fixed by adhesions which bind the growth to surrounding structures. When located at the side of the uterus the growth may develop between the

FIG. 136.

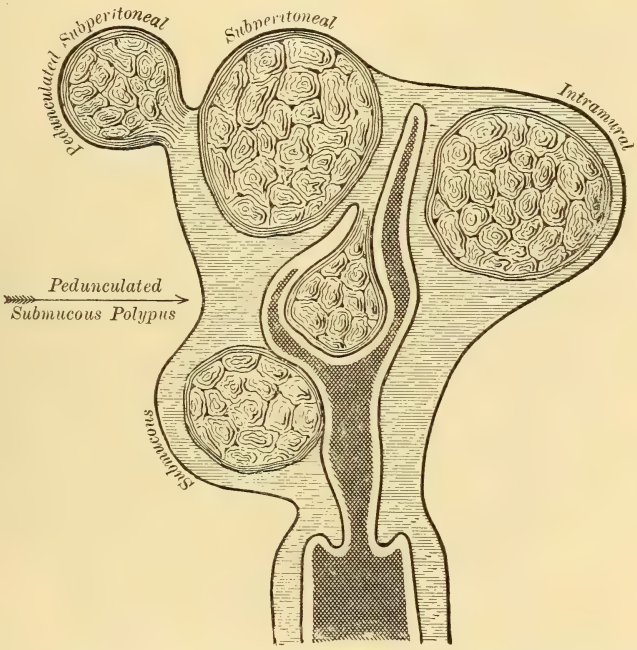

Intramural, submucous, and subperitoneal myomata. A pedunculated subperitoneal myoma is sometimes wrongly called extra-uterine myoma. A pedunculated submucous myoma is called intra-uterine polypus. (DUDLEY.)

layers of the broad ligament—"intraligamentary or broad ligament fibroids."

Fibroids of the cervix may be submucous, interstitial, or subserous (subvaginal). Submucous fibroids of the cervix are seldom large. They are usually pedunculated, and as such are known as fibrous polyps.

Interstitial fibroids of the cervix distort the cervical canal, and may cause complete obstruction, locking in secretions above and preventing conception.

Subserous fibroids of the cervix are very rare, and are seldom of large size. They may grow into the vagina or into the paravaginal connective tissue.

On *cross-section of a fibromyoma* bands of fibrous and muscular tissue are seen running in various directions and forming whorls, concentric rings, and wavy lines. The color varies from gray to a rosy hue, depending upon the relative amounts of fibrous and muscular tissue and upon the blood supply.

FIG. 137.

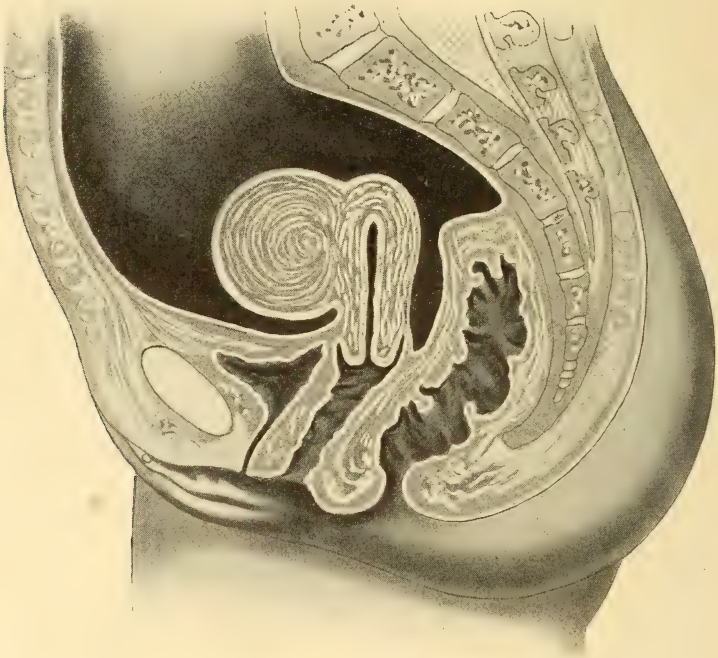

Subperitoneal fibroid of the uterus. The uterus is crowded backward by a fibroid attached to its anterior wall.

The **microscopic diagnosis** is based upon the finding of mature connective tissue and muscle fibres. Without a knowledge of the gross appearance of the tumor it is impossible to distinguish a fibroid from the uterine wall. The relative amount of connective tissue and muscle fibres varies widely.

A pure fibroid does not exist. There is always present more or less muscular tissue. As age advances the connective tissue increases at the expense of the muscular elements. The muscle fibres are

involuntary, and contain spindle-formed nuclei. The cell protoplasm is homogeneous, rarely granular. On cross-section the nucleus is half-moon shape. Some fibres contain two or more

FIG. 138.

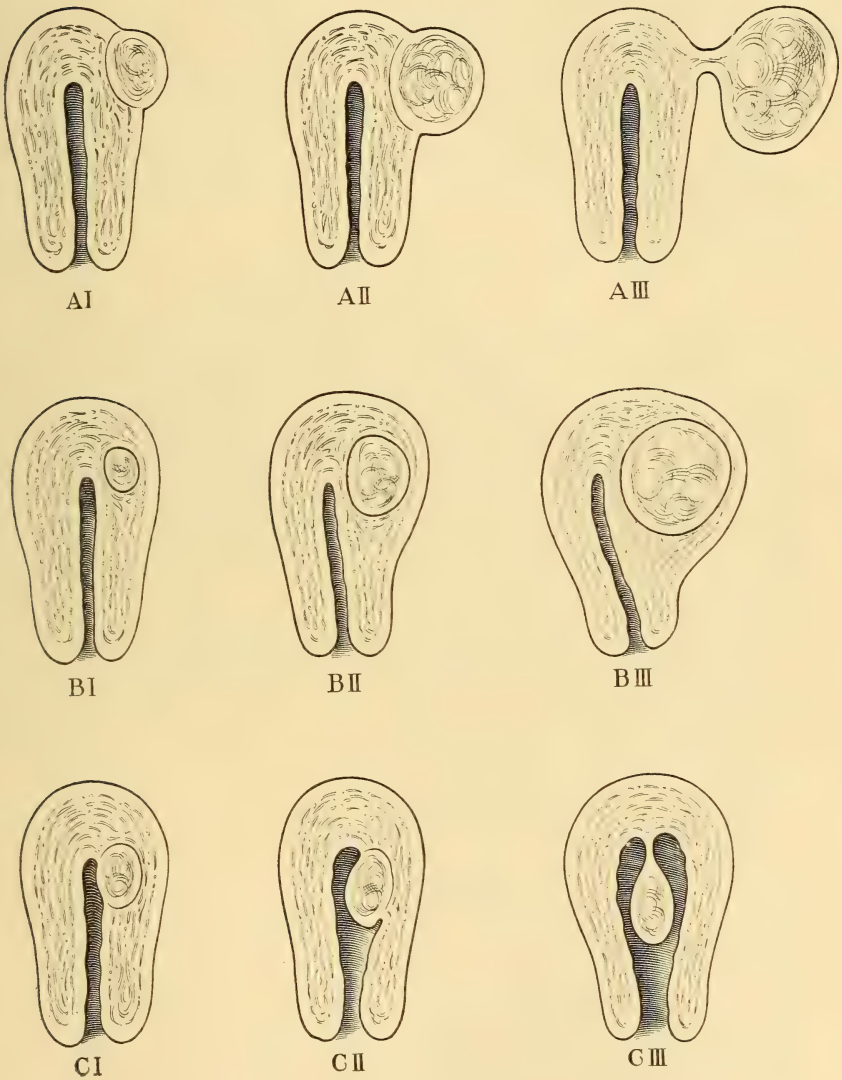

Schematic drawing representing the development of uterine fibroids and their relation to the uterine wall. (Suggested by FEHLING.)

AI, AII, AIII. Subperitoneal fibroids. BI, BII, BIII. Interstitial fibroids. CI, CII, CIII. Submucous fibroids.

nuclei. Karyokinetic figures are seldom seen in the muscle cells of the slow developing growths, but are present in proportion to the rapidity of the growth. The connective tissue usually forms a loose texture, poor in nuclei. In other growths and in other fields of the same growth the connective tissue may be more compact and contain round or oval nuclei.

Bloodvessels course through the connective tissue. Veins are not as numerous as arteries, particularly in old fibromyomata. A central artery running an irregular course through the centre of the fibroid is described by Gottschalk, but has not been generally recognized. Lorey and Hertz have described nerve fibres in fibromyomata.

ADENOFIBROMYOMA UTERI.

Fibroids containing glands are described by numerous authorities. Shroeder believes the glands originate in the endometrium. Carl Ruge, Gottschalk, Kossman, and others maintain that they arise from Gärtner's ducts. Recklinghausen contends that the glands arise from the Wolffian body or from the endometrium. These peculiar growths are almost invariably intramural. They never possess a capsule, and are known as diffuse or infiltrating fibroids. They are found in the tube, the uterine horn, and occasionally in the posterior wall of the uterus.

Gebhard gives the following varieties:

1. A hard form in which the muscle tissue predominates over the glandular elements.
2. A cystic tumor with many large spaces.
3. A soft form in which the glandular elements predominate over the fibrous or muscular.
4. A soft form with widened blood spaces—telangiectatic or angiomatous adenomyoma.

In the growths are often seen small ducts communicating with a single large one as the teeth of a comb are joined to its back. These ducts are embryonic inclusions of the ducts of the Wolffian body and the "uriniere." They may distend into cysts compressing the surrounding connective tissue. The contents of the cyst are clear and serous, occasionally colored by pigment.

Recklinghausen speaks of pseudoglomeruli in describing elevations attached to the cyst wall by a broad base.

Pick described a submucous adenomyoma averaging 55 grammes.

Cullen reported to the Johns Hopkins Society an adenomyoma of the round ligament.

DEGENERATION OF FIBROIDS

The various forms of degeneration of fibroids are not only of pathological interest, but their recognition is of the greatest clinical importance. Nobel estimates that serious complications arise in fibroids in about one-third of all cases. Of these complications the various forms of degeneration constitute a large proportion.

FIG. 139.

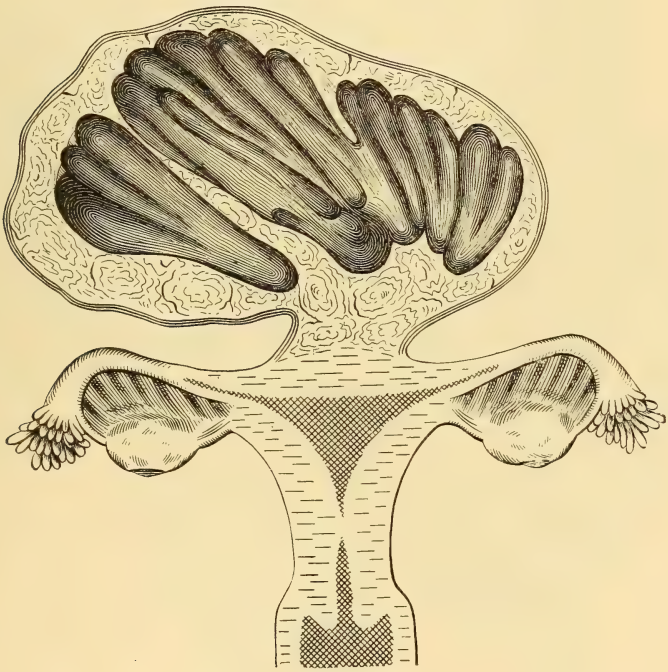

Fibrocystic myoma uteri. The interior of the tumor shows the fibrocystic change. (DUDLEY.)

1. **Atrophy.** We are familiar with a physiological atrophy of fibroids following the climacteric. A similar change takes place in event of an artificially induced menopause by the removal of the ovaries. In pedunculated tumors the blood supply is limited, and as a result atrophy may follow. According to Shroeder, this atrophy consists of a fatty degeneration. It is more probably a

simple atrophy in which the muscle cells diminish in size and in number. In this manner large tumors may wholly disappear.

2. **Calcareous degeneration** may occur in fibroids of all sizes and locations. The calcareous deposits are found in the connective tissue, often leaving the muscle fibres isolated and incrusted.

Fig. 140.

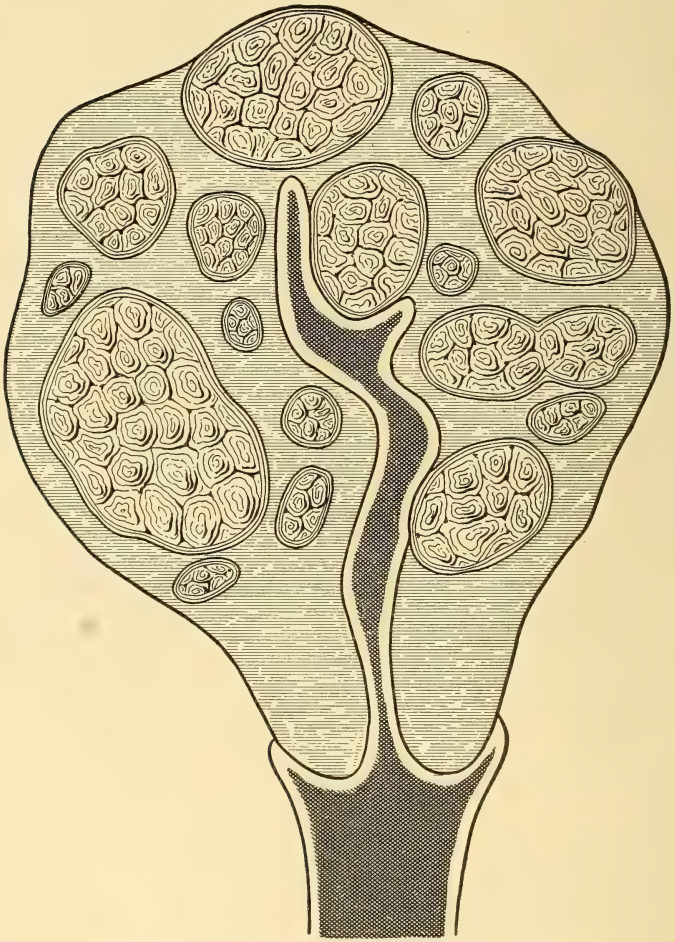

Multiple myomata. (Dudley.)

Gebhard gives the following analysis of the deposit:

Calc. carb.	49.0
Calc. phosph.	29.0
Calc. sulph.	13.0
Calc. lithat.	0.5
Organic substances	0.4

Petrified fibroids are known as "womb stones." It is possible for such stones to be severed from the uterus and lie free in the peritoneal cavity, or, if submucous, to be either retained in the uterus or expelled. Womb stones were described by Hippocrates. Everett reported one weighing 2.04 kg.

3. **Fatty degeneration** of fibroids following pregnancy is of common occurrence. The tumor is soft and of a mottled, yellow tint. Fat droplets are seen in the muscle fibres.

FIG. 141.

A pedunculated subperitoneal fibroid lies above the promontory of the sacrum and is too large to fall into the pelvis. It has drawn the uterus and vagina upward.

4. **Myxomatous degeneration** of fibroids is a circumscribed degeneration of the connective tissue. Rarely is there a diffuse involvement of the tumor. Before cutting into the tumor it may appear cystic. On cross-section one or more areas of degeneration are seen. The myxomatous material is glairy and translucent, contain-

ing opaque particles and a fibrillar or fibrous network. By absorption of the myxomatous material cystic spaces are formed.

5. **Suppuration and gangrene of fibroids** is a grave condition demanding immediate surgical interference. The usual cause is puerperal infection. Subserous fibroids may be infected through the bowel. Twisting of the pedicle of a fibroid may result in gangrene.

6. **Amyloid degeneration** of a fibroid is described by Stratz.

7. **Telangiectatic** fibroids are of rare occurrence. They are formed either from a dilatation of the lymph or blood spaces. The tumor is soft and may fluctuate.

8. **Sarcomatous degeneration** of fibroids will be discussed in the chapter on Sarcoma of the Uterus.

9. **Cancerous degeneration** is an unusual form. The epithelial elements are derived from the overlying mucosa in submucous and interstitial growths or from the glandular elements of an adenofibroma. But two cases are recorded in which the cancer began in the substance of the fibroid.

Enchondroma and osteoma are occasionally mixed with a fibroma.

CHANGES IN THE ENDOMETRIUM, MYOMETRIUM, TUBES, AND OVARIES

The *endometrium* undergoes hyperplastic changes under the irritating influence of the fibroid. Hence it is that these changes are almost invariably found in submucous, usually in interstitial, and seldom in subperitoneal fibroids. There is hypertrophy and hyperplasia of the elements forming the endometrium. In large fibroids bulging into the uterine cavity there may be pressure atrophy of the mucosa. When protruding into the vagina the endometrium may be transformed into many layers of stratified epithelium and decubitus ulcers may form upon the surface.

The *myometrium* becomes hypertrophied. This is particularly true of submucous and interstitial growths. The hypertrophy is proportionate to the size and number of the tumors.

The tubes and ovaries share in the hypertrophy to a limited extent. It is estimated that the tubes are diseased in 10 per cent. of all cases.

Clinical Characteristics of Fibroids. 1. **Shape.** A fibroid grows concentrically, and hence is usually round. The firm, sub-

serous tumors, which from their location are less influenced by the uterus, are round or oval. Submucous fibroids of softer consistency are moulded by the uterus. When forced through the cervix they become elongated and even hour-glass shaped. Interstitial fibroids confined within the uterine wall are round.

2. **Mobility.** Only pedunculated submucous and subserous fibroids move independently of the uterus. Broad ligament fibroids are restricted in their movements. Fixation by adhesions and by incarceration restricts the movements of the tumor and the uterus to which it is attached.

3. **Consistency.** The consistency of a fibroid varies from a stone-like hardness to the softness of a pregnant uterus, and may even appear to fluctuate. This variation in consistency is largely to be accounted for by the relative proportions of fibrous and muscular tissue comprising the growth. The more fibrous tissue the harder the growth. The forms of degeneration causing a hardening of the growth are atrophy (so-called fibroid degeneration), calcareous, cartilaginous, and osteomatous degeneration ; those causing a softening of the fibroid are fatty, myxomatous, cystic, œdematous, purulent, gangrenous, telangiectatic, sarcomatous, and cancerous degeneration. During pregnancy the tumor softens and grows rapidly ; after pregnancy it becomes smaller and firmer.

During the period of menstrual congestion the growth increases slightly in size and is more elastic.

4. **Rate of Growth.** The softer and more vascular the tumor the more rapid its growth. It is important to observe the rate of growth in distinguishing a growing fibroid from a pregnant uterus and in determining malignant degeneration.

Clinical Diagnosis of Uterine Fibroids. The diagnosis of uterine fibroids rests largely upon the local findings. Symptoms at best are only suggestive of their possible presence.

Subjective Signs. Two general groups of symptoms are to be considered : those due to hemorrhage, and those due to pressure and traction made by the growing tumor.

1. *Hemorrhage* in the form of an increase of the menstrual flow is usually the first event that attracts the attention of the patient. As time goes on the loss of blood may seriously undermine the patient's health, and has been known to cause death. There may be no intermission, or intervals of variable length may be interrupted by profuse and even alarming hemorrhages. It is

seldom that the loss of blood is distinctly and exclusively intermenstrual. The blood comes from the endometrium, rarely from the fibroid. The tumor acts as a foreign body irritating the endometrium. Hence it is that hemorrhage occurs almost invariably in submucous fibroids, to a lesser extent in interstitial, and seldom in subperitoneal fibroids. It is possible for a subperitoneal growth to interfere with the circulation in the uterus and indirectly cause hemorrhage. Mental excitement, physical exertion, and instrumental and digital examinations excite hemorrhage. The blood is often expelled in clots. This clotting is partly the result of obstruction to the outflow of blood by the tumor and by displacements of the uterus.

2. *Pressure* and *traction* made by the growing tumor upon surrounding structures are later developments than hemorrhage, and are not usually manifest until the tumor has attained considerable size. Subperitoneal growths are most likely to produce these symptoms. A variety of symptoms arises from direct pressure and traction. Pain is caused by pressure of the growing uterus and tumor upon the various structures in the pelvis. A fibroid incarcerated in the small pelvis may early cause pain even to an intolerable degree. Intraligamentary fibroids no larger than a man's fist may occasion distressing pain. On the other hand, large, freely movable fibroids occupying the abdominal cavity may cause no pain.

The pain is referred to the lumbar and sacral region, to the shoulders, breasts, and thighs, and rarely to the cervical and interscapular regions.

In submucous growths the pain may be due to intermittent uterine contractions excited by the growing fibroid. Such pains are usually colicky, and are most severe during the period of menstrual congestion. If, as sometimes happens, the outflow of menstrual blood is obstructed, there will be a so-called obstructive dysmenorrhœa due to intra-uterine tension and to an effort on the part of the uterus to expel the blood clots. Pain, in most cases of uterine fibroids, first manifests itself at the menstrual period when the uterus and tumor are swollen and tender from congestion.

The "birth of a fibroid"—*i. e.*, the expulsion of a submucous fibroid—is associated with labor-like pains of astonishing severity. After the flow is well started the pain may be relieved. The more abundant the blood supply to the tumor the greater will be the

menstrual swelling. Acute pain on external pressure may be experienced in the menstrual period from irritation of the peritoneum. Mechanical irritation of the peritoneum caused by the movable tumor may set up a localized peritonitis, and this in turn adds to the pain and discomfort.

Pressure of a fibroid upon the abdominal and thoracic viscera gives rise to a variety of symptoms. Pressure upon the bladder causes vesical tenesmus, frequent urination, and catarrh of the bladder. A small subperitoneal fibroid attached to the anterior surface of the uterus may cause serious disturbance in the bladder. The uterus may be compressed, leading to hydronephrosis, pyonephrosis, and uræmia. The urethra is rarely pressed upon by the tumor, though the bladder may be elevated and the urethra stretched and distorted.

Pressure upon the rectum may cause constipation, rectal tenesmus, a sense of fulness and pressure in the rectum, and a catarrhal discharge.

Pressure upon the veins of the pelvis may cause œdema and varicosities of the lower extremities.

When the tumor is large enough to fill the abdominal cavity, pressure upon the bowel and stomach will interfere with digestion, and pressure upon the diaphragm will hinder its excursions and thereby interfere with the functions of the heart and lungs. Great intra-abdominal pressure caused by large fibroids undoubtedly embarrasses the functions of the kidneys.

Torsion of the pedicle of a fibroid is possible; furthermore, it is possible for a fibroid to cause a torsion of the uterus (see Fig. 80). In this manner a fibroid may be completely twisted from the uterus. Such an event must necessarily be followed by gangrene of the tumor, unless an adequate blood supply is conveyed by the adhesions. Immediately upon the twisting of the pedicle there is severe abdominal pain, together with a sudden increase in the size of the fibroid. Vomiting and collapse follow—the clinical picture being not unlike that of a strangulated hernia, or the twisted pedicle of an ovarian cyst. When the torsion is partial or slow in its development, the symptoms will be less pronounced. When a fibroid becomes infectious or gangrenous, the event will be ushered in by a rise in temperature, chills, and pain. The tumor will be tender to pressure and increased in size. When submucous, a stinking discharge will come from the uterus. When a subperi-

toneal fibroid becomes gangrenous, the symptoms are less characteristic. Pain may be absent. Rise of temperature and tenderness on pressure are all but constant symptoms. The usual signs of peritonitis supervene when the affection spreads to the peritoneum.

Calcareous degeneration gives rise to no symptoms suggestive of the condition. There is but one sign upon which a positive diagnosis can be based, and that is the expulsion of part or all of the growth in which the calcareous deposits are found. This seldom occurs, because submucous fibroids rarely calcify and are seldom expelled.

Objective Signs. It is evident that a positive diagnosis cannot be made from the above subjective signs. From them we can only conclude that there is a swelling of some sort causing the pressure symptoms. A physical examination is indispensable in making a diagnosis.

The diagnosis is based upon the recognition of a tumor connected with the uterus and having certain fairly definite characteristics. The recognition of a fibroid of the uterus is ordinarily easy, but may be rendered difficult by various circumstances. In order that a diagnosis of fibroids be made the tumor must either be seen or outlined by the examining hands. Many conditions may exist to render such a procedure impossible, and at such times the diagnosis must be reserved until an exploratory incision has been made.

Small interstitial fibroids can only be suspected from the size and irregular consistency of the uterus. In large, interstitial fibroids there is difficulty in outlining the uterus apart from the tumor. The sound passed into the uterine cavity will locate the uterus, and when combined with a conjoined examination it should be possible to determine the existence of a fibroid and its position relative to the uterus. In outlining the respective positions of the uterus and tumor it is important to recognize their difference in form and consistency.

A subperitoneal fibroid is ordinarily identified by a conjoined examination. When the tumor is large abdominal palpation may alone be sufficient. The form, consistency, and relation to the uterus may suffice for a diagnosis. Much dependency may be placed upon the firmer consistency of the tumor as compared with the uterus, and particularly is this of importance in differentiating a fibroid from a pregnant uterus.

As with interstitial fibroids, great difficulty may be experienced

in outlining a large sessile subperitoneal fibroid from the uterus. The irregular outline, the firmer consistency, the groove or angle which may mark the connection between tumor and uterus are points which, together with the use of the sound, should suffice for a diagnosis in the majority of cases. Greater difficulty is experienced with multiple subperitoneal fibroids.

Intraligamentary or *broad ligament fibroids* are recognized by their point of attachment along the side of the uterus, by their lessened mobility, by the course of the adnexæ which run over the tumor, and by the crowding of the uterus to the side of the pelvis. The growth may spring from the supravaginal portion of the cervix or from the side of the uterine body.

Plate VI. represents a single large subperitoneal fibroid causing a rounded protuberance of the abdomen. Plate VII. represents an abdomen distended by multiple subperitoneal fibroids, in which the irregularities are plainly visible.

Submucous fibroids can only be diagnosed with certainty when they are seen protruding through the cervix, or when palpated through the cervical canal. The hemorrhage and uterine colic will suggest the possible presence of a submucous fibroid, but the diagnosis must be kept in reserve for a physical examination. Within the uterine cavity the finger detects a firm, rounded tumor connected with the uterus by a broad base or pedicle. The fibroid may be felt as a circumscribed bulging tumor upon the mucosa. With the sound or curette similar observations may be made, though with less certainty.

Fibroids of the cervix are not difficult to diagnose when attached to the vaginal portion. Their attachment to the cervix can be demonstrated by inspection or by the finger and sound. Small interstitial fibroids of the cervix are recognized by the firm, rounded, and sharply circumscribed area of resistance which characterizes their presence.

The use of the sound in the diagnosis of uterine fibroids is not to be underestimated, yet its application should be restricted to the cases in which a conjoined examination fails to clear up the diagnosis. Aside from the danger of infection, there is the added risk of perforating the uterus at a point possibly thinned by the tumor.

Great difficulty may be experienced in the passage of the sound. The tumor may be impinged upon and give the impression that the depth of the uterus is short in contrast to the usual lengthening

FIG. 142.

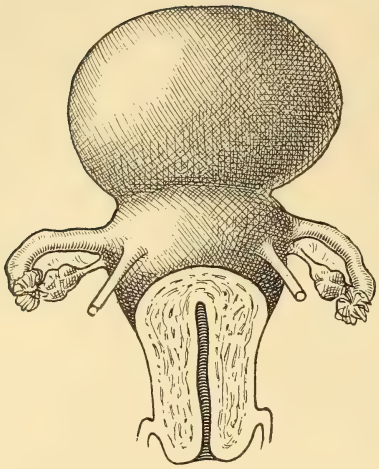

I.

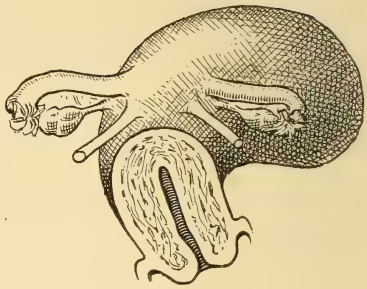

II.

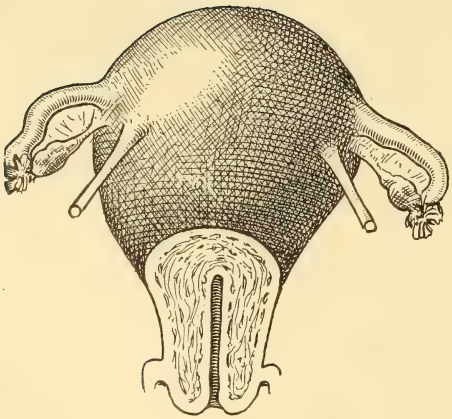

III.

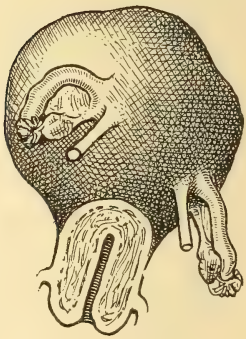

IV.

It is possible to locate a fibroid in relation to the uterus by palpating the uterine appendages and round ligaments.

I. The fibroid is subperitoneal and sits upon the fundus, hence the appendages and round ligaments are not disturbed in their relative positions. II. The fibroid is subperitoneal and sits upon the posterior wall of the uterus, and extends backward and to the left. The appendages and round ligaments are not disturbed in their relative positions. III. The fibroid is interstitial and evenly distends the uterus, hence the appendages and round ligaments are separated on the same plane. IV. The fibroid is interstitial and lies in the fundus and right cornua. The right tube and round ligaments are elevated and dislocated outward.

of the uterine cavity as found in the presence of submucous and interstitial fibroids. The shape of the uterine cavity is also to be noted by the sound. It may be encroached upon and greatly distorted, so much so that the sound cannot be passed to the fundus.

Palpation of the Adnexæ and Round Ligaments. In favorable cases the tubes and round ligaments can be palpated in a conjoined examination. It is observed that their location and point of attachment are altered by the tumor, and it is sometimes possible to locate the tumor in its relation to the uterus by observing the position of the adnexa and round ligaments.

Where the uterus is small and a larger fibroid sits upon the fundus the tumor may be mistaken for the uterus. The attachment of the tubes and round ligaments when determined will indicate the position of the uterus apart from the tumor. The sound will confirm the findings.

A submucous or interstitial growth evenly distending the uterus will separate the attachments of the round ligaments and adnexæ. An interstitial fibroid of the anterior wall will separate the round ligaments and tubes, and if to one side of the median line the corresponding tube and round ligament will be elevated above the other. An interstitial fibroid on the posterior surface of the uterus will tend to approximate the appendages.

If the fibroid is on the side of the uterus the corresponding round ligament and tube may be elevated. Fig. 142 illustrates these facts.

The diagnosis of malignant degeneration of a fibroid is discussed in the chapter on Sarcoma of the Uterus.

Differential Diagnosis. Fibroids of the uterus commonly appear during the period of sexual maturity when pregnancy, inflammatory lesions, and displacements are likely to arise, and it is for this reason that the differential diagnosis is of such importance.

Interstitial Fibroids.	Chronic Metritis.
1. Irregular enlargement of the uterus unless tumors are small.	1. Uniform enlargement.
2. Variable consistency.	2. Uniform, firm consistency.
3. Not tender to pressure.	3. Commonly tender to pressure.
4. Uterus freely movable.	4. Uterus usually restricted in its movements.
5. No history of infection.	5. History of infection.
6. Symptoms of uterine catarrh not common.	6. Symptoms of uterine catarrh generally present.

When the fibroids are multiple and small it may be impossible to distinguish such a lesion from chronic metritis. The clinical history cannot be relied upon.

Uterine Fibroid.	Uterine Pregnancy.
1. Usual signs of pregnancy absent.	1. Present.
2. Tumor of firm consistency, rarely soft.	2. Soft and elastic.
3. Intermittent uterine contractions absent.	3. Present.
4. Irregular and asymmetrical growth.	4. Rate of growth regular and symmetrical.
5. Slow growth.	5. More rapid growth.
6. Cervix firm, not patulous.	6. Cervix soft and patulous.
7. Positive signs of pregnancy absent.	7. One or more present, *i. e.:*
	a. Fœtal heart tones.
	b. Fœtal bruit.
	c. Active fœtal movements.
	d. Palpation of fœtal parts.
	e. Ballottement.

Fig. 143.

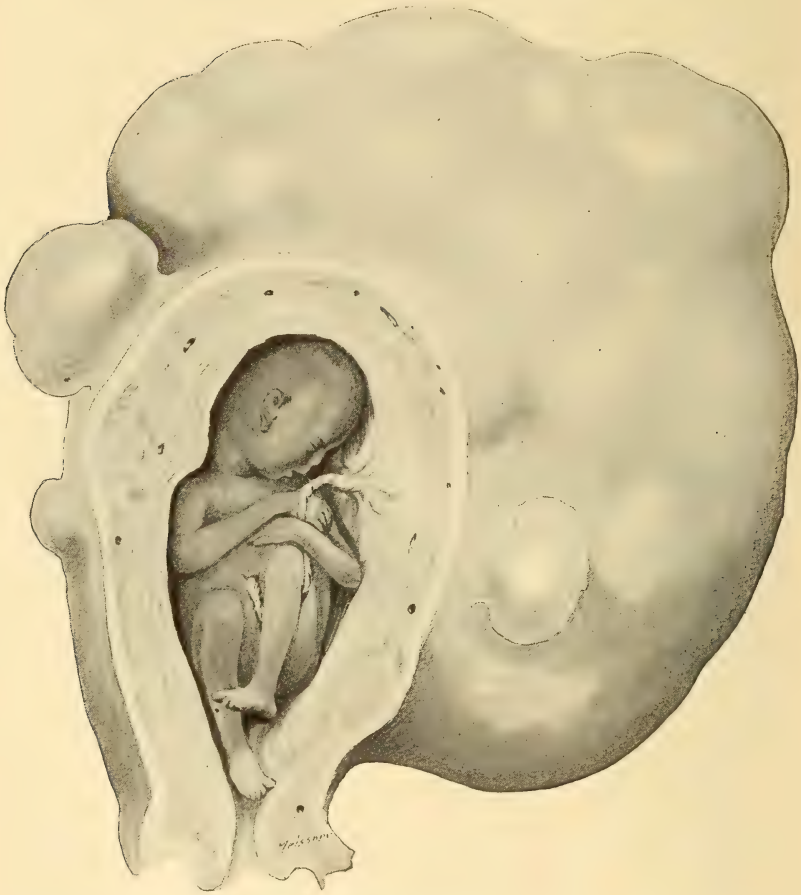

Myoma complicated by pregnancy. Complete hysteromyomectomy; recovery. (Dudley.)

Of greatest importance in the differential diagnosis of fibroids from early pregnancy is the uniform rapid growth of the pregnant

uterus, the intermittent uterine contractions and characteristic doughy consistency. Later, when positive signs of pregnancy are elicited, there should be no mistaking the fact of pregnancy.

A large, soft, interstitial fibroid may evenly distend the uterus. Its soft consistency, regular outline, and rapid growth may suggest the presence of a pregnant uterus. In addition to the above findings, there may be nausea and vomiting, enlargement of the breasts, softening and discoloration of the vaginal portion of the cervix. With such a condition it may be impossible to make a diagnosis from early pregnancy. Keeping the case under observation for a few weeks, it will be noted that the growth is slower than in pregnancy, that there are no intermittent contractions and that none of the positive signs of pregnancy develop.

But the diagnosis of fibroids complicated by pregnancy is often a difficult problem. Small subperitoneal fibroids may be mistaken for part of the fœtus. Under the influence of pregnancy a fibroid grows rapidly and becomes soft. It is, however, unusual for the growth to become as soft as the pregnant uterus, so by the circumscribed area of firmer resistance the fibroid is outlined apart from the pregnant uterus. If the examination is made during a uterine contraction this difference in consistency between the uterus and fibroid is not evident. Repeated and prolonged examinations may be required.

No tumor other than a pregnant uterus displays these intermittent contractions.

When through a morbid state of the contained fœtus the uterus remains in a state of tonic contraction, the discovery of an interstitial fibroid may be impossible. When in doubt as to the diagnosis, and the condition of the patient does not demand immediate interference, it is always advisable to await developments and make examinations at frequent intervals.

Subserous Uterine Fibroids.	Hæmatoma and Hæmatocele.
1. No history of recent pregnancy.	1. Frequently history of pregnancy.
2. Slow, continued development.	2. Sudden development.
3. Consistency firm, rarely soft.	3. Consistency at first is fluctuating, later is doughy.
4. Sharply circumscribed tumor.	4. Ill-defined tumor.
5. Exploratory puncture negative.	5. Exploratory puncture—blood obtained.

Gangrene with a fatal termination has been known to follow an exploratory puncture of a fibroid.

For the differential diagnosis of uterine fibroids from displace-

ments of the uterus, carcinoma, sarcoma, tubal and ovarian swellings, and pelvic exudates, see respective chapters on these subjects.

A case in the experience of the author, and another recently observed by Bayard Holmes, presented a soft subperitoneal fibroid near the horn of a pregnant uterus which was thought to be an ectopic gestation. In both cases the pregnancy was early; the fibroids were not discovered until the pregnant uterus began to rise out of the pelvis, bringing the tumor with it.

CHAPTER XXVI.

THE DIAGNOSIS OF CARCINOMA OF THE UTERUS.

Topographical Classification. Carcinoma may arise from any portion of the uterine mucosa, both within the uterus and covering the vaginal portion of the cervix. The classification proposed by Ruge and Veit is as follows:

1. **Carcinoma of the vaginal portion of the cervix,** including the vaginal surface of the cervix from the external os to the vault of the vagina.

2. **Carcinoma of the cervix,** including the mucosa of the cervical canal.

3. **Carcinoma of the body of the uterus,** including the mucosa from the internal os to the horns of the uterus.

It will be observed that the location of the new-growth is not only of pathological interest, but has much to do with the manner of diagnosis, the clinical manifestations, prognosis, and treatment.

Etiology. We find carcinoma of the uterus *commonly appearing about the time of the menopause.* Carcinoma of the vaginal portion more often makes its appearance immediately preceding the menopause, and carcinoma of the body usually appears a few months or years later. The earliest recorded case appeared at eight years of age. I have lately observed a case of carcinoma of the vaginal portion in a woman, aged ninety-three years.

Heredity, while playing an important rôle, is of less importance as an etiological factor than was formerly believed.

It has been said that the negress is particularly exempt from carcinoma of the uterus. Later observations tend to disprove this view, indicating that the negress is little less susceptible than the white woman.

Childbearing appears to have an important relation to the development of carcinoma of the vaginal portion. The author has seen but one carcinoma of the vaginal portion in a nullipara whose cervix has never been dilated. The patient was forty-three years of age. The uterus was removed by Dr. D. W. Graham, of the Chicago Presbyterian Hospital. The great rarity of carcinoma of the cervix

in nulliparæ speaks for the influence of trauma as a factor in the development of cancer. Carcinoma of the body of the uterus is said to be more frequent in nulliparæ.

There can be no question that *the inflammatory lesions of the uterus* (endometritis and erosions) are not seldom the starting-points of carcinoma; but that scars in the cervix are such is justly questioned. While *fibroids* and carcinoma are often associated in the uterus, it is not probable that the one is in any way dependent upon the other for its existence.

Carcinoma of the uterus is found more frequently in the lower orders of society. These classes are more susceptible to and neglectful of infections and traumatisms.

FIG. 144.

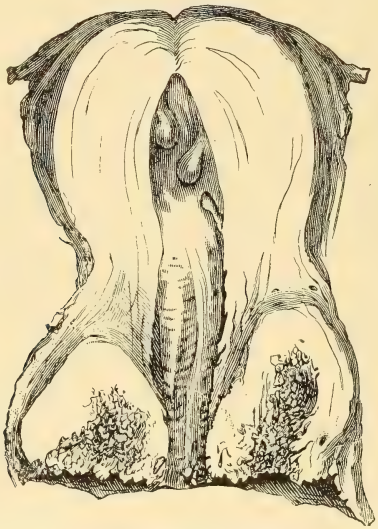

Carcinoma of the cervix involving the parenchyma of the vaginal portion. (RUGE and VEIT.)

Cohnheim's theory of cell inclusion is not supported by observations made upon the carcinomatous uterus.

Leopold concludes from a series of experiments that pure cultures of the blastomycetes may be found in fresh carcinoma of the ovary. He injected a pure culture into the testicle of a rat. The animal died, and on the peritoneum were found nodules in which were similar blastomycetic organisms. Leopold infers that this organism may be the cause of carcinoma in man.

The frequency of carcinoma of the uterus is variously stated. Welsh found that in 31,482 cases of carcinoma 29.5 per cent. were of

the uterus. In point of frequency the uterus takes second rank to the stomach as a primary seat of carcinoma. There can be no doubt but carcinoma is on the increase, though it is only fair to admit that the perfected means of diagnosis account in large part for the statistics.

Anatomical Diagnosis. I. **Carcinoma of the vaginal portion of the cervix** may tend to grow superficially into the vagina, forming a polypoid or cauliflower growth; or it may deeply infiltrate the cervix.

Fig. 145.

Carcinoma of the cervix uteri; cavity of cervix excavated. (Ruge and Veit.)

1. Cauliflower carcinoma of the vaginal portion of the cervix is seen as a sessile or pedunculated growth arising from one or both lips of the cervix. It varies in size up to the complete filling of the vagina. The surface is generally covered with a slimy, gangrenous deposit. The whole mass bleeds readily to the touch and is friable. The surface is uneven, nodular, polypoid, or villous.

2. Infiltrating carcinoma of the vaginal portion of the cervix appears in the early stage as an irregular thickening and hardening of the cervix. The anterior lip is most often first involved.

Cullen distinguishes three stages according to the degree of infiltration and disintegration of the cervix. While this classification is purely arbitrary, it will be found convenient for purposes of description.

Stage 1. *This is the stage of infiltration* in the absence of disintegration. The surface is hard, friable, and uneven. The color of the surface is glistening, bluish-white. Cross-sections of the growth show a gray or yellowish-gray surface, often cutting like cartilage. Fibrous striations are seen to course through the structure, isolating nests of friable homogeneous tissue, the so-called cancer nests. By squeezing the surface, these nests may be emptied of their cell contents, leaving small, shallow depressions. Such nests are not to be confused with Nabothian follicles filled with inspissated mucus. The two may be found in the same section. Unfortunately, cancer of the vaginal portion is seldom observed at this stage, because of the mild symptoms which prevail. Not infrequently there is an entire absence of symptoms. While impossible to say without an anatomical dissection, it is probable that the growth is still confined to the cervix. Yet it must be borne in mind that not only regional but general dissemination of the carcinoma may occur at this stage.

Stage 2. *This is the Stage of Moderate Disintegration.* The carcinomatous tissue has partially disintegrated, leaving a depression with irregular, hard, elevated margins. The base of the ulcer is uneven, and covered with a stinking slough of a grayish-yellow or gangrenous character. Upon handling the affected tissue bleeds freely and is friable. In this stage the growth is rarely confined to the cervix. More than half the vaginal tissue may be lost.

Stage 3. *This is the Stage of Complete Disintegration of the Vaginal Portion of the Cervix.* In the vault of the vagina is a sloughing, stinking, ragged crater. No cervix is to be seen or felt. The vaginal walls are invaded and form the margins of the crater. The paravaginal connective tissue, broad ligaments, and uterosacral ligaments are infiltrated. The growth is slow to pass beyond the internal os into the cavity of the uterus, but may extend to the fundus. Isolated cancerous nodules may lie in distant portions of the vaginal wall. Contact growths may develop upon opposing surfaces. The bladder is involved late, and the rectum still later, as a rule. Only in the very late stage is the peritoneum invaded. The iliac glands are the first of the lymphatics to be invaded, but

these are late in being affected and may entirely escape. Metastatic growths in distant parts of the body are seldom observed.

II. **Carcinoma of the Cervix.** Carcinoma of the cervix takes its origin from the epithelium of the cervical mucosa confined within the boundaries of the external os below and the internal os above.

FIG. 146.

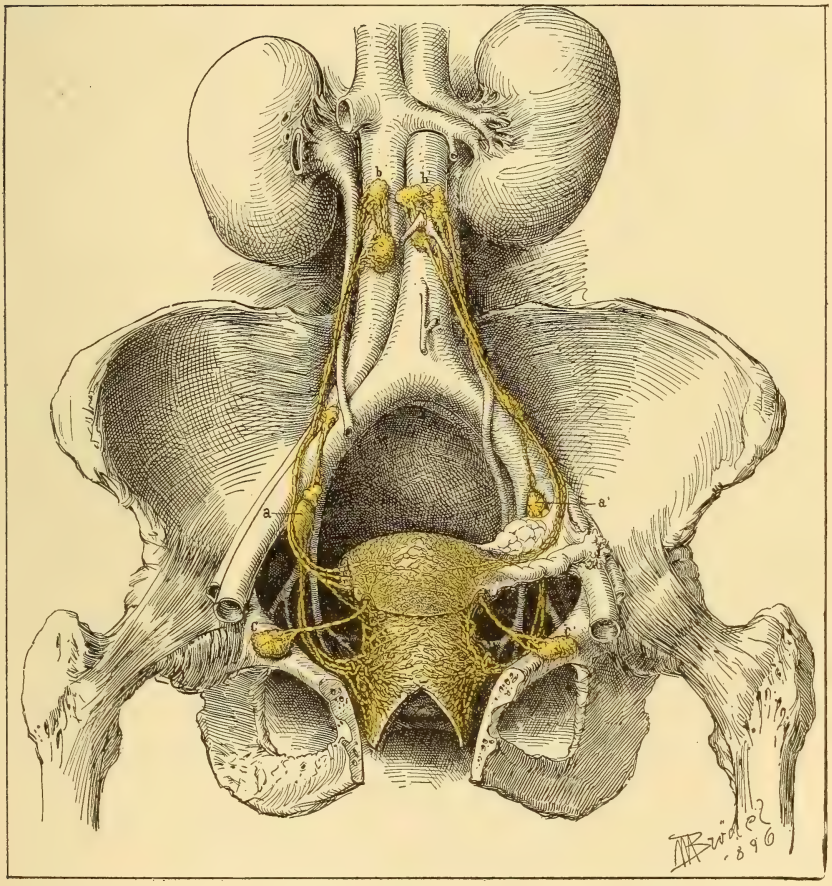

Lymphatics of uterus and upper third of vagina, and iliac and lumbar glands. (RUSSELL.)

The carcinomatous growth may involve all or a part of the mucosa. It may assume a nodular or cauliflower appearance, or may infiltrate the underlying tissue. The entire cervix may be infiltrated and will eventually disintegrate, leaving a crater-like structure with a thin shell. The lips of the cervix may close in over the growth, hiding it from view. It is seldom, if ever, that the lips

are disintegrated, but in the late stages they are infiltrated and glazed. On cross-section the carcinomatous mass is cartilaginous, yellowish-white, and glistening. The advancing border is irregular and blends into the normal tissue. The body of the uterus and vagina may be invaded either by direct extension or by metastasis.

The paravaginal connective tissue is invaded comparatively early. It is unusual to observe a case before the broad ligaments are involved, hence the prognosis is grave.

The peritoneal cavity is invaded late. The tubes, ovaries, bladder, and rectum are seldom attacked. The iliacs are the first of the lymphatic glands to be invaded. Metastasis to distant organs seldom occurs. Winter found the iliac glands involved in 22 per cent. of cases of cancer of the cervix. He found four cases of advanced cancer of the cervix without involvement of these glands. Emil Reese has made extended observations on the involvement of the lymphatic glands in cancer of the cervix. He has shown that the glands of the pelvis are often cancerous when no larger than normal. Again, they are sometimes enlarged from a hyperplasia, the result of an ulcerative process in the growth. Extensive glandular involvement contraindicates all but palliative treatment.

III. **Carcinoma of the Body of the Uterus.** Carcinoma may arise from any part of the mucosa of the uterine body, either as a circumscribed or as a diffuse growth. The surface is never smooth. It begins as a shaggy growth studded with delicate villosities, which may later enlarge and coalesce into polyps or form twig-like processes with numerous offshoots. In late and far-advanced cases the growth presents the appearance of grain tissue. The entire uterine cavity may be filled with the cancerous growth. The musculature of the uterus is very slowly invaded, and it is for this reason that cancer of the body of the uterus is regarded as relatively benign.

On cross-section the invading carcinomatous tissue, with its pale, homogeneous and glistening appearance, is in contrast to the musculature. The advancing border is irregular. When the serous covering of the uterus is invaded small grayish-yellow nodules are seen beneath the serosa. The growth is usually late in sloughing.

Extension from the body of the uterus is extremely slow. The internal os is rarely trespassed; the broad ligaments are not infiltrated until late. The peritoneum may be directly invaded, but this is late, if at all. The bladder, rectum, tubes and ovaries com-

monly escape invasion. Metastasis to distant parts of the body is late, and may never occur. Kroemer believes we find metastasis more common in carcinoma of the uterine body than of any other part of the uterus.

As to the frequency of carcinoma of the body of the uterus, Schatz says that it occurs in 2.5 per cent., and Schauta says in 13.8 per cent., of all carcinomata of the uterus.

Clinical Diagnosis. A work of this character could do no greater service than to emphasize the importance of an early diagnosis in carcinoma of the uterus, and to point out the methods of making such a diagnosis.

No departure from the normal menstrual flow should be regarded as trivial in advanced years of life. We are not to be contented with the supposition that it is a phenomenon of the change of life—too many lives have been sacrificed by such inferences.

It is the family physician, not the specialist, who first sees these cases, and it is to him we must look for the early recognition of the danger, if not for a positive diagnosis. The practitioner must be firm in his demand for a local examination. Ignorance, sloth, prejudice, and false modesty are to be discountenanced. Where the physician, after a searching examination into the cause of the hemorrhage, fails to satisfy himself, he should appeal to the specialist, whose services at this time are of greater value than in the treatment of the case, for the reason that it takes greater skill to make a diagnosis in these doubtful cases than it does to remove the uterus after the diagnosis is made. Since the early recognition of carcinoma of the uterus rests upon the microscopic examination of scrapings and excised pieces of the suspected portion, it is self-evident that only those especially trained in the work are competent to make such a diagnosis.

Symptoms in the early stage, while there is yet time to interfere, are at best only suggestive of the lesion.

Hemorrhage is usually the first of the symptoms to appear. It is at first excited by some physical exertion, such as straining at stool, lifting burdens, and sexual intercourse. All departures from the normal menstrual flow, or all losses of blood not in relation to the menstrual period, call for a careful examination. The older the individual the greater the probability of carcinoma. In carcinoma the loss of blood is at first slight; rarely does it begin with a profuse flow. A watery discharge may precede the flow of blood weeks

and months, and is highly suggestive of carcinoma. The patient becomes anæmic, and strength fails as a result of the hemorrhage.

Leucorrhœa is almost invariably present, at first in the form of a watery, odorless discharge, later as a thicker white or yellowish fluid, and, finally, of a stinking, dirty, bloody discharge. Such a discharge can only be regarded with suspicion; it is in no sense pathognomonic. Sloughing fibroids, decomposing placental tissue, and senile endometritis may cause a similar discharge. As in hemorrhage, so with such a leucorrhœa, a careful examination is imperative.

Pain is seldom an early manifestation of carcinoma of the uterus, and is less reliable as a guide to diagnosis than is hemorrhage or leucorrhœa. Not infrequently the growth is far advanced before pain is experienced. In such cases the pain begins when the growth has extended beyond the uterus. Pain and hemorrhage are often in inverse proportion. The pain is aggravated by the congestion, and when the flow of blood is considerable the congestion is relieved and this in turn lessens the pain.

Miscellaneous symptoms arise from extension to the surrounding structures. The bowels become constipated, and defecation is painful from the pressure of the growth. As the rectum is invaded a mucous or mucohemorrhagic discharge comes from the rectum; finally, a rectovaginal fistula develops. Invasion of the bladder causes frequent urination, irritability of the bladder, bloody urine, and, finally, a vesicovaginal fistula.

When the cellular tissue of the pelvis is involved there may be pain referred to the groin, thighs, and legs. Œdema of the legs, often of one side, may result from an involvement of the veins and lymphatics of the pelvis. In almost every case of advanced carcinoma of the uterus the kidneys are involved and uræmic symptoms may be manifest.

Cachexia develops in the advanced stage, though it may be surprisingly late in making its appearance. The above symptoms are responsible for the cachexia.

I. **The diagnosis of carcinoma of the vaginal portion of the cervix** can be made with greater ease and certainty than in any other portion of the uterus, because of the greater accessibility to touch and sight.

In the infiltrating form with an overlying covering of mucous membrane the diagnosis is difficult without the aid of the micro-

scope. The broadening of the cervix, the irregular nodular surface, the cartilaginous consistency, and the glistening, bluish color are not sufficiently characteristic. The friability and tendency to bleed when grasped by a tenaculum or when the finger-nail is gouged into it, are regarded by many of large clinical experience as characteristic of cancer, and altogether reliable in making a diagnosis. While much reliance can be placed on these signs, the microscopic examination of an excised piece of the suspected portion must be regarded as the conclusive test, without which a positive diagnosis is often impossible. When ulceration follows the diagnosis is made with greater ease. The hard, glistening, irregularly elevated border, together with the friability and tendency to bleed when handled, leaves little doubt as to the carcinomatous nature. There is then little need for the microscope to confirm the diagnosis.

A cauliflower growth is more readily recognized as malignant than the infiltrating form, yet papillary erosion must be excluded, and to make a careful differentiation the microscope will often be found indispensable. The greater the clinical experience of the examiner the larger will be the percentage of cases in which the diagnosis can be made from the clinical signs and symptoms. But there will remain a certain number in which the diagnosis can only be made by a microscopic examination of an excised piece of the suspected portion. (See Microscopic Diagnosis, page 289.)

II. **The diagnosis of carcinoma of the cervix** is rarely made early, because the growth is not accessible to the sense of touch or sight, hidden as it is above the external os. Indeed, the growth may go on to an advanced stage, destroying the mucous membrane and underlying connective tissue, and yet be unsuspected. Where the destruction of tissue is seen through a vaginal speculum the diagnosis is not difficult, but this is not possible in the early stage when a radical cure is assured.

When the cervix is artificially dilated bleeding is profuse and tearing can scarcely be avoided. The finger or curette gouges out friable masses. The friability and bleeding of the tissue are so characteristic as to leave little doubt of the carcinomatous nature of the growth. It is scarcely necessary to resort to the microscope to confirm the diagnosis.

III. **The diagnosis of carcinoma of the body of the uterus** presents the greatest possible difficulties. There are no symptoms that may be regarded as pathognomonic; the lesion is beyond the reach of

the examining finger, and cannot be brought under inspection. The general nutrition of the individual bears little relation to the stage of the growth. She may retain her weight into the last stage.

Hemorrhage, a foul-smelling discharge, and pain occur in the order named, but it is possible for one or all of these symptoms to be absent, and more often there is nothing in the symptoms to suggest anything more serious than endometritis.

If every menstrual irregularity occurring late in life, and every intermenstrual or postmenopausal hemorrhage were regarded with suspicion of carcinoma, and a thorough search made into the cause, few carcinomata of the uterus would long go unrecognized.

It is usual for the menstrual periods to have been regular, for the menopause to have passed in the ordinary way, and for some months or years to have intervened before the appearance of hemorrhage. The author lately saw a case in which the menopause had been passed forty-eight years when hemorrhage returned. Even with this long interval the patient and friends thought the loss of blood was due to a return of the menses. Their suspicions were confirmed to their entire satisfaction when the flow of blood ceased in a few days and returned in four weeks. This disposition on the part of the patient to believe that postmenopausal hemorrhages are the return of the menses is too frequently responsible for the high rate of mortality in carcinoma of the uterus.

There is little difference in the subjective signs of carcinoma of the body of the uterus and those of the cervix or vaginal portion. The constitutional effects appear much slower. It is impossible to say when the growth begins. We commonly date the appearance of the carcinoma from the time of the onset of the watery discharge or hemorrhage, but it is to be borne in mind that these symptoms may be due to endometritis which has not as yet developed into a malignant growth; and, on the other hand, these symptoms may follow weeks and months after the beginning of malignant degeneration. The slow growth of carcinoma of the body of the uterus is illustrated by a case of Cullen's, in which the hysterectomy was performed two years after the onset of symptoms, and in which the disease was seen to have made little progress.

In a case operated upon by Dr. J. Clarence Webster the symptoms began three years previous to the operation. The growth was still apparently confined to the body of the uterus.

We now see that the subjective signs cannot be relied upon in

making a diagnosis, and that we must depend largely upon physical signs.

Bimanual palpation of the uterine body shows a slight uniform enlargement, together with some degree of softening. In the early stage the size and consistency of the uterus is not changed. In the advanced stage, when the growth has extended to the serosa, small nodules may be palpated on the outer surface of the uterus, giving the impression of small subperitoneal fibroids.

Exploration of the uterine cavity is essential to a positive diagnosis. This is accomplished by the examining finger, the sound, or the curette.

After dilating the cervix sufficiently to admit the index finger, the entire surface of the endometrium can be explored. Soft, friable, and irregular elevations upon the surface are located, and may be scraped off by the finger for a microscopic examination. It is possible in the early stage for a growth that is not distinctly raised above the surface to escape the examining finger.

The uterine sound will detect the irregularities upon the surface of the endometrium with less certainty, and will afford much less intelligent information regarding the consistency and extent of the growth. In carcinoma the sound will sink into the soft growth and cause considerable bleeding.

An exploratory curettage followed by a microscopic examination of the scrapings will supply an absolute means of making a diagnosis, and should be made in every case, no matter what the other findings may be.

Microscopic Diagnosis of Carcinoma of the Uterus. We have learned that an early diagnosis of carcinoma of the uterus is seldom made from clinical manifestations or from the naked eye appearances of the growth; that the only positive means of making an early diagnosis is by a microscopic examination of excised pieces and of scrapings removed by the curette.

I. **Carcinoma of the Vaginal Portion of the Cervix.** In advanced cases where there is ulceration of the cervix and where the vagina and parametrium are infiltrated, a microscopic examination is seldom necessary. In the early stage no characteristic features may be observed by the naked eye, and it is in such cases that the microscope is indispensable.

The technic of excising a piece of the cervix for a microscopic examination is to sterilize the vagina as for a vaginal operation;

grasp the cervix with a tenaculum and with knife or scissors remove a wedge including part of the suspected portion and part of the apparently healthy tissue. Following the incision catgut sutures are used to close the wound, and the vagina is packed with gauze. An anæsthetic is desirable, though not absolutely necessary.

Fig. 147.

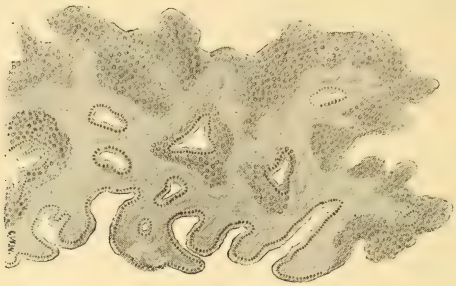

The microscopic appearance of an infiltrating squamous-cell carcinoma of the cervix is that of many layers of flat epithelium varying greatly in size and in form from the normal epithelium of the vaginal portion. The cells may be no larger than a leucocyte, or considerably larger than normal. The nuclei are relatively large, often segmented. They take a deep stain and show many karyo-

Fig. 148.

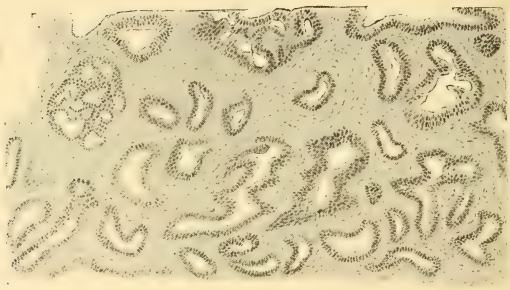

kinetic figures. A variable amount of protoplasm surrounds the nuclei. The cells, grouped in irregularly projecting columns, invade the underlying tissues and may finally wholly replace the cervix. About the margins of these projecting columns is a round-cell infiltration of the connective tissue stroma. Cross-sections of these epithelial columns appear as "cancer nests" (Fig. 154), and in them "cancer pearls" (Fig. 153) are found.

The microscopic diagnosis of a cauliflower carcinoma of the vaginal portion of the cervix is to be made from an excised piece of the suspected portion. The sections must be made perpendicular to

FIG. 149.

Papillary carcinoma of the cervix.

FIG. 150.

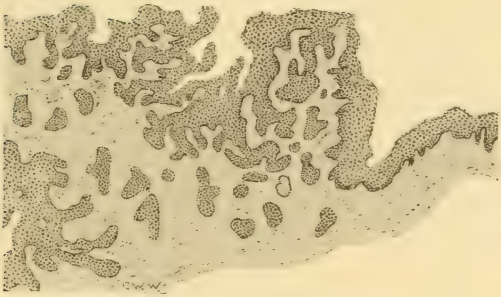

Squamous-cell carcinoma of the cervix.

FIG. 151.

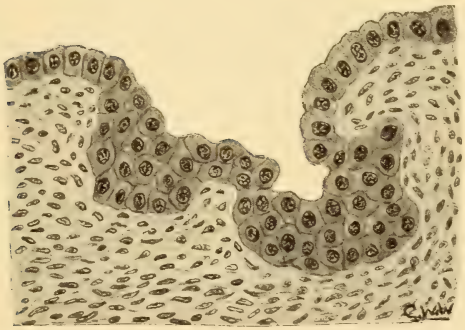

Proliferation of the superficial columnar epithelium. The new-formed epithelium is seen to invade the connective tissue in the act of forming a malignant gland.

the cervix, in order to observe the epithelial invasion of the latter. The finger-like projections which aggregate to make a cauliflower growth are composed of a framework of connective tissue which contains a central bloodvessel, many round cells, and a variable number of invading epithelial cells (Fig. 155). The surface is covered with many layers of squamous epithelium not unlike those described above in the infiltrating form of carcinoma. The epithelium invades the underlying connective tissue of the cervix, and it is this feature that gives the malignant character to the growth. Cancer nests may show various stages of degeneration. Giant cells are relatively abundant. Hyaline degeneration of the cancer cells is common and the nuclei may be fragmented.

FIG. 152.

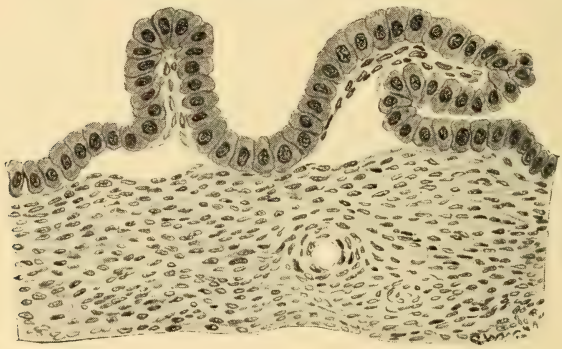

Proliferation of the superficial columnar epithelium. The new-formed epithelium extends outward, forming papillary projections into which connective tissue fibres project to form a framework. There is no invasion of the connective tissue. The figure represents the beginning of a malignant papillary growth.

Erosion carcinoma is a term implying malignant degeneration of an erosion of the cervix. The malignant changes commonly begin on the surface of the erosion, less frequently from the glands and follicles. In this way it is possible to have cylindrical-cell carcinoma in the vaginal portion of the cervix.

II. **Carcinoma of the Cervix.** Two general histological forms of carcinoma of the cervix are recognized—alveolar and glandular. These forms take their origin from the surface epithelium or from pre-existing glands. In either form the wall of the cervix may be deeply infiltrated and the cervical canal filled. Ruge and Veit describe a budding process in the development of malignant gland formations. Groups of epithelial cells bud from either side of the

lumen of a gland and unite to form a bridge across the gland. Eventually the lumen of the gland may be filled with epithelial cells.

In no essential way does carcinoma of the cervix differ from carcinoma of the body of the uterus.

FIG. 153.

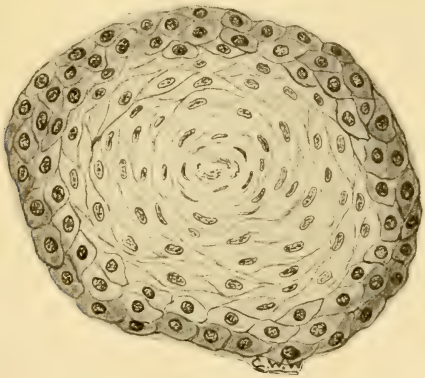

Cancer pearl composed of concentric layers of hornified epithelium.

III. **Carcinoma of the Body of the Uterus.** In carcinoma of the body of the uterus we see a great variety of histological forms. In general there are found the adenocarcinoma and the alveolar, very rarely the squamous-cell carcinoma.

FIG. 154.

Cancer nest with a necrotic centre.

Adenocarcinoma may assume a type sometimes spoken of as malignant adenoma—*i. e.*, a glandular growth in which the glands are greatly increased in number and invade the musculature. There is but a single layer of epithelium, and the glands are very irregular in outline and often increased in size. It is difficult to

differentiate an early malignant adenoma from an advanced type of hyperplastic glandular endometritis, or what is sometimes called a benign adenoma. Gebhard describes two varieties of malignant adenoma—the everted form, in which the glandular irregularities project outward from the lumen; and the inverted form, in which the irregularities project into the lumen of the gland. The two forms are often combined.

FIG. 155.

A finger-like projection of a squamous-cell carcinoma of the cervix.

When in addition to irregularity in outline and great increase in the number of the glands the epithelium proliferates to form two or more layers and the basement membrane is broken through, we have formed the *adenocarcinoma.*

Alveolar carcinoma may form by the complete filling up of the

gland lumen in the advanced stage of adenocarcinoma, or the surface epithelium may invade the underlying tissue, giving rise to the formation of "cancer nests."

SQUAMOUS-CELL CARCINOMA OF THE BODY OF THE UTERUS.

There are but few authentic cases of squamous-cell carcinoma of the body of the uterus reported. To deny the possible existence of such growths, as does Cullen in his admirable work on *Cancer of the Uterus*, is unwarranted from a study of the recorded cases. That multiple layers of squamous epithelium of a perfectly benign character are found has been well established by Veit, Gebhard, Ries, and others. It is only reasonable to infer that such benign metamorphosis may in turn become transformed into squamous-cell carcinomata.

Zeller, in 1885, observed in the scrapings of all forms of endometritis isolated areas of stratified squamous epithelium showing none of the characters of a malignant growth. Gebhard and Menge made similar observations in gonorrhœal endometritis. Werth examined the mucosa ten days after curettage, finding islets of squamous epithelium in the mouths of glands. Gottschalk and Winkler record similar observations in the endometrium of pregnancy in the fifth and third months, respectively. Optiz and Gebhard found small papillary elevations in the decidua, composed of three or four layers of squamous cells. Meier and Friedländer made observations on the uteri of fœtuses and infants, in which they demonstrated isolated patches of squamous epithelium, four to six layers in thickness, the lowermost layer being cylindrical, the uppermost layer hornified, and the intermediate layer cubical in form. Heugge reports two cases, forty-four and forty-nine years of age, in which curettage was performed for the control of hemorrhage. In both were found transformation and proliferation of the epithelium into stratified squamous epithelium, occupying the glands and the surface of the mucosa.

In none of the above recorded cases was there evidence of malignancy. The benign metamorphosis occurred from the ninth month of fœtal life to the forty-ninth year. Bebkiser, Hofmeier, and Gebhard each described a case in which the benign stratified epithelium became transformed into a malignant squamous epithelial growth. Kaufman curetted the uterus of a woman, aged sixty-

four years, who had suffered from uterine hemorrhage six years. In the scrapings were typical fields of adenocarcinoma, together with nests of squamous-cell carcinoma containing cancer pearls.

It is probable, as Winter says, that these growths never arise directly from cylindrical epithelium. It is more likely that through mechanical, chemical, and myotic influences the cylindrical cells proliferate, become flattened, and subsequently undergo malignant transformation.

Plate XXXVI. is drawn from a specimen removed by Dr. J. Clarence Webster in the Presbyterian Hospital of Chicago. In the specimen is an interstitial fibroid of the uterine body lying directly posterior to a cauliflower growth of the endometrium. This endometrial growth is about two inches in diameter, is soft and friable, and shows no visible degenerative changes. The remainder of the endometrium is apparently normal. Microscopic sections show an adenocarcinoma; typical in form and intimately associated with malignant glands are areas of apparently squamous-cell carcinoma. In the field will be seen glands partially filled with flat epithelium, and cells showing transition stages from the cylindrical to the flat cells. No cancer pearls are found. After a thorough search throughout the endometrium not involved in the cauliflower growth, I could find no evident metamorphosis of the surface epithelium. It is probable that the existence of the flat epithelium may be accounted for by the presence of the encroaching fibroid—a result of pressure.

I. **Differential Diagnosis of Carcinoma of the Uterus.** **Carcinoma of the vaginal portion of the cervix** is to be differentiated from eversion of the mucous membrane, erosions of the cervix, decubitus, tuberculous and syphilitic ulcers, follicular degeneration of the cervix, metritis coli, and sarcoma.

Eversion of the mucous membrane of the cervix follows laceration of the cervix. Viewing the cervix through a speculum, the eversion is often exaggerated by the traction made by the speculum upon the cervix. Grasping the two everted lips of the cervix with tenacula and bringing them together the everted mucous membrane is rolled in, leaving a normal appearing cervix. The suspected portion is not friable, and does not bleed freely when handled. Finally, if a section of the everted mucosa is examined under the microscope, it is seen to be either normal or hypertrophied. There is no evidence of an epithelial invasion of the underlying tissue.

PLATE XXXVI.

Combination of squamous-cell carcinoma and adenocarcinoma of the corpus uteri.

Erosions of the cervix (mucous patch) may be confused with carcinoma when having a papillary surface or when deeply indurated. Erosions seldom bleed so freely as does carcinoma, and the tissue is less friable. Where doubt exists a microscopic examination of an excised piece of the suspected portion will confirm the diagnosis. No epithelial invasion will be found beneath the basement membrane.

Decubitus ulcers of the cervix due to pressure from ill-fitting pessaries and friction of the cervix and thighs in prolapsus uteri are recognized by their punched-out appearance, the absence of hard, elevated margins, the granular bed in the absence of induration, and, finally, by a microscopic examination of excised pieces of the ulcers in which there is found no epithelial invasion of the underlying structures. On removal of the pessary and replacing the prolapsed uterus there is a tendency to healing, which is never present in carcinomatous ulcers.

Tuberculous ulcers of the cervix are rare as compared with carcinoma. A tuberculous family history, the presence of tuberculosis elsewhere in the body, and particularly in the upper genital tract, will suggest the possible nature of the lesion. The tuberculous ulcer has a ragged, undermined margin in contrast to the hard, elevated margin of a carcinomatous ulcer. The bed of the ulcer is not indurated as in carcinoma, and may be studded with tubercles and covered with a yellowish secretion. Miliary tubercles may surround the margins of the ulcer. There is not the tendency to bleed when handled, nor is the tissue so friable as in carcinoma. Finally, a microscopic examination of excised pieces will reveal the tubercles, giant cells, and possibly the tubercle bacillus, and there will be an absence of deep invasion by the epithelium. There is a tendency to heal by cicatrization not seen in cancerous ulcers.

Bayea speaks of ulcerative, miliary, papillary, and hyperplastic tuberculous endocervicitis. Papillary tuberculous endocervicitis, according to Bayea, is distinguished from a cauliflower carcinoma by the following:

1. Not bleeding so freely or so early as carcinoma.
2. More elastic and velvety and less friable than is carcinoma.
3. Commonly occuring during the period of sexual maturity, while carcinoma occurs later.
4. Great variations in history and in duration.
5. Microscopic examination showing lesions typical of tuberculosis and the absence of epithelial invasion.

A syphilitic ulcer is single, shallow, and deeply indurated; the bed of the ulcer is covered with a grayish-yellow deposit, and the margins are not elevated but are described as serpiginous. There is a tendency to heal by cicatrization. Multiple ulcerated papules may be present. Under the microscope there is noted an absence of epithelial invasion of the cervix.

Follicular degeneration of the cervix, or, what is commonly known as a follicular erosion, is described on page 251. The cervix may be considerably enlarged, irregular, and nodular. Cutting into the irregular elevations, inspissated mucus escapes. The suspected tissue is tough, not friable as in carcinoma, and does not bleed when handled. The microscope shows distended glands, with an intact, overlying mucosa not invading the underlying connective tissue.

An interstitial fibroid of the cervix is commonly associated with similar growths in the body of the uterus. The tumor is firm, sharply circumscribed, and shows no tendency to friability and bleeding. On cross-section and under the microscope a fibrous or fibromuscular structure is seen.

Metritis coli is a chronic inflammation of the cervix causing such thickening and hardening of the tissue as to suggest malignant infiltration. The enlargement is uniform as contrasted with the irregular growth of the carcinomatous cervix; there is an absence of the cartilaginous firmness of the cervix of the first stage of carcinoma, and there is no bleeding on handling. In doubtful cases a section of the suspected tissue should be submitted to the microscope.

Sarcoma of the cervix cannot be diagnosed from carcinoma without the aid of the microscope. The clinical history and the naked eye appearance of the growth will not suffice for a diagnosis.

Abel lately claims to have hit upon a valuable diagnostic point in squamous-cell carcinoma of the cervix. He finds by the Weigert resorcin-fuchsin stain the presence of elastic fibres surrounding the nests of epithelium and running between individual epithelial cells. In benign epithelial growths, such as condyloma of the cervix and papillary erosions, elastic fibres are found at the margins of epithelial groups and do not run between individual cells.

II. **The differential diagnosis of carcinoma of the cervix** is made from mucous polyps, submucous fibroids, and cystic degeneration of the glands of the cervix. In all of these the absence of friability, the slight bleeding when handled, finally, and conclu-

sively, a microscopic examination of the suspected tissue, determine its identity.

III. **The differential diagnosis of carcinoma of the body of the uterus** is from endometritis, submucous and interstitial fibroids, retained placental tissue, syncytioma malignum, hydatiform mole, arterio-sclerosis, sarcoma, and endometritis.

Endometritis may closely resemble carcinoma of the body of the uterus in its clinical manifestations, and in its macroscopic and microscopic appearances.

The symptoms of endometritis may be identical with those of carcinoma. In both of these lesions all symptoms may be absent or so insignificant as not to concern the patient.

A naked eye examination of the endometrium after removal of the uterus or of scrapings removed from the uterus, while sufficiently characteristic in many cases, may be altogether misleading. It not infrequently happens that the only way to make a positive diagnosis is by the aid of the microscope. Indeed, *it is only by an exploratory curettage and a microscopic examination of the scrapings that an early diagnosis of carcinoma of the uterus can be made.*

Carcinoma of the body of the uterus is so insidious in its development and so slow in its progress that it becomes imperative to regard with suspicion all hemorrhages, however slight, when occurring late in life, and to advise an exploratory curettage when the cause of the hemorrhage is not accounted for.

In making a microscopic examination of suspected scrapings from the uterus we are to determine whether the glands are more irregular in outline than the glands of hyperplastic and hypertrophic endometritis ; whether they are so increased in number as to do away with the interglandular connective tissue to an extent not observed in endometritis, and, finally, whether the epithelium is proliferated and broken through the basement membrane and is found within the interglandular connective tissue. These three findings—that is, great irregularity of the glands, great increase in number of the glands, and proliferation of the epithelium beyond the basement membrane—serve to distinguish adenocarcinoma and malignant adenoma from glandular endometritis. One, two, or all three of these features may be found, and are to be regarded as characteristic. The last, however, is by far the most reliable. Occasionally there will be found a specimen, the character of which cannot be determined with certainty. Such cases should either

be treated as if malignant or should be kept under close observation.

Submucous and interstitial fibroids may present all the clinical evidences of malignancy. This is especially true in gangrene of the fibroid. Hemorrhage, leucorrhœa, pain, and emaciation may all be in evidence, and suggest the presence in the uterus of a malignant growth. An exploratory curettage and a microscopic examination of the removed particles will establish a diagnosis.

A fibroid bulging into the uterine cavity may be identified by a sound, curette, or the examining finger. It is to be borne in mind that fibroids and carcinoma may coexist in the body of the uterus, and we are not to be content with the finding of any single cause for the symptoms, but are to exclude all possible causes.

Retained Placental Tissue. Portions of the placenta may be retained in the uterus an indefinite length of time—weeks, months, and years after the termination of labor and abortion. Hemorrhage, leucorrhœa, and pain may result, giving a clinical picture that may be mistaken for carcinoma of the body of the uterus. The lesion is most likely to be found during the period of sexual maturity, while the symptoms of carcinoma of the uterine body seldom appear before the climacteric period, and more often some time after the menopause.

A positive diagnosis can only be made by an exploratory curettage and a microscopic examination of the scrapings. In recent cases the placental tissue may be recognized by the naked eye, but in cases of long standing mere shadows of placental tissue may be recognized by the microscope The presence of decidual cells and chorionic villi in the scrapings determines the diagnosis.

The glands of pregnancy are so varied and irregular in form as to suggest the possibility of malignancy where pregnancy has not been suspected. The interglandular connective tissue may be almost entirely lost by pressure of the enlarged glands. The glands seldom run at right angles to the surface and may run almost parallel. Their outlets are constricted by the surrounding decidual cells, while their deeper portions are widely distended. As a rule, a single layer of epithelium lines them, but more than one layer is occasionally found. The epithelium is flattened or cuboidal. A number of layers of flat epithelium have been observed in the glands. There is, however, no invasion of the interglandular connective tissue by the epithelium, and herein lies the differentiation

from malignant glands. The finding of decidual cells surrounding the glands will suggest their character.

Mucous polyps of the uterus are frequently the cause of hemorrhage. While more common during the age of sexual maturity, they may be found at any age, even years after the menopause. The microscopic picture does not differ essentially from that of endometritis. The absence of epithelial proliferation and invasion of the underlying connective tissue will exclude carcinoma.

The decidua of ectopic pregnancy may be confused with carcinoma where pregnancy is not suspected. The scrapings from the uterus of an ectopic pregnancy may appear to the naked eye not unlike those from a carcinoma. Viewed under the microscope no doubt should arise. In association with the decidual cells are the glands of pregnancy, giving a picture not to be confused with carcinoma.

Tuberculous endometritis may closely simulate carcinoma in its clinical and anatomical features.

Tuberculosis of the endometrium usually occurs early in life as compared with carcinoma of the uterus. There may be a family history of tuberculosis, or tuberculous foci may be found elsewhere in the body. If found in the tubes, it is altogether probable that the endometrium will be involved. In exceptional cases the diagnosis can be made from cover-slip preparations of the leucorrhœal discharge. To the naked eye the endometrium may present the characteristic ulcers and tubercles, but in general it may be said that in the absence of tuberculosis in other portions of the genital tract, the lesion can only be diagnosed from endometritis or carcinoma by microscopic examinations of sections taken from the uterus after removal, or from scrapings. The finding of tubercles, giant cells, or tubercle bacilli and the absence of epithelial invasion of the connective tissue will complete the diagnosis. The picture is distinctly that of an inflammatory reaction.

DIAGNOSIS OF EXTENSION OF CARCINOMA OF THE UTERUS.

It is of prime importance to determine whether or not the carcinoma is confined to the uterus. This should always be done before the diagnosis can be considered complete and before determining upon radical procedures in treatment.

It is now generally conceded that the entire uterus must be removed for carcinoma involving any part of the organ ; hence it is

no longer a question as to how much of the uterus is involved in the growth, but rather as to whether it is confined to the uterus or has spread to the surrounding structures. We look to the parametrium, vagina, bladder, rectum, lymph glands, and internal organs for secondary growths.

The parametrium, particularly that portion of the cellular tissue found betwen the layers of the broad ligaments, is involved comparatively early. In carcinoma of the cervix and vaginal portion the base of the broad ligament is invaded. The infiltrated tissue is felt as a "board-like" mass, irregular and nodular in outline, firmly fixed, and not tender to pressure. The cervix is crowded to the opposite direction.

The examination is best made under anæsthesia. Two fingers are placed in the rectum, the thumb in the vagina. Counter-pressure is made over the abdomen by the other hand. The cervix and area of infiltration will be found as one mass. The cervix will be immovable. This immobility of the cervix does not necessarily signify a carcinomatous invasion ; it may well be inflammatory.

Inflammatory swellings of the tubes and ovaries fixed by the side or behind the uterus may be mistaken for carcinomatous infiltration. Such swellings are more tender to pressure, are less cartilaginous in consistency, have not the same intimate connection with the cervix, and are commonly located on a higher plane.

Still greater difficulty is experienced in differentiating carcinomatous infiltration of the parametrium from pelvic cellulitis. In the latter there is greater tenderness, the outline is flatter and less nodular, and there may be no direct and immediate connection between the carcinomatous lesion in the uterus and the infiltrated parametrium. The cervix is crowded away from the growth, while in parametritis the cervix is drawn to the infected side.

It is difficult to demonstrate carcinomatous infiltration of the connective tissue occupying the vesico-uterine space. Usually it is not possible until an incision is made into the region. The uterosacral ligaments may be infiltrated. The characteristics of the lesion and the differentiation from an inflammatory involvement of the same structures are as found in invasion of the broad ligaments.

The vagina is invaded by direct extension, seldom by metastasis.

Since carcinoma of the vaginal portion more often begins in the anterior lip, the anterior wall of the vagina is frequently first attacked. The infiltrated vaginal wall is readily recognized by the

finger and by examination through the speculum. The infiltrated area in the vagina is directly continuous with the growth in the cervix. The margins of the infiltrated area are elevated, hard, and irregular. Ulceration follows in the late stage, and such ulcers show the irregular, elevated margins and the uneven base which bleeds freely on being touched. Metastatic growths may be found at any point in the vaginal walls, more often in the posterior wall. Such growths are hard and nodular, and may attain the size of a walnut.

When the paravaginal tissue is infiltrated it is possible to move the vaginal mucous membrane independently of the underlying growth.

Spiegelberg's sign is of some value in recognizing a carcinomatous infiltration beneath an intact mucous membrane. Passing the finger over the surface the mucous membrane feels like wet rubber, having lost its normal pliability.

Invasion of the bladder is secondary to that of the anterior wall of the vagina. It is clinically recognized by frequent and painful urination, blood in the urine, and, finally, by the dribbling of urine into the vagina through a vesicovaginal fistula. An early diagnosis is made by cystoscopic examination. The area of infiltration and the ulcers are distinctly detected, and when associated with advanced carcinoma of the cervix there can be no hesitancy in making the diagnosis of extension of the carcinoma to the bladder.

The rectum is invaded after the growth has spread to the posterior vaginal wall. The symptoms indicating invasion of the rectum are a mucous discharge which is often stained with blood, rectal tenesmus, constipation alternating with diarrhœa, and a discharge of feces through the vagina after the development of a rectovaginal fistula. A digital exploration of the rectum and vagina reveals a hard, infiltrated area in the rectovaginal septum, which bleeds and may crumble to the touch ; the mucous membrane of the rectum has lost its pliability, and cannot be moved independently of the underlying structures ; and, finally, a section removed for microscopic examination determines the diagnosis.

Metastatic growths are seldom early in making their appearance. Experience teaches us that it is never possible to say with absolute certainty that metastasis has not occurred even in the apparently early growths. The ovary is sometimes the seat of metastasis. Of the abdominal and thoracic viscera those most often involved are

the lungs and liver. In carcinoma of the uterine body the lumbar glands are first involved. If the horn of the uterus is invaded the deep inguinal glands may be attacked by way of the round ligament. In carcinoma of the cervix, the vaginal portion of the cervix and the upper segment of the vagina, the iliac glands lying in front of the sacro-iliac synchondrosis at the bifurcation of the common iliac vessels are first invaded. In carcinoma of the vulva and lower segment of the vagina the inguinal glands are first attacked. It is of the greatest importance to recognize involvement of the lymphatic glands in settling the question of operative interference.

The diagnosis of recurrence after removal of the uterus is of great importance. A recurrence implies failure of having thoroughly removed the primary focus.

Winter speaks of *local recurrence* when the secondary development is in or near the previous field of operation ; of *lymph gland recurrence* when the lymphatic glands of the body are involved subsequently to the operation, and of *metastatic recurrence* when the carcinoma spreads by way of the blood stream to distant parts of the body.

The great liability of recurrence in carcinoma of the uterus admonishes us to always give a guarded prognosis, no matter how early and thoroughly the operation may have been performed.

The general symptoms indicating a recurrence are loss of flesh and strength, cachexia, foul-smelling leucorrhœa, irregular hemorrhages, and pain in the pelvis radiating to the thighs, groin, rectum, back, and abdomen. A positive diagnosis can only be made from a physical examination. Local recurrence in the tissues about the uterus is recognized by the cartilaginous consistency of the areas of infiltration in the vagina and broad ligaments.

Granulation tissue in the scars at the end of the stumps may be regarded with suspicion. They are seldom so hard and friable as carcinoma, and a microscopic examination of an excised piece or scraping will determine the diagnosis. It is not always possible to say of enlarged glands that they are so from carcinomatous involvement. It is possible that their enlargement is the result of infection.

ENDOTHELIOMA.

By endothelioma is meant a malignant new formation arising from the endothelium of blood and lymphatic vessels and from

serous surfaces. Endothelioma appears at any time in life. The earliest reported case is that of Braetz, at eighteen years of age.

Such growths differ from carcinoma and sarcoma, not only in their histogenesis, but also in their histological structure.

In their gross appearance there is nothing distinctive. Under the microscope the lumina of blood and lymph spaces are seen to be distended with rapidly proliferating endothelium. The neighboring connective tissue and bloodvessels may be invaded. The individual cells assume a variety of shapes, and are not always recognized as endothelial in origin. The flat cells become irregular in outline and swollen, and the nuclei take a deep stain. It may be possible to identify these cells by tracing them to their origin in the walls of vessels, where they are not so changed in structure.

It is puzzling to differentiate between a carcinoma invading the lymph spaces and an endothelioma arising from the lymph spaces. In lymphatic carcinoma the appearance is that of veins of marble in the stroma.

CHAPTER XXVII.

THE DIAGNOSIS OF SARCOMA OF THE UTERUS.

From the older literature we are led to believe that sarcoma of the uterus is an extremely rare condition. Roger Williams and Gurlt reported ten sarcomata in 6764 tumors of the uterus. Doubtless many sarcomata were regarded as carcinoma through failure to make a microscopic examination. Some were regarded as fibroids and were spoken of as recurrent.

Whitridge Williams, in his *Contribution to the Histology and Histogenesis of Sarcoma of the Uterus*, reported 114 uterine sarcomata in the literature. The proportion of sarcoma to carcinoma in the uterus is said to be 1 : 40.

Etiology. Nothing is known of the essential cause of sarcoma. What has been said of Cohnheim's theory receives no confirmation in sarcoma. Inflammatory lesions and trauma seem to bear no causal relation, nor does childbearing. Fully two-thirds of the cases are found in women who either have not borne children or have given birth to less than the average number. We find no age exempt from infancy to the postclimacteric period. A case has been lately reported in which a hysterectomy was performed at three years of age. Pick reports a case at two years of age. The oldest case recorded was seventy years. Gusserow reported seventy-three cases, of which four were under twenty-nine years of age ; fifteen were from thirty to forty years ; twenty-eight from forty to fifty ; eighteen from fifty to sixty, and three were over sixty years of age.

Anatomical Diagnosis. As in carcinoma of the uterus, sarcoma is found in the vaginal portion of the cervix, in the cervical canal, and in the body of the uterus.

I. **Sarcoma of the Vaginal Portion of the Cervix.** This is an uncommon location for sarcoma. To the naked eye there is no way of distinguishing this growth from carcinoma. There are the cauliflower and the infiltrating forms, resembling those found in carcinoma of the vaginal portion.

II. **Sarcoma of the cervix** is distinctive when assuming, as it usually does, a grape-like form (sarcoma botryoides). The mass protrudes from the external os and hangs into the vagina as transparent vesicles, appearing not unlike a vesicular mole. This form is more often found in childhood, but may appear in old age. Pfannenstiel found 50 per cent. in nulliparæ. A similar growth is sometimes seen in the body of the uterus due to œdema or myxomatous degeneration of the growth. Carcinoma of the cervix never assumes this vesicular form.

Sarcoma of the cervix may form a diffuse infiltration of the cervical tissue or protrude from the surface as a tubercular, polypoid, or cauliflower growth.

III. **Sarcoma of the body of the uterus** arises from any of the mesoblastic structures. Very commonly the growth is a malignant transformation of a pre-existing fibroid tumor.

a. Sarcoma of the submucosa may take the form of a diffuse infiltration or of a papillary or nodular growth projecting from the surface. The surface of these growths is never shaggy as in carcinoma.

The color varies from pale gray to dark red. Their consistency is soft and often friable.

The growth rarely begins as a diffuse involvement of the mucosa, but rather as a circumscribed lesion extending by continuity of surface and by metastasis.

b. Sarcoma of the wall of the uterus generally arises from submucous or interstitial fibroids. The fibrous structure of the tumor gives place to a homogeneous substance of soft consistency, varying in color from pale gray to dark red. The growth is rapid as compared to that of a fibroid. Recurrent fibroids were recognized in the days when the microscope was little used. They are now regarded as fibrosarcomata.

Sarcoma spreads through the uterine wall to the peritoneum and to the abdominal and pelvic viscera. Metastasis to neighboring organs and to lymphatic glands is unusual. The point of earliest attack is the lung. The ovary is the seat of secondary invasion more often in sarcoma than in carcinoma.

Microscopic Diagnosis. As elsewhere in the body, sarcoma is classified as round-cell, spindle-cell, or giant-cell. Very often there is a mixture of these cells.

1. **Round-cell sarcoma** is composed of large or small round cells having a large nucleus and a limited rim of protoplasm. The

diameters of the cells vary from 4 to 15 micromillimetres. There is a variable amount of chromatin and an abundance of karyokinetic figures. Numerous newly-formed bloodvessels are seen. The sarcoma cells directly bound blood spaces.

2. **Spindle-cell sarcoma** is composed of large or small elongated cells arranged in bundles and bands. On section they appear in various forms from round to spindle. Two or more nuclei are observed. The amount of chromatin varies greatly.

3. **Giant-cell sarcoma** is a rare finding in the uterus. These cells may be 80 micromillimetres in diameter. They are polynuclear, and are rich in chromatin and mytotic figures. The nuclei vary in shape and in staining qualities ; vacuoles may be present.

In all the above forms the fibrillar network may be so scanty that it escapes notice, or so abundant that the name fibrosarcoma is suggested. As a rule, the connective tissue framework is distributed uniformly between the cells, but nests of cells may be surrounded, by connective tissue giving the appearance of cancer nests (alveolar sarcoma). Newly-formed bloodvessels are prominent features of sarcoma, and may be sufficiently abundant to give to the tumor the name angiosarcoma.

The intimate association of the blood channels with the surrounding sarcoma cells is characteristic. No sharp distinction can be made between the three microscopic forms. A mixture of two or three is the rule.

Secondary changes in sarcoma tissue are of common occurrence, though not so frequent as in carcinoma, for the reason that sarcoma cells are more directly supplied with blood. Degenerative changes ordinarily begin in the centre of a sarcoma. The cells at the periphery do not usually suffer change. The degenerative forms commonly seen are the hemorrhagic, hyaline, and fatty.

Mixed Tumors. The tendency of sarcoma cells to assume the mature type accounts for the frequency of the so-called myosarcoma of the uterus. Myxosarcoma is a myxomatous degeneration of the connective tissue stroma. Enchondrosarcoma, carcinosarcoma, and melanosarcoma are of extremely rare occurrence.

Clinical Diagnosis. All that has been said of the clinical diagnosis of carcinoma of the uterus applies to sarcoma. The clinical manifestations and physical findings do not materially differ from carcinoma. The differential diagnosis of carcinoma from sarcoma must depend upon the microscope.

The early recognition of sarcomatous degeneration of a fibromyoma is of the utmost importance. When a fibromyoma of the uterus undergoes malignant changes it takes on rapid growth, becomes softer in consistency, more pain is experienced in the region of the tumor, cachexia rapidly develops, ascites may make its appearance, and metastatic growths may arise in the lungs and elsewhere. If the tumor is interstitial or submucous, the hemorrhages will be greater. When a fibroid takes on a rapid growth, and particularly if near the time of the menopause, no time should be lost in removing the growth. When after removal of a fibroid the growth returns, it is suggestive of sarcoma.

The length of time a sarcoma may exist before destroying life is variable, and has been observed from two months to five years. The average time is estimated at two years.

CHAPTER XXVIII.

THE DIAGNOSIS OF DISEASES OF THE TUBES.

Methods of Examination. Only under favorable conditions can a normal tube be outlined in a bimanual examination. If the abdominal walls are thick and tense an anæsthetic will be required.

The uterus is first located in an abdomino-vaginal examination. From the horn of the uterus the hand, passing outward toward the sides of the pelvis, should follow the tube a variable distance. The normal tube is made to roll under the examining finger like a cord. It appears to be about the size of a slate-pencil. At the fimbriated extremity the wall is so thin that it is impossible, under normal conditions, to palpate it. When the uterus is in retroposition, or when the tubes have fallen behind the uterus, or when the uterus and tubes are in their normal position and the vagina is small and sensitive, the recto-abdominal method of examination is preferable. In the unmarried a recto-abdominal examination should be done under anæsthesia.

Where the tubes lie beyond easy reach of the examining finger, traction upon the cervix with vulsella forceps should be made by an assistant, while the recto-abdominal or vagino-abdominal method is carried out.

May a sound be passed into the tube? Undoubtedly the sound has been passed into diseased tubes, but it is questionable whether the normal tube has ever been sounded. It is very certain that the procedure should never be attempted for fear of penetrating the uterus.

ANOMALIES IN THE STRUCTURE OF THE TUBES.

1. Both tubes may be wanting, in which case the uterus is commonly absent.

2. A single tube may be wanting, in which case the corresponding side of the uterus is usually absent.

3. One or both tubes may be rudimentary and associated with a rudimentary uterus. The tubes may remain infantile in type, very greatly convoluted, and have a small lumen.

4. The lumen of the tube may be partially or completely obliterated or may be abnormally large.

5. Rudimentary tubes or fimbriæ may spring from the main tube. Leading into the main tube through the accessory tubes and fimbriæ are rudimentary canals and ostia.

FIG. 156.

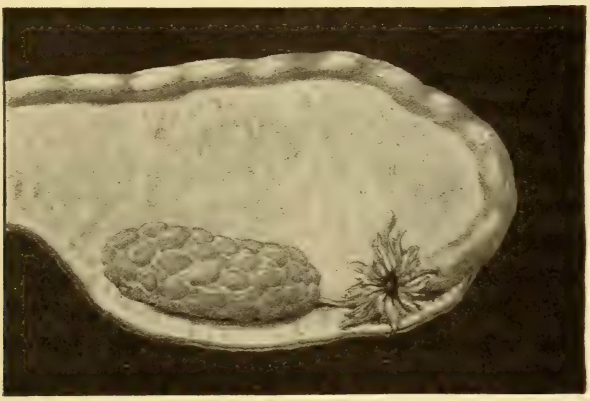

Ovary and Fallopian tube, from a woman forty-one years of age. Natural size. Atrophic processes and consequent decrease in size of the ovary and tube already begun. (DUDLEY.)

Webster resected the fimbriated end of the tube, and some months later the abdominal cavity was again opened and the fimbriæ were found to be regenerated.

6. Diverticula of the endosalpinx are sometimes present, and are known to be a cause of tubal pregnancy.

CHANGES IN THE POSITION OF THE TUBES.

These changes may be congenital, but are more often acquired. In congenital malposition of the tubes there is usually a malposition or maldevelopment of the uterus. In a uterus bicornis the tubes lie more to the sides of the pelvis than is normal. In a rudimentary uterus the tubes lie below the normal level. Congenital hernia of one or both tubes is a rare finding.

Much more frequent are acquired displacements of the tubes. When the tube becomes enlarged and increased in weight, it tends

to fall to a lower level at the side of or behind the uterus. Adhesions may pull the tube in any direction, and all swellings, whether inflammatory or new-growths, push the tubes into malpositions. Any displacement of the uterus will almost invariably displace the tubes.

CIRCULATORY DISTURBANCES IN THE TUBE.

Whatever interferes with the general or local circulation in the pelvis may cause congestion of the Fallopian tubes. Thus diseases of the heart, lungs, liver and kidney, abdominal tumors, ascites, chronic constipation, and tight lacing are among the causes of tubal congestion.

Infectious diseases, the blood dyscrasias, burns, toxæmias, and menstrual congestion are additional general causes. A displaced tube, one that is twisted, constricted, or compressed, may cause congestion and possibly hemorrhages into the tube.

Anatomical Diagnosis. The congested tube is slightly swollen, dark red in color, and offers unusual resistance to pressure. Hemorrhages may be seen in the mucosa and in the lumen. Necrosis of the tube may result from interference with the blood supply. Martin describes a case of necrosis of the tube following a mitral insufficiency.

When the ends of the tubes are closed and blood is extravasated into the lumen in sufficient quantity the tube will be distended into what is known as a hæmatosalpinx. For further description of hæmatosalpinx, see page 327.

The microscope shows the vessels to be deeply congested with blood extravasated into the tube wall and lumen. When there is necrosis the tissues stain poorly.

Clinical Diagnosis. Perhaps a large proportion of cases goes unrecognized, partly because of the frequency with which the lesion exists in the absence of all clinical manifestations; partly because of associated lesions. The menstrual periods are painful, and the functions of the bowel and bladder are performed with more or less discomfort. Tenderness on pressure over the affected tube is the one constant symptom. The diagnosis cannot be made with certainty without an exploratory incision. The existence of a possible cause, together with the finding of a tube that is somewhat tender to pressure and slightly enlarged, will lead to a probable diagnosis. It is manifestly impossible to differentiate clinically

PLATE XXXVII

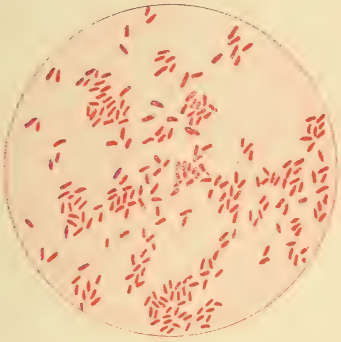

Bacillus coli communis.

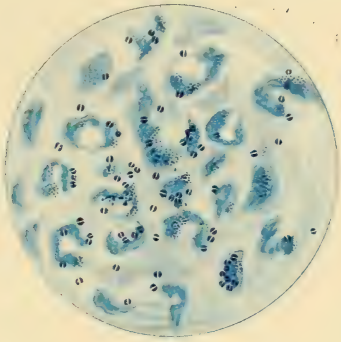

Gonococcus.

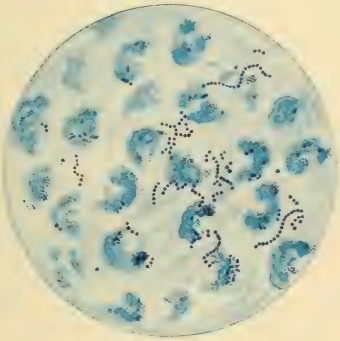

Streptococcus pyogenes.

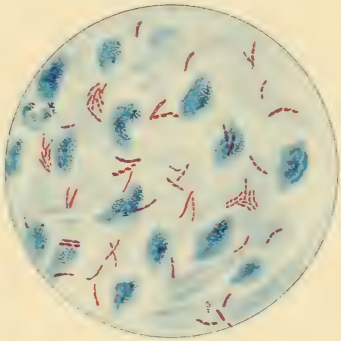

Bacillus tuberculosis.

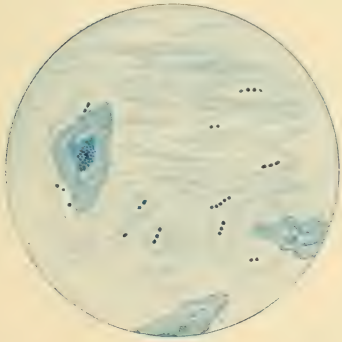

Pneumococcus.

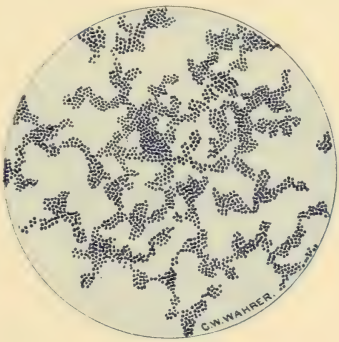

Staphylococcus.

Magnified 1000 times.

a congested tube from a catarrhal salpingitis ; the former is the forerunner and accompaniment of the latter.

The diagnosis of hæmatosalpinx will be referred to on page 327.

INFLAMMATIONS AND INFECTIOUS GRANULOMATA.

General Considerations. Of all lesions of the tube the inflammatory are most commonly observed. Of the various exciting causes of salpingitis we have the authority of Noeggerath and Wertheim for placing the gonococcus at the head of the list of micro-organisms. In 302 cases of inflammatory lesions in the tubes, there were 83 in which living micro-organisms were found, and of this number 56 were gonococci, 11 were streptococci, 6 staphylococci, 1 was the pneumococcus, while 122 were sterile. The fact that such a large percentage is sterile adds to the difficulty in determining the essential microbic cause. L. R. Guthrie collected statistics from operators in fifteen cities of Iowa, and concludes that 70 per cent. of inflammatory diseases of the tubes are of gonorrhœal origin. Neisser, in 143 cases, found the gonococcus in 80 after a latent period of from two months to eight years. He emphasizes the necessity of repeated examinations and faultless technic. Mixed infections are of common occurrence. The path of invasion is usually by way of the uterus ; seldom by the abdominal route from the ovary, bowel, and peritoneum. More rarely is the invasion by way of the lymph and blood streams.

The manipulation of an infected uterus during the process of an examination or operation is doubtless often responsible for extension of the infection from the uterus to the tubes.

There are no pathognomonic symptoms of salpingitis, and none that are invariably present. Associated inflammatory lesions in the genital tract are nearly always found, and hence it is that the symptoms of the one are so intimately associated with those of the other, and, therefore, it is difficult to obtain a clinical picture of salpingitis.

Again, the innervation of the tubes, ovaries, and uterus is so intimately connected as to bring these organs into close sympathy one with the other.

Pain is the most constant symptom, and yet advanced cases of salpingitis exist in the absence of pain. Temperature has but little diagnostic value. Sterility does not necessarily follow as the result

of double salpingitis. An occluded lumen may eventually become patent and permit the passage of the ovum.

The history of infection and the clinical course of the disease cannot in themselves suffice for a diagnosis, but must be supported by direct palpation of the diseased tubes.

CLASSIFICATION OF SALPINGITIS.

I. Catarrhal Salpingitis.
- 1. Acute catarrhal salpingitis (endosalpingitis).
- 2. Chronic catarrhal salpingitis.
  - *a.* Salpingitis isthmica nodosa.

  End stages :
  - *a.* Hydrosalpinx.
  - *b.* Hæmatosalpinx.

II. Purulent Salpingitis.
- 1. Acute suppurative salpingitis.
  - *a.* Septic.
    - 1. Puerperal.
    - 2. Non-puerperal.
  - *b.* Gonorrhœal.
- 2. Chronic suppurative salpingitis.

  End stage—Pyosalpinx.

III. Tuberculous Salpingitis.

I. CATARRHAL SALPINGITIS.

Etiology. The statistics of Martin illustrate the frequency of the lesion. In 1402 operations on the tubes 415 (29.5 per cent.) were for catarrhal salpingitis.

As a rule, the lesion is secondary to inflammatory diseases of the uterus, which extend by direct continuity of tissue. Primary catarrhal salpingitis, in the absence of an inflammatory lesion elsewhere in the pelvis, is an unusual occurrence.

We may speak of the causes as thermic, mechanical, chemical, and microbic.

1. **Thermic influences** resulting in salpingitis can scarcely act directly because of the deep-seated location of the tube. Menstrual congestion from chilling of the body may be placed in this category.

2. **Mechanical causes** have a greater significance. Such, for example, are digital and instrumental manipulations, sexual excesses, massage, and overstrain in lifting and walking.

3. **Chemical irritants** in the form of antiseptics injected into the uterus may pass into the tubes and set up a salpingitis.

4. By far the most essential and prevailing factors in the causation of catarrhal salpingitis are the **pathogenic micro-organisms.**

It is not always possible to distinguish between the above-named causes in a given case of catarrhal salpingitis. Two or more factors may operate to bring about the same result. Of the general diseases complicated by catarrhal salpingitis mention may be made of all the specific, infectious, and contagious diseases, notably tuberculosis, malaria, and chlorosis.

Anatomical Diagnosis. In **acute catarrhal salpingitis** the tube is of a livid or dark red color, is slightly thickened and convoluted, its consistency is increased to a limited degree, and the fimbriæ are red, swollen, and retracted to a variable degree preparatory to a possible closure of the abdominal end of the tube. On cross-section of the tube the mucosa rolls out and is congested and thickened. In the lumen of the tube is a variable amount of serous fluid. No adhesions surround the tube.

The microscopic diagnosis is based upon the marked congestion and infiltration with small round cells in the mucosa, and to a less degree in the musculature. Here and there are hemorrhagic extravasations into the connective tissue spaces. The epithelial lining of the tubular lumen may be normal, but in long-standing lesions the cells may degenerate and become desquamated. The secretion found in the lumen of the tube is in great part lymph mixed with blood cells and degenerated epithelium. From the acute stage the tube may easily resolve into a normal condition, suppuration may follow, or, as is not infrequently the case, the acute stage may pass into the chronic.

In **chronic catarrhal salpingitis** the tube enlarges in all diameters and is correspondingly convoluted. The tube is of firmer consistency than in the acute stage. The mucosa and muscularis are thickened through congestion of the bloodvessels and hyperplasia of the connective tissue. The epithelium lining the tube lumen may be destroyed. Following this the lumen may be obliterated by adherence of the denuded mucous folds. Adjacent folds of mucous membrane may adhere by their free margins and lock in

spaces filled with a serous secretion and lined with columnar epithelium, thereby closely simulating retention cysts formed from glands. The mucous folds become club-shaped from congestion and the inflammatory exudate. The peritoneal covering of the tube is involved, and adhesions may surround the tube and close up the fimbriated end, leading to the formation of a hydrosalpinx.

Salpingitis isthmica nodosa is regarded by Chiari and Schauta as a circumscribed interstitial salpingitis located in the isthmus of the

FIG. 157.

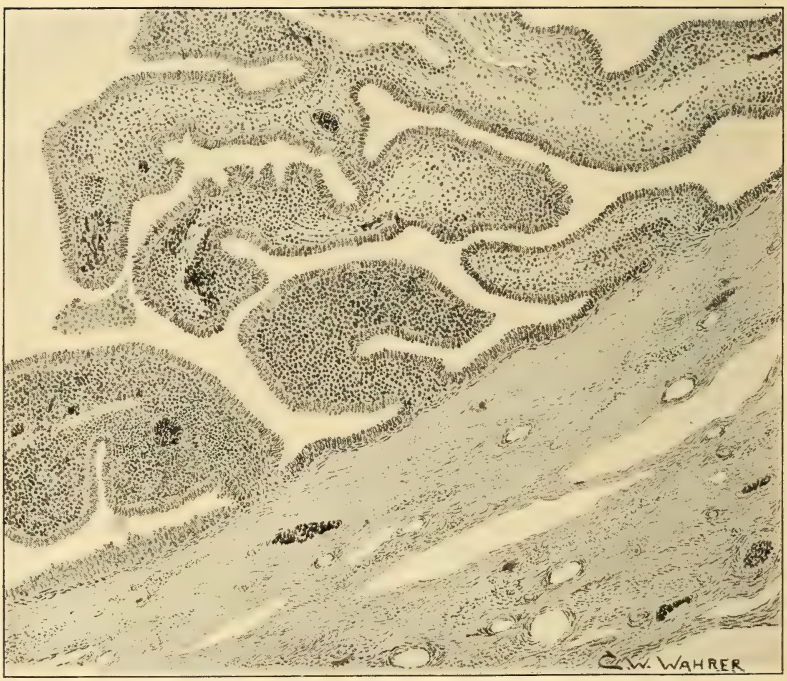

Catarrhal salpingitis. The villous projections of the mucosa are club-shaped, congested, and infiltrated with small round cells. The muscularis is congested.

tube and forming a nodular enlargement varying in size from that of a split pea to a bean. Gebhard regards these growths as benign adenomata.

Hydrosalpinx (sactosalpinx serosa) is the end stage of catarrhal salpingitis. The ends of the tube become closed and the pent-up secretion distends the tube into a serous sac. Because the thin, distended, fimbriated end of the tube offers little resistance to the

PLATE XXXVIII.

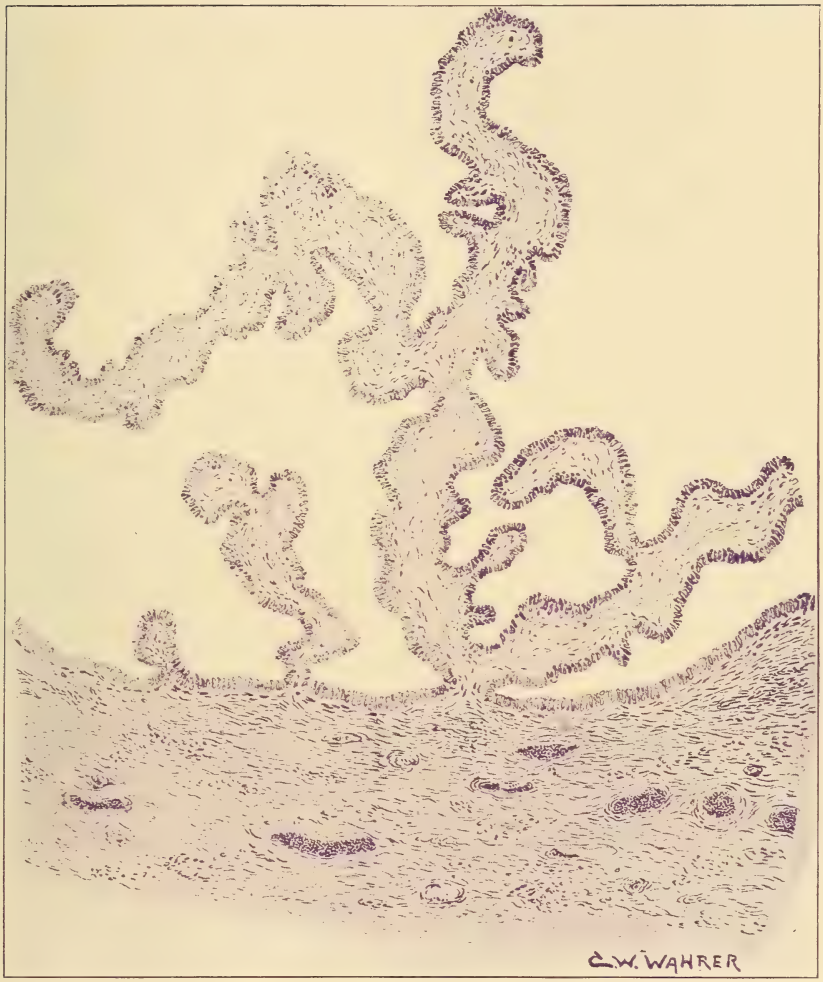

Hydrosalpinx.

A branching fold of mucous membrane projects into the lumen of the tube. It is composed of connective tissue covered by a single layer of columnar epithelium. A section of the tube wall is composed of connective tissue, muscle fibre, and bloodvessels; and is lined within by a single layer of columnar epithelium.

accumulating fluid, the tube distends at the outer end to a far greater extent than at the uterine end, where the muscular wall is more resistant and the lumen of the tube smaller. It is unusual for the tube to distend throughout its entire length; it may enlarge to the size of a child's head. The larger the tube the thinner and more transparent is the wall.

Adhesions to the tube are not ordinarily present, and are seldom firm, hence hydrosalpinx is more or less movable. The fimbriated end is shaped like a club or retort. Radiating lines mark the adhesions of the fimbriæ.

In the early stage we have the gross and microscopic appearance of catarrhal salpingitis. As the tube distends the walls become thinner and more transparent; the mucosa thins and the musculature is stretched and atrophied, presenting longitudinal bands of muscle fibres running the entire length of the tube and terminating at the fimbriated end in a rosette figure.

The epithelium of the mucosa is compressed and may be wholly lost. The contents of the tube is clear, serous fluid, with a specific gravity of 1005 to 1010, and an alkaline or neutral reaction. Sometimes the fluid is of a greenish tint, due to the presence of cholesterin. Desquamated epithelium, leucocytes, and occasionally a few red blood cells are found in the fluid contents of the tube.

When the uterine end of the tube is not permanently and completely closed the contents may be periodically discharged into the uterus (*hydrops tubæ profluens*). As expressed by Sutton, the blockade at the uterine end has been raised.

The contents of the tube may be absorbed, but it is unusual for the fimbriated end to reopen.

A pyosalpinx may develop from a hydrosalpinx by secondary infection with pyogenic organisms conveyed through the uterus or bowels. Tortion of a hydrosalpinx is a possible event leading to the formation of a hæmatosalpinx.

Sutton gives the following reasons for believing that a pyosalpinx often resolves into a hydrosalpinx:

1. Hydrosalpinx is not found in acute cases.

2. In many chronic cases hydrosalpinx is found on one side of the uterus and pyosalpinx on the other.

3. The ampulla of a tube will sometimes be dilated into a hydrosalpinx, while the isthmus contains pus.

4. The fluid contents in a hydrosalpinx will sometimes be color-

less, but the recesses of the tube contain caseous material and cholesterin.

5. The dilated tube in the hydrosalpinx may, as in pyosalpinx, communicate with a large ovarian follicle to form a tubo-ovarian cyst.

Tubo-ovarian Cyst. Here the ovary is distended into a cyst which communicates with a hydrosalpinx through an adventitious opening. A congenital tubo-ovarian cyst has not as yet been described. As a rule, the hydrosalpinx and ovarian cyst develop independently.

FIG. 158.

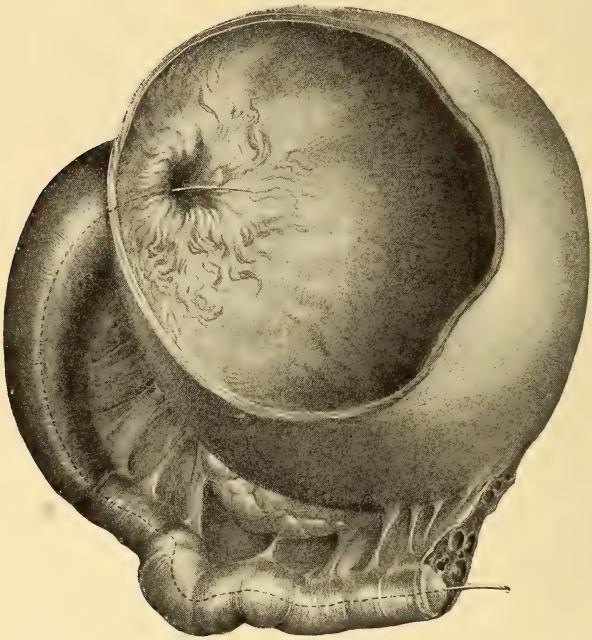

Tubo-ovarian abscess. Abscess cavity in the ovary. (DUDLEY.)

Later the two structures unite by adhesions, the partition wall atrophies, gives way, and there is established a communication between the two. Rokitansky described a corpus luteum cyst communicating with a hydrosalpinx.

The fimbriæ of the tube may be found free in the ovarian cyst or adherent to the inner surface of the cyst wall.

Hæmatosalpinx. From the macroscopic appearance it is not always possible to distinguish an inflammatory hæmatosalpinx from one due to ectopic pregnancy or to other non-inflammatory causes.

The wall of the tube is possibly thicker from round-cell infiltration and hyperplasia, and inflammatory adhesions may form about the tube. In addition there are usually evidences of infection in the uterus. A careful study of specimens of hæmatosalpinx will, in a large percentage, lead to the discovery of an embryo, an apoplectic ovum, or chorionic villi. It is the uniform testimony of observers that nearly all cases of hæmatosalpinx are due to ectopic gestation.

The term *hæmatosalpinx* should be reserved exclusively for Fallopian tubes dilated with blood and in which there is no evidence of pregnancy. A dilated tube containing chocolate colored fluid is not to be classed as hæmatosalpinx.

The gross and microscopic appearances of hæmatosalpinx do not differ greatly from those of hydrosalpinx, with the exception of the contents and the dark red color which is imparted to the contents. Fluctuation may not be so distinct in hæmatosalpinx.

Clinical Diagnosis of Catarrhal Salpingitis. 1. **Acute Catarrhal Salpingitis.** The clinical picture is usually that of uterine catarrh or of acute pelvic inflammation. Rarely are the tubes alone involved, and hence it is difficult to clearly define the clinical signs of catarrhal salpingitis. There is a feeling of weight and discomfort in the pelvis, often amounting to acute pain, which is located in one or both sides. Painful urination and defecation are sometimes complained of.

The initial chill, followed by a rise of temperature, which is accompanied by flashes of heat and cold, may be due to the salpingitis, but is more often the result of more extensive lesions in other parts of the pelvis.

It is possible for catarrhal salpingitis to exist without the knowledge of the patient.

The diagnosis must, therefore, rest largely upon the local findings, for in the absence of a physical examination no positive diagnosis can be made. Because of pain and tenderness the tubes cannot be palpated without an anæsthetic. The tube, as outlined in a bimanual examination, is about the size of the little finger; it is movable, slightly more resistant to pressure than is the normal tube, and at the fimbriated end the sensation imparted is that of a soft, ill-defined mass.

2. **Chronic catarrhal salpingitis** may arise in a very insidious manner, or may begin as an acute infection, with all the symptoms and signs above referred to. In the chronic stage there is no tem-

perature and no increase in the pulse rate. The patient is often nervous, and suffers from pain, particularly during the menstrual periods. Sexual intercourse is painful, and a leucorrhœal discharge is a common accompaniment.

In the form described by Chiari and Schauta, known as salpingitis isthmica nodosa, the pain during menstruation is colicky and cramping. The tenderness on palpation is not so great as in the acute stage. The tube is outlined as irregular, convoluted, and of the size of the thumb or index finger. In consistency the tube is much firmer than normal, and in manipulating the tube the range of motion is observed to be restricted, in part from loss of flexibility, and in part from the presence of adhesions about the tube. The

FIG. 159.

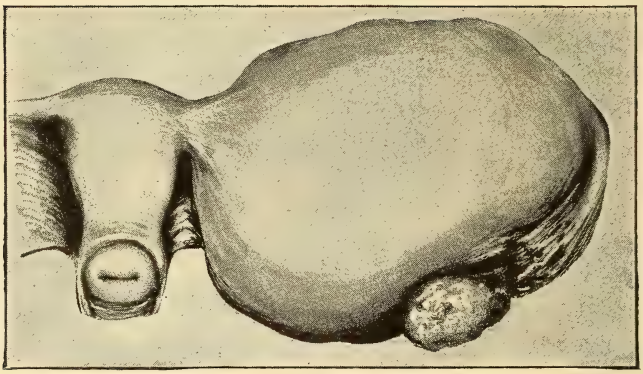

Large hæmatosalpinx; semidiagrammatic. (THOMAS and MUNDÉ.)

position of the tubes is seldom exactly normal. More often they are found at the side of or behind the uterus. The uterus may be drawn to the affected side and restricted in its range of motion.

In salpingitis isthmica nodosa the nodular swellings near the horn of the uterus are sometimes recognized in a bimanual examination. Few cases have been diagnosed clinically.

Hydrosalpinx and hæmatosalpinx are recognized clinically by the pressure they make upon the surrounding structures and by direct palpation. The patient may be wholly unaware of the existence of the lesion.

In a conjoined examination, preferably under anæsthesia, the distended tube is outlined as a retort-shaped mass, tense, elastic, and often fluctuating. If no adhesions surround the tube there

PLATE XXXIX.[1]

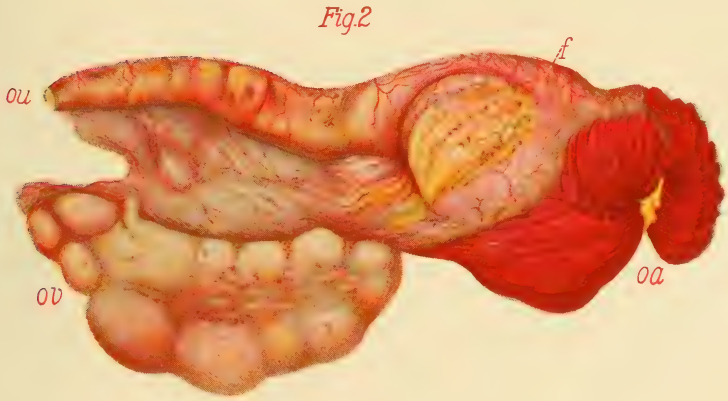

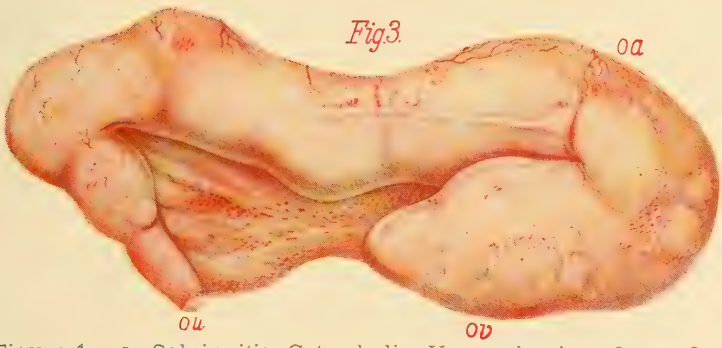

Figure 1. *a*, Salpingitis Catarrhalis Hemorrhagica, Cross Section. *m*, Muscle of the tube. *n*, Mucosa of the tube. *l*, Lumen of the tube. Picro-carmine stain. (Hartnack, Oc. 2; Objective 4.) *b*, Leucocytes containing blood pigment with normal red blood corpuscles from the tubal mucosa. (Hartnack, Oc. 2; Objective 7.)

Figure 2. Salpingitis Purulenta Acuta Dextra. *ou*, Uterine opening of tube. *oa*, Abdominal end of tube. *ov*, Right ovary. *f*, Purulo-fibrinous deposit. Posterior view, natural size.

Figure 3. Salpingitis Purulenta Chronica Dextra. *ou*, Uterine end of tube. *oa*, Region of Abdominal end of tube. *ov*, Ovary with strongly adherent tube. Posterior view, natural size.

[1] August Martin, Krankheiten der Eileiter.

should be a free range of motion. The small and firm uterine end, together with the outer, rounded, elastic, and fluctuating portion, gives the impression of an ovarian cyst. The ovary can rarely be

Fig. 160.

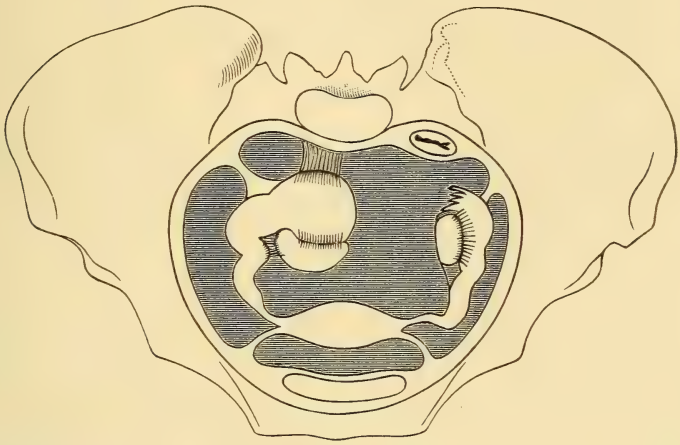

Right tubo-ovarian abscess and left pyosalpinx. The right tube and ovary are distended with pus as is also the left tube. Adhesions bind the tubes together and the right tube to the posterior surface of the uterus, rectum, and wall of the pelvis.

recognized apart from the distended tube. There is no way of detecting a hydrosalpinx from a hæmatosalpinx except by aspirating or by an exploratory incision.

Tubo-ovarian cysts are only recognized after the cyst is removed.

II. PURULENT SALPINGITIS.

Etiology. The causes are essentially those of catarrhal salpingitis. As previously stated, catarrhal salpingitis may be followed by suppuration. On one side may be a catarrhal salpingitis ; on the other side a purulent salpingitis ; the two apparently distinct and separate lesions may be dependent upon the same cause.

Following are the statistics from the clinic of A. Martin : In 2098 cases of purulent salpingitis, 279 were caused by gonorrhœa, 374 by puerperal septic infection, 19 by tuberculosis, and 13 by syphilis. Of this number 1282 were preceded by catarrhal salpingitis. From the statistics of Martin, Schauta, Frommel, Charrier, Wertheim, and Prochowick 376 cases are collected, and of this number, 76 showed a pure culture of the gonococcus, 10 a mixed

gonococcus infection, 15 a staphylococcus and streptococcus, 7 a pneumococcus, and 3 a bacterium coli infection. In 15 there was doubtful identity, and in 215 the tubes were sterile.

In puerperal septic infection the essential causes are, in the order of frequency, staphylococcus pyogenes aureus and albus, and streptococcus pyogenes. The gonococcus, the tubercle, and colon bacilli are occasional factors.

The infection commonly travels by direct continuity of tissue, passing directly from the endometrium to the tube. Occasionally the infection is conveyed through the broad ligaments to the tube, or from the peritoneum to the tube.

Infection of the tubes acquired by instrumental and digital manipulations is due to the same sort of bacteria as are found in puerperal infection.

Gonorrhœal infection of the tube is for the most part acquired by sexual intercourse, but may be conveyed by instruments and the fingers both in the puerperal and non-puerperal state. The infection usually travels by continuity of tissue, but may be conveyed by the lymph and blood streams.

Anatomical Diagnosis. *a.* In **acute purulent salpingitis** there are all the evidences of an intense acute inflammation. The tube is enlarged possibly to the size of the thumb ; the color is an intense red ; the distended bloodvessels stand out prominently under the serous covering, and the fimbriæ are swollen and retracted. Very early in the process the fimbriæ may be agglutinated, thereby completely closing the abdominal end of the tube. These adhesions are not firm, and for this reason the bimanual examination must be made cautiously for fear of expressing the pus from the tube into the abdominal cavity. From the naked-eye appearance of the unopened tube it is impossible to say whether or not there is pus within the lumen.

In the acute stage a fresh fibrinous exudate forms about the tube, and as the lesion passes into the chronic stage these adhesions extend and become more firmly organized. The elongation of the tube leads to kinking and convolutions in the course ; the tube may be completely doubled upon itself. In the lumen of the tube pus is accumulated in varying amounts.

Under the microscope the tubal wall is seen to be congested, and there is round-cell and leucocytic invasion of its entire wall. Pyogenic micro-organisms can be demonstrated throughout the

wall. The epithelium of the mucosa is early destroyed, and the folds of denuded mucous membrane adhere, thereby partially or completely obliterating the lumen of the tube and locking in spaces filled with pus. Throughout the muscularis and underneath the serous covering are localized areas of suppuration. In the pus accumulated in the lumen and wall of the tube it is often possible

FIG. 161.

Acute purulent salpingitis. The folds of mucous membrane are swollen and club-shaped; they are infiltrated with small round cells, pus cells, and pyogenic micro-organisms. A similar infiltration is found in the muscularis. In the lumen of the tube is found blood and pus cells in all stages of degeneration. The epithelium is intact.

to demonstrate the presence of the micro-organisms causing the infection. The older the infection the less likely is the finding of bacteria. There may be superficial necrosis of the mucosa forming a pseudodiphtheritic membrane. Gonorrhœal infection is more likely to be confined to the mucous membrane than are the other forms. Wertheim demonstrated the presence of the gonococcus in all portions of the tube.

b. **In chronic purulent salpingitis** the tube attains to about the size of the thumb. The color is not such an intense red as in the acute stage, and the adhesions are firmer and more extensive. The fimbriæ are almost invariably adherent, obliterating the abdominal end of the tube. The convolutions of the tube are bound one to another, and are adherent to the ovary, uterus, bowel, bladder, omentum, and abdominal wall. These adhesions permit very limited excursions of the tube. As the tube enlarges and the adhesions contract the tube and ovary adhere to the side of or behind the uterus. The appendix vermiformis and tube are so frequently adherent that it is always advisable to inspect the appendix when the abdomen is opened. From the tube the pus may evacuate through adhesions

FIG. 162.

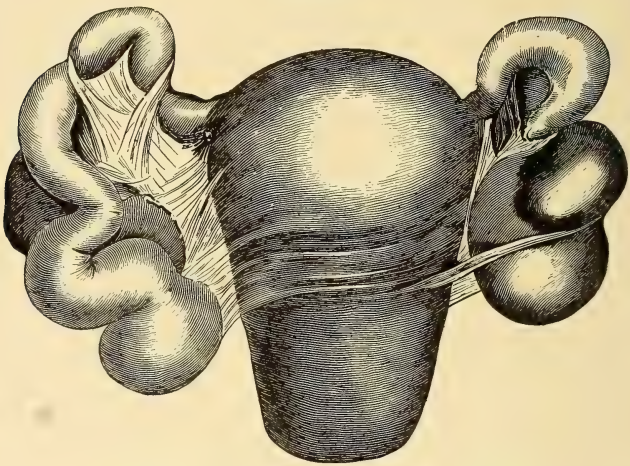

Double pyosalpinx with uterine adhesions. (BANDL.)

into an adherent hollow viscus. Again, the infection may travel from the bowel through the adhesions to the tube and cause a secondary infection in the tube.

The pus within the tube is yellow or grayish-yellow, rarely greenish or blood-stained. Nothing can be ascertained from the naked-eye appearance of the pus as to its virulence. In long-standing cases the formed elements of the pus may absorb, leaving a serous fluid.

The entire wall of the tube is thickened through congestion and hyperplasia of the connective tissue. Small abscesses may be seen in the mucosa, the muscularis, and underneath the serosa.

Pyosalpinx (sactosalpinx purulenta). Where the ends of the tubes are closed the pus accumulates within the lumen and distends the

tube. The greater distention is at the fimbriated end, where the wall is thin. It is seldom that the tube is distended throughout its entire length. The size is seldom greater than a man's fist, but it may be large enough to extend above the brim of the pelvis and even to the umbilicus. The wall of the tube is at first thickened, but when greatly enlarged there is an irregular thinning, even to the point of rupture. Rupture of the tube may take place at its lower circumference between the layers of the broad ligament or at any point in the wall of the tube. Adhesions usually protect the peritoneal cavity, and frequently direct the pus into a hollow viscus or into a cyst of the ovary. Left pyosalpinx is very prone to rupture into the rectum.

Fig. 163.

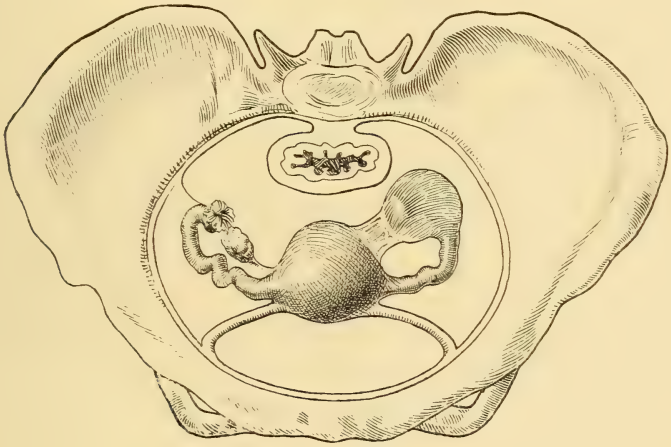

The left tube is distended with pus and is adherent to the posterior surface of the uterus. The right tube and ovary are normal.

The pus contained within the distended tube is found in various stages of preservation, and is mixed with red blood cells, degenerated epithelium, fibrin, and detritus. The mucosa atrophies from pressure, and may be replaced by connective tissue. The epithelium is almost wholly destroyed. The muscle and connective tissue fibres are atrophied and the bloodvessels are limited in number.

The Clinical Diagnosis of Purulent Salpingitis. 1. **Acute purulent salpingitis** is generally ushered in by marked constitutional disturbances. There may be an initial chill; this is followed by a rise of temperature and pain referred to the affected tube. In

nearly every instance there is a similar lesion in the uterus, which may mask the more limited affection of the tube. Very often the infection does not stop in the tubes, but is carried on to the ovaries and peritoneum, giving rise to additional temperature and pain that will wholly mask the clinical manifestations of the affected tube. As a rule, the tubes are not involved for from three to five days following septic infection of the uterus. After complete resolution in the uterus and peritoneum the infected tube may fail to resolve, and remain distended with pus. This indisposition on the part of the tubes to resolve as readily as do other parts of the genital tract is explained in part by the lessened power of absorption in the tube, but in greater part by the closure of the ends of the tube, thereby locking in the pus.

Repeated exacerbations are the rule. These are brought about by sexual excesses, menstrual congestion, and injudicious exercise.

We seldom find gonorrhœal infection invading the tubes before the second or third week after the initial infection of the cervix. As a rule, the general symptoms are not so well-marked in gonorrhœal infection as in other forms of septic infection.

2. **Chronic purulent salpingitis** usually begins with an acute attack and ends in a pyosalpinx. The general disturbances are in nowise proportionate to the extent of the lesion. All symptoms may be absent in the presence of an extensive lesion. Menstrual disorders in the form of a menorrhagia and dysmenorrhœa are fairly constant symptoms. Pain in the region of the tubes and referred to the back and thighs, together with digestive disorders, are common complaints. Sterility is almost sure to result from a bilateral involvement of the tubes. Martin reports three cases of bilateral pyogenic infection of the tubes in which pregnancy followed.

Palpation of the diseased tubes can usually be accomplished without difficulty. When found impossible to clearly outline the tubes an anæsthetic should be given. The uterus is first located. It is seldom found in the median line, and its range of mobility is restricted. The tubes are engaged between the examining fingers, and are traced outward from the horns of the uterus or downward and backward beside and behind the uterus. They are felt as sensitive thickened cords varying in consistency, size, position, and degree of mobility. The consistency is always firm at the uterine, less so at the fimbriated end. The kinks in the tube are felt as nodules in its course. Sensitiveness to pressure is directly proportionate to

the acuity of the inflammation. The ovary can be palpated apart from the tube only in exceptional cases. The position of the tube largely depends upon the position of the uterus. In retroposition the tubes and ovaries may lie in the pouch of Douglas. With the uterus erect and forward, it is scarcely possible for the tubes to reach into the pouch of Douglas. There will be no fluctuation unless the tubes contain a considerable amount of pus.

The walls of a pyosalpinx are thicker and more resisting to the pressure of the contained fluid; hence the tube is rarely so large as a hydrosalpinx may become. Furthermore, fluctuation is less marked, and there is greater fixity and sensitiveness to pressure.

The *character of the pyosalpinx* should be determined when possible—that is, whether due to gonorrhœa, puerperal infection, tuberculosis, or non-puerperal septic causes.

The clinical history will often lead to a positive diagnosis, particularly in gonorrhœal and puerperal cases. Gonorrhœa is assumed to be the cause when other possible factors are eliminated.

The presence of a purulent discharge from the urethra and infection of the glands of Bartholin will determine the diagnosis of gonorrhœal salpingitis to a moral certainty. Absolute certainty in the diagnosis is only obtained by the finding of the gonococcus of Neisser in the secretion.

THE DIAGNOSIS OF SACTOSALPINX.

The term sactosalpinx is understood to be a Fallopian tube distended with fluid—*i. e.*, blood, serum, or pus. Under the generic term sactosalpinx we place hæmatosalpinx, hydrosalpinx, and pyosalpinx—the end stages of catarrhal and purulent salpingitis. The following features are characteristic of sactosalpinx:

The **position** is at the side of or behind the uterus, extending from the horn of the uterus outward or downward. Unless greatly distended the tube lies below the normal level, most often close to the side of the uterus or immediately behind.

The **consistency** is so variable as to render it of little value in diagnosis. When fluctuation is present it is of some diagnostic significance, but it is so often absent that it cannot be relied upon.

The **general contour** is significant. We commonly speak of sactosalpinx as being of retort- or sausage-shape. The tube is distorted in proportion to the degree of distention. The irregularity in the course of the tube can usually be noted in a bimanual examination.

The tube may be so snugly twisted upon itself as to give to the examining finger the impression of a round or oval swelling. So firmly may the tube adhere to the uterus the two are felt as a single mass. The outline of the tube may be lost in a surrounding inflammatory exudate.

The Diagnosis of the Contents of a Sactosalpinx. Following the recognition of a sactosalpinx it is next important to determine the contents of the distended tube. This can only be done with certainty by an exploratory puncture through the vagina or by an exploratory incision. The danger of carrying infection into the tube by the exploring-needle is not to be disregarded. Fortunately the indications for such a procedure are limited, because whether blood, pus, or serum, an operative procedure is indicated.

Differential Diagnosis. Kelly gives the following differential diagnosis between gonorrhœal and streptococcic infection of the tubes :

Gonorrhœal Infection.	Streptococcus Infection.
1. Slow in its onset, often preceded by inflammation of the external genitals and urethra.	1. Onset abrupt, following miscarriage, normal labor, or topical applications.
2. Pain localized in one or both ovarian regions.	2. Pain more general and severe in the lower abdomen.
3. No signs of general peritonitis.	3. Usually signs of peritonitis.
4. Suffers more or less constantly, but may have no fever.	4. Suffers constantly, and usually has a peptic fever.
5. Temperature 98.5° to 102° F. (38.9° C.).	5. Temperature 101° to 105° F. (38.3° to 40.5° C.)
6. Pulse accelerated, but of good quality.	6. Pulse never feeble and more rapid.
7. Attack lasts from five to fifteen days.	7. Attack seldom lasts less than a month, and may continue three months or more.
8. Often presents the appearance of good health.	8. Anæmic and weak.
9. Gonococci usually found on cover-slip preparation from the cervical, urethral, or vulvovaginal glandular secretions.	9. Gonococci not found in the secretions.
10. History of marital gonorrhœa.	10. Husband sound.

Appendicitis.	Tubo-ovarian Disease.
1. No previous local disturbances.	1. Genito-urinary functions previously disturbed. Usually a history of gonorrhœal or puerperal infection.
2. Chill usually absent.	2. Chill may precede fever.
3. Pain in right iliac region, sudden onset, acute, and not radiating to thighs.	3. Gradual onset, pain dull, continuous, and radiating.
4. Fever of variable degree.	4. Fever often entirely absent.
5. Muscular rigidity on right side of the abdomen.	5. No muscular rigidity unless complicated by peritonitis.
6. Inflammatory exudate about appendix three to five days after onset of symptoms.	6. Inflammatory exudate in the pelvis felt by vaginal examination at the onset of the symptoms.
7. Vaginal examination is rarely painful in appendicitis.	7. Always painful in tubo-ovarian disease.

Krussen says the appendix is involved in 15 per cent. of cases of tubo-ovarian disease.

Martin found appendicitis complicating right-sided salpingitis thirteen times in 276 cases. Ochsner, in 51 cases of appendicitis, found the tube and ovary involved fifteen times. Because of the frequency with which appendicitis and salpingitis are associated an inflammatory lesion in the right side of the pelvis should suggest a possible involvement of both of these structures, and no operation is complete on either of these structures without investigating the condition of the other. It is possible for a primary appendicitis to extend to the rectocæcal connective tissue and on to the pelvic connective tissue, giving rise to a secondary parametritis. A similar extension may take place along the peritoneum from the cæcum to the tubes and ovaries. The history of the onset and previous complaints are important considerations. Next in point of importance is the position of the swelling. Tumefactions in and about the tube are intimately connected with the uterus, and can be traced to its horn. In appendicitis the swelling is high up in the right iliac space, and in enlarging it extends downward into the pelvis in contrast to the swellings of tubo-ovarian diseases, which extend upward from the pelvis. In appendicitis it may be possible to palpate the tube and ovary apart from the exudate about the appendix.

A **subserous fibroid** may be simulated by a pyosalpinx when the tube is round, thick-walled, closely adherent to the uterus, and surrounded by a firm, sharply-defined exudate.

The clinical history is important. In pyosalpinx there is a history of infection, either puerperal or gonorrhœal, while in fibroids no such history is obtainable. In subserous fibroids the tumor is round, sharply circumscribed, not tender to pressure, usually freely movable, and unilateral. In pyosalpinx the tumor is more elongated, less sharply defined, tender to pressure, immovable, and often bilateral. In pyosalpinx there are evidences of infection in the lower genital tract, while with fibroids such is not the case.

Parametric exudates are often associated with pyosalpinx, and their differentiation may be impossible. The location and general contour are the distinguishing features. The onset and general clinical manifestations closely simulate each other.

A pyosalpinx is often bilateral, while a parametric exudate is commonly unilateral. The former lies on a higher level at the side

of or behind the uterus, while the latter lies low in the pelvis in direct contact with the vault of the vagina, running from the sides of the uterus directly outward. A pyosalpinx is more sharply circumscribed and is retort- or sausage-shaped. A parametric exudate is ill-defined.

Ovarian and parovarian cysts may closely resemble a hydrosalpinx. The diagnosis may be reserved for an exploratory incision. Hydrosalpinx is more often bilateral and elongated, and is more limited in size.

New formations of the tubes are very rare as compared with inflammatory lesions. The presence of ascites associated with tubal swellings speaks in favor of malignant new formations of the tubes. For the differential diagnosis of salpingitis from tubal pregnancy, see Chapter XVII.

TUBERCULOUS SALPINGITIS.

Etiology. In this country our knowledge of tuberculosis of the tubes is largely contributed to by Williams, Penrose, and Edebohls.

The following statistics are from Veit:

Wenkel found tuberculosis five times in 575 cases.

Donhoff found tuberculosis fourteen times in 509 cases.

Schramm found tuberculosis thirty-four times in 3389 cases.

Rosthorn found tuberculosis twice in 40 cases.

Williams found tuberculosis seven times in 91 cases.

Martin found tuberculosis seventeen times in 620 cases.

The above constitute a sum total of 79 in 5224 cases, or 1 case of tuberculous salpingitis in 66 abdominal sections.

Kundrat, in 140 abdominal sections for the removal of diseased uterine appendages, found tuberculous salpingitis in 4 cases and tuberculous endometritis in a single case.

Williams is undoubtedly correct in his statement that tuberculosis often goes unrecognized in a catarrhal or suppurative salpingitis for want of microscopic and bacteriologic examinations.

In two years' time at the Johns Hopkins Hospital the tubes removed for inflammatory lesions were found tuberculous in 8 per cent.

The great frequency of genital tuberculosis as a primary lesion in the tubes is shown in the statistics of W. Meyer, who reports 67 cases of primary tuberculosis of the genital tract, of which 57 were primary in the tubes.

We recognize a primary and secondary tuberculous salpingitis. Hegar, in his monograph of 1886, speaks of ascending and descending infections. The ascending form may be primary or secondary. The descending is always secondary.

THE AVENUES BY WHICH THE TUBERCLE BACILLUS GAINS ACCESS TO THE TUBES are :

1. By the blood current (metastatic invasion), as found in secondary involvement of the tubes from a primary focus in the lungs in the absence of a tuberculous lesion in the omentum, mesenteric glands, peritoneum, or bowel.

2. By continuity of tissue either from the peritoneum or the uterus. In 194 cases of secondary tuberculous salpingitis the peritoneum was primarily involved 110 times (Meyer.) When the tube is adherent to the bowel at the site of a tuberculous ulcer the infection may pass directly from the bowel to the tube without involving the peritoneum. Such infections are usually mixed with the colon bacillus.

Emmet described a case in which the tubercle bacillus travelled from the uterus through the tube and attacked the peritoneum, leaving the tube free.

3. By way of the lymph current. In this manner tuberculosis may be conveyed from the lower genital tract through the broad ligaments without passing through the uterus.

The infection is conveyed to the genital tract by the examining fingers, instruments, and coitus. Tuberculosis may be conveyed from the husband to the genital organs of the wife, even though his sexual organs are normal.

The infection may travel direct to the tubes without attacking the uterus, vagina, or vulva.

As predisposing causes may be mentioned age, the puerperium, and inflammatory lesions of the tubes. Tuberculous salpingitis may be found at any period of life from infancy to old age, the greatest number occurring from fifteen to thirty years of age. The age limits are wider than in any of the other forms of tuberculosis. The puerperal uterus, and particularly the placental site, is especially susceptible to tubercular infection.

Inflammatory lesions of the tubes are likely to have tuberculosis engrafted upon them. In this manner we have mixed infections of the tubercle bacillus with the gonococcus, staphylococcus, streptococcus, and colon bacillus.

Anatomical Diagnosis. As in other forms of salpingitis, we recognize an acute and a chronic stage.

Acute tuberculous salpingitis is very rare. The tube resembles the catarrhal form. There is a slight increase in the size of the tube together with marked congestion ; the mucosa is swollen and the secretion increased. The entire wall of the tube is infiltrated with small round cells, and in addition to these changes, which are those of acute catarrhal salpingitis, giant cells, tubercles, and tubercle bacilli are found in the mucosa and to a lesser degree in the muscularis. The lesion is more pronounced in the fimbriated end. The secretion collected in the lumen may be serous, bloody, or purulent.

From the acute the lesion may merge into a chronic stage closely resembling chronic catarrhal or chronic suppurative salpingitis. As a rule, there is no acute stage.

Miliary tubercles may aggregate to form large tubercles and nodules, which in turn may undergo caseous degeneration. The lumen of the tube may be filled with caseous material. A tuberculous pyosalpinx may form after the closure of either end of the tube.

There is no way of distinguishing tuberculosis of the tubes either in the acute or chronic stage from catarrhal or suppurative salpingitis except by the discovery of tubercles, giant cells, or tubercle bacilli. For this reason tuberculosis in a tube is often overlooked.

Gray or yellowish-gray tubercles ranging in size from a miliary tubercle to a hazelnut, may be seen on the surface of the tube and on the peritoneum near by. Adhesions about the tube are usually firm and extensive.

Williams describes a chronic fibroid tuberculous salpingitis in which there is a marked fibrous hyperplasia in and between the tubercles. Caseous degeneration is absent. This is a very chronic form, and may be regarded as a healing process.

Calcification of the tuberculous product is described by Klob, Penrose, and Rokitansky.

Clinical Diagnosis. Tuberculous salpingitis may be suspected when one or both tubes are found to be enlarged and tender to pressure, and the possibility of gonorrhœal or puerperal infection can be excluded. The presence of tuberculosis elsewhere in the body or in the husband, and a tuberculous family history, will speak for tuberculosis as the cause of the lesion in the tube.

In primary tuberculous salpingitis the symptom of greatest clinical importance is prolonged and painful menstruation.

The functions of the bowels and rectum are frequently disturbed.

Abdominal ascites is found in about 15 per cent. of cases. An evening rise of temperature and increase in the pulse rate are significant. As a diagnostic test tuberculin may be administered.

The local findings do not differ at first from those of acute and chronic salpingitis. Later nodules may be felt on the surface of the tube. There is nothing in the conjoined examination to positively identify a tuberculous tube.

Hegar lays great stress upon the peculiar condition of the middle third of the tube, which presents firm, nodular swellings. In the

FIG. 164.

Tuberculous Fallopian tube. (DUDLEY.).

absence of peritonitis there are no findings differing materially from those of salpingitis in general. The finding of tuberculous peritonitis naturally suggests tuberculosis of the tubes. An exploratory curettage may disclose tubercles in the scrapings.

In favor of tuberculous salpingitis the following data may be given:

1. The diagnosis of chronic salpingitis.
2. Tuberculous lesions elsewhere in the body.
3. Tuberculosis in the husband, particularly when involving the sexual organs.
4. Family history of tuberculosis.
5. Salpingitis in virgins (90 per cent. are said to be tuberculous).

6. Tubercle bacilli in the leucorrhœal discharge or in scrapings from the uterus.

7. Ascites.

SYPHILIS OF THE FALLOPIAN TUBE.

Literature on syphilis of the tube is scant and cases are of rare occurrence. Three authentic cases are described by Ballentyne and Williams, Donhoff, Bouchard, and Lepine.

Donhoff discovered the usual changes of catarrhal salpingitis in a postmortem examination of a baby, nine days old, which had died of syphilis.

The case recorded by Ballentyne and Williams was a seven months' child. There were numerous small gummata scattered throughout the tube wall and obliterating the lumen.

Buchard and Lepine reported a case, aged forty years. Death was from syphilis. There was a gumma in each tube the size of a hazelnut, and the lumina of the tubes were occluded.

ACTINOMYCOSIS OF THE FALLOPIAN TUBE.

We know little of actinomycosis of the tubes. Zemann, Stewart, Muer, and Granger have contributed all that is now known. In the reported cases the lesion was both primary and secondary in the tubes.

PARASITES OF THE FALLOPIAN TUBE.

Echinococci have been found in the tubes, the infection being secondary to that of the abdominal viscera, the pelvic bones, and the paraproctal connective tissue. Benoit reported 80 cases found in the literature.

NEW FORMATIONS OF THE FALLOPIAN TUBES.

All new formations of the Fallopian tubes are of rare occurrence.

Those described are: papilloma, polyp, myoma, fibroma, dermoid cyst, lipoma, fibromyxoma, cystoma, sarcoma, carcinoma, endothelioma, syncytioma malignum.

1. **Papilloma** arises from the endosalpinx. Sänger was able to collect only six cases in the literature. Simple papilloma takes the form of a villous or cauliflower growth which may fill and distend

the tube. The villosities may adhere and lock in cystic spaces. The growth is histologically constructed of connective tissue covered by a single layer of columnar epithelium, having no disposition to invade the connective tissue, as is the case in malignant papilloma. Metastasis does not occur. It has been suggested by Doran that benign papillary growths are of inflammatory origin. He bases his opinion on a certain, definite inflammatory reaction seen to accompany the growth. He believes gonorrhœa to be a potent factor.

2. **Polyps** of the tube are virtually inflammatory lesions. They are rarely found.

Fig. 165.

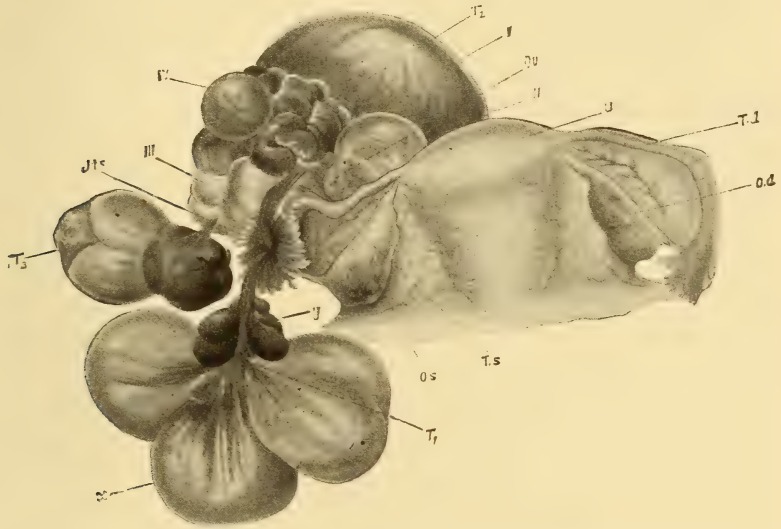

Fibromyxoma fimbriarum tubæ cystosum. (Martin.)

U. Uterus. *Td.* Right tube. *Od.* Right ovary. *Ts.* Left ovary. *Its.* Left infundibulum of the tube. *Os.* Left ovary. T_1I. Pedunculated tumor. T_2II. Pedunculated tumor. T_3. Secondary pedunculated tumor. *Ov.* Calcareous body resembling an ovary. *X.* Cyst containing dark yellow fluid. *Y.* Gelatinous tissue without cavities. *I.* Blood cysts with blood detritus. *II.* Blood cyst with fresh blood. *III.* Soft myxomatous tumor. *IV.* Soft myxomatous tumor.

3 and 4. **Myoma** and **fibroma** of the tube are not to be mistaken for the nodular swellings of salpingitis isthmica nodosa. Five cases are reported by Sänger. Bland Sutton reported one the size of an orange. V. Recklinghausen reported an adenomyoma of the tube arising from the duct of Müller.

5. **Dermoid cysts** of the tube are described by Pozzi and Richie.

6. **Lipomata** are not of such unusual occurrence in the tube. They are usually located between the two layers of the mesosalpinx, and have been known to attain the size of a hen's egg.

7. **Fibromyxoma cystoma of the fimbriæ** was described by Sänger (Fig. 165). There were three tumors connected by fimbriæ to a normal tube. They consisted of fibrous and myxomatous tissue.

8. **Sarcoma** of the tube has a papillary structure that cannot be distinguished from benign papilloma or carcinoma by the naked eye. But five cases are recorded.

9. **Carcinoma** of the Fallopian tube may be primary or secondary. Orthmann was the first to describe primary carcinoma of the tube. Like other new formations of the tube, carcinoma assumes a papillary form, and in its histological structure is not unlike papillary adenoma of the ovary and malignant adenoma of the uterus. Secondary carcinoma of the tube resembles the primary growth, and is an extension from a similar growth in the uterus and tubes. One-third of the primary carcinomata of the ovary extend to the tube.

It has been repeatedly observed that inflammatory lesions of the tubes serve as forerunners of carcinoma.

Le Count[1] says: "It is especially concerning tumors of the Fallopian tube that confusion has arisen; there has been quite a general failure to recognize that a diffuse hyperplastic inflammation is possible—a process that is strictly analogous to the polypous hyperplasia of other mucous surfaces—and that in certain typical examples it is as distinct from tumor growth as gastritis proliferans is from carcinoma of the stomach." He believes it fully demonstrated that there exists an imperceptible transition of hyperplastic processes of the tubal mucosa into those of true tumor growth, and that these may terminate in the production of benign tumors and then into a malignant new formation.

We find carcinoma of the tubes occurring about the time of the menopause—a time when inflammatory lesions are less frequent.

Sänger-Barth observed a direct malignant degeneration of the tubal mucosa. Doran and Fearne observed a malignant transformation in a benign papilloma.

Carcinoma of the Fallopian tube is commonly unilateral. According to Sänger-Barth, it usually arises from the middle and outer portions of the tube.

In conformity with many authors we will recognize two microscopic forms—the papillary and the alveolar.

[1] The Genesis of Carcinoma of the Fallopian Tube in Hyperplastic Salpingitis, with a Report of a Case and a Table of Twenty-one Reported Cases. Johns Hopkins Bulletin, March, 1901.

The papillary form consists of numerous papillæ composed of connective tissue and covered by columnar epithelium.

Alveolar carcinoma of the tube shows a greater proliferation of the epithelium and the grouping of these epithelial elements into nests.

CYSTIC NEW FORMATIONS OF THE FALLOPIAN TUBES.

Hydatids of Morgagni are transparent cysts containing a clear, watery fluid. They are found on the peritoneal covering of the tube and broad ligament, either isolated or arranged in groups. The fimbriæ of the tube may distend with a similar fluid and present the appearance of cysts of Morgagni.

Cysts as large as a walnut have been found in the mucosa of the tube, and are inclusions of the mucous folds.

Cysts of equal size are found in the musculature. These arise from the ducts of Gärtner.

The following classification is from Sänger :

1. Serous cysts, lying beneath the serous covering of the tube and varying in size to a child's head.
2. Lymphangiectasis.
   - *a.* As small cysts on the tube and ligament.
   - *b.* Winding canals or cysts located under or within the peritoneum of the tube and broad ligament.
   - *c.* Lymphangiectatic cysts, large and isolated, located in the subserosa of the tube and in the mesosalpinx.
3. Hydatids of Morgagni, which are to be regarded as physiological, and are located in the fimbriæ.

CHAPTER XXIX.

THE DIAGNOSIS OF THE DISEASES OF THE OVARIES.

Normal Anatomy of the Ovary. The ovaries are two in number, lying behind the broad ligaments on a level with the brim of the pelvis, midway between the horn of the uterus and the psoas muscle. The ovary is oval in shape and about the size of an almond. The average measurements, as given by Farre, are: Longitudinal diameter, one-third of an inch; transverse diameter, three-quarters of an inch; perpendicular diameter, three-eighths of an inch. The anterior border (hilum) is flat, and is attached to the broad ligament; the posterior border is convex and free. The ovary lies in a shallow concavity formed by the posterior layer of the broad ligament. This *fossa* of the broad ligament is a remnant of the peritoneal pouch in which the ovary of the rat and other mammalians is enclosed. Such a fossa was observed in a case by J. Clarence Webster.

The **ligaments of the ovary** are two in number—the ovarian ligament and the infundibulo-pelvic ligament. In addition to these ligaments the ovary is attached at its hilum or anterior border to the posterior layer of the broad ligament. The *infundibulo-pelvic ligament* connects the outer end of the Fallopian tube to the side wall of the pelvis, and may be regarded as that portion of the upper border of the broad ligament not occupied by the Fallopian tube. It is about 2 cm. in length.

The *ovarian ligament* extends from the horn of the uterus to the inner end of the ovary, and is about 3 c.cm. long.

THE HISTOLOGY OF THE OVARY.

The ovary is covered with a layer of nucleated columnar cells continuous at the hilum with the peritoneal endothelium. At the point of transition is a white, glistening line called the "white line of Farre." The epithelium covering the ovary is called the "germ epithelium of Waldeyer," and beneath it is a fibrous layer known as the tunica albuginea.

The framework of the ovary is of connective tissue, and is divided into cortical and medullary portions, the former lying external to the latter. The Graafian follicles are scattered throughout the ovary. Nerves, bloodvessels, lymphatics, and muscular fibres are also found in the connective tissue. The medullary portion is more vascular than the cortex.

FIG. 166.

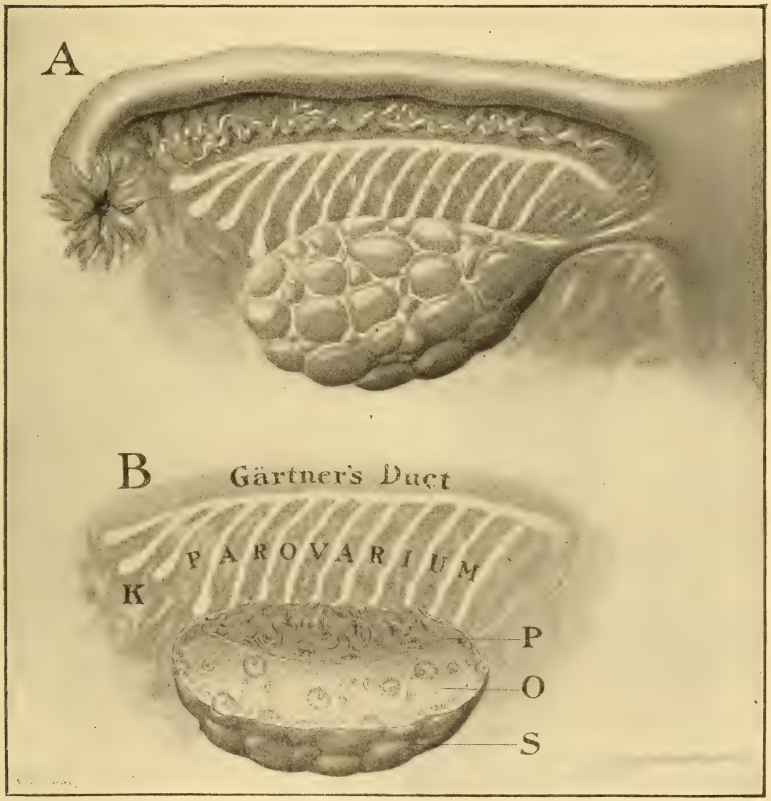

Cyst-producing region of the ovary and its surroundings. (DUDLEY).
A. Uterus, Fallopian tube, parovarium, and ovary. B. Gärtner's duct, parovarium, and ovary shown in section; P, paroöphoron, sometimes called the vascular or medullary zone; O, oöphoron, this is the egg-bearing portion, sometimes called parenchymatous zone, sometimes the cortical portion; S, free external surface of ovary; K, Kobelt's tubes.

The **Graafian follicles** number 40,000 to 70,000 in the infant ovary. They vary in size from one one-hundredth to one-thirtieth of an inch in diameter. The younger and smaller follicles occupy the medullary portion, and as they grow larger they are

found to occupy the cortical portion. A Graafian follicle consists of :

1. A tunica fibrosa and membrana propria.
2. The membrana granulosa and discus proligerus.
3. The liquor folliculi.
4. The ovum surrounded by the discus proligerus and composed of :

a. Zona pellucida, a homogeneous external membrane.
b. Yolk protoplasm.
c. Germinal vesicle.
d. Germinal spot.

Methods of Examination. The bladder and rectum should be empty, and all restricting clothing removed from the waist. An

FIG. 167.

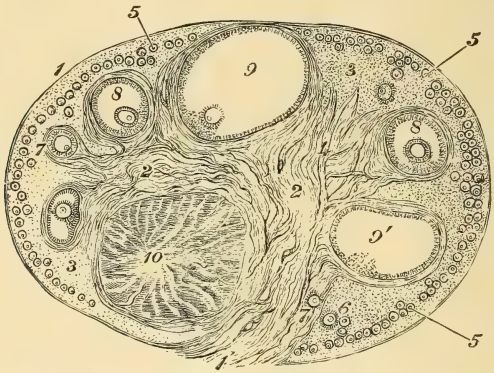

Section of the ovary. (After SCHRON.)
1. Outer covering. 1'. Attached border. 2. Central stroma. 3. Peripheral stroma 4. Blood-vessels. 5. Graafian follicles in their earliest stage. 6, 7, 8. More advanced follicles. 9. An almost mature follicle. 9'. Follicle from which the ovum has escaped. 10. Corpus luteum.

anæsthetic is not always required, but is helpful in all cases and indispensable in many. The patient is placed in the lithotomy position. The abdomino-vaginal method is usually chosen. If the vagina is short, resisting, or sensitive to pressure, or if the hymen is intact, it will be advisable to make a recto-abdominal examination. When the ovary lies behind the uterus it may be better palpated through the rectum.

As a matter of routine, it is advisable to first locate the uterus, then follow from the horn of the uterus along the course of the tube to the ovary. The right ovary is best detected by the finger of the right hand in the vagina and the left ovary by the finger of the

left hand. It is not, as a rule, necessary to change hands; either the right or the left hand will suffice in most cases for the examination of both ovaries.

In difficult cases Ulmann recommends filling the rectum with a colpeurynter to force the ovary upward and forward within easier reach of the examining finger.

ANOMALIES IN THE DEVELOPMENT OF THE OVARY.

1. **Absence of one or both ovaries** may occur as a congenital defect, or the entire ovarian tissue may be completely lost through atrophic changes and new formations. When both ovaries are absent the uterus and tubes are either altogether wanting or poorly developed. Menstruation and childbearing are impossible. In a case reported by Quain there was vicarious menstruation from the nose. Two of Martin's cases were sexual perverts, one a nymphomaniac, the other a prostitute. Martin collected twenty-two cases of congenital absence of one ovary. In one of his cases the uterus was normal, but the right tube and ovary were absent. In another the uterus and vagina were rudimentary, and the left tube and ovary absent. In nine of the twenty-two cases there was a uterus unicornis. The vagina and vulva are seldom influenced by the absence of a single ovary, and may be well-formed where both ovaries are absent.

Torsion of the tube or adhesions surrounding the tube and ovary may shut off the blood supply and cause complete atrophy of the ovary.

The diagnosis of the absence of one or both ovaries can only be made by inspection after the abdomen is opened.

2. **One or Both Ovaries May Be Congenitally Small.** This condition may be primary or secondary. Martin reports thirty-six cases of rudimentary ovaries; none menstruated, and only seven experienced the molimena. Twelve of the thirty-six cases had a rudimentary vagina, and in every case the uterus was undersized.

Rudimentary ovaries have been recognized by a conjoined examination, though this is exceptional.

3. **Supernumerary ovaries** are accounted for either as an acquired segmentation of the ovary or as a congenital defect. In 500 cases supernumerary ovaries were found eighteen times by v. Wenkel. Sänger reported one that measured 1 cm. by 0.04 cm. As a rule,

they are much smaller. Pregnancy following the removal of both ovaries is explained by the presence of a supernumerary ovary.

A true supernumerary ovary is a rare finding, but an accessory ovary constricted off by adhesions is a comparatively frequent lesion. These accessory ovaries may be connected with the ovary by a pedicle or be completely isolated. Small pedunculated bodies are frequently seen near the ovaries; these are detached tubes of the parovarian, small myomata of the ovarian ligament, or stalked corpora fibrosa.

The clinical significance of supernumerary ovaries is in the continuation of the menstrual and childbearing functions after the removal of both ovaries.

The diagnosis can only be made by direct inspection.

4. **One or Both Ovaries May Be Congenitally Large.** This anomaly is occasionally found associated with precocious development of the sexual organs. Hypertrophy of the ovary is more often an acquired lesion. It is physiological during pregnancy and is commonly associated with uterine fibroids. It must be remembered that the normal ovary varies in size within wide limits.

CHANGES IN THE POSITION OF THE OVARY.

The normal position of the ovary is at the level of the brim of the pelvis midway between the horn of the uterus and the psoas muscle. There is a limited physiological range of motion influenced by changes in the position of the uterus, the filling and emptying of the bladder and rectum, the respiratory movements, and changes in the attitude of the patient. During pregnancy the ovaries are elevated into the abdominal cavity.

Pathological causes of misplaced ovaries are:

1. Displacements of the uterus and tubes.

2. Inflammatory lesions of the ovaries, increasing the weight of the ovaries and causing them to fall to a lower level, or adhesions about the ovary drawing the organ out of place.

3. New-growths about the ovaries, crowding them out of place.

4. Increase in size and weight of the ovaries from abscesses, hæmatomata, and tumor formations, causing them to prolapse.

DESCENSUS OVARII.

Classification (Sänger). 1. **Descensus lateralis**, in which the ovary descends no further than the upper border of the sacral ligament.

2. **Descensus posticus**, in which the ovary descends below the upper border of the uterosacral fold.

The causes of descensus ovarii are:

1. Increase in the weight of the ovary by:
   a. Hypertrophy and hyperplasia.
   b. Congestion.
   c. Hæmatoma or abscess.
   d. New formations.
2. Relaxation of the supporting ligaments of the ovary.
3. Retropositions and prolapsus uteri.
4. Pelvic adhesions pulling upon the ovaries.
5. Pelvic and abdominal tumors pushing the ovaries downward.
6. Severe falls.

In 4000 cases Martin found the ovary descended in 564, and of this number a single ovary was prolapsed eighty-six times. The greatest number was found between the ages of twenty-five and thirty. They are rarely seen after fifty years of age.

A prolapsed ovary rarely remains normal. The dependent position interferes with the return circulation, and this leads to a chronic hyperplasia of the ovary (chronic ovaritis). In the 564 cases reported by Martin chronic ovaritis was found 401 times. In 15 there was cystic degeneration of the ovary, and in 154 cases there was periovaritis with fixation from adhesions.

The diagnosis is based altogether upon the physical findings. The symptoms are wholly unreliable in identifying the lesion. Excessive symptoms occurred only twenty-six times in the 564 cases of Martin. Painful menstruation, dyspareunia, and pain in defecation are those commonly present, though they are by no means constant. How much parametritis and other complicating lesions have to do with these symptoms cannot be determined. Sterility does not necessarily follow. It is difficult if not impossible to demonstrate that the reflex symptoms, such as headache and dyspepsia, are dependent upon diseases of the ovary.

The displaced ovary is recognized by its size, form, consistency,

and sensitiveness to pressure. An anæsthetic is always of advantage and may be indispensable. A recto-abdominal examination is often more satisfactory than a vagino-abdominal.

Not only must the position of the ovary be located, but it is necessary that the cause of the displacement be ascertained.

HERNIA OF THE OVARY.

Hernia of the ovary may be congenital or acquired. Congenital hernia of the ovary is commonly bilateral, and acquired hernia unilateral. Inguinal hernia is by far the most frequent form, though the ovary may descend through the crural ring, navel, ischiadic and obturator foramina. In pseudohermaphrodites the ovary, having descended through the inguinal canal, is likely to be mistaken for the testicle. Menciere reports a single case in which the uterus together with the ovaries and tubes were found in the hernial sac. So long as the ovary is not incarcerated and the circulation remains undisturbed no symptoms will arise. When from compression or torsion the return circulation is impeded the ovary becomes swollen from venous stasis, and may finally become gangrenous. The symptoms inaugurated by this condition are pain, vomiting, and collapse.

The diagnosis rests exclusively upon the finding of the ovary. When the ovary and tube alone are found in the hernial sac and the abdominal wall is not thick and sensitive, there should be little difficulty in establishing a diagnosis. The ovary is recognized by its size, form, consistency, and sensitiveness to pressure, and in a conjoined examination the Fallopian tube is found to connect the displaced ovary with the uterus. The percussion note is dull in contrast to the tympanitic note of the bowel. The absence of the corresponding ovary in the pelvis is evidence in favor of hernia of the ovary.

A hydrocele of the canal of Nuck is distinguished from hernia of the ovary by the cystic, fluctuating character of the swelling and by the presence of the ovary in the pelvis.

It is difficult to distinguish strangulation and gangrene of the ovary from a strangulated intestinal hernia. Tympany on percussion is elicited in either case. Finding the ovary in the pelvis will exclude the possibility of hernia of the ovary. Not infrequently an exploratory incision is required to establish the diagnosis.

When the hernia is congenital or when acquired before the time

of puberty the condition may go unrecognized until puberty, when the ovary becomes enlarged and tender during the menstrual periods.

HYPERTROPHY OF THE OVARY.

The size of the ovary varies within wide limits, and hence it is not always possible to distinguish between a normal ovary and one that is hypertrophied.

In true hypertrophy there is an increase in the amount of ovarian tissue. This condition is not to be confounded with hyperplasia of the connective tissue stroma, the result of passive congestion and inflammation. There are no characteristic clinical signs of hypertrophy of the ovary. Early puberty, unusual sexual vigor, and a late menopause are the ascribed manifestations.

ATROPHY OF THE OVARY.

The physiological atrophy of the ovary in the climacteric may occur some time before the menstrual periods altogether cease or may be delayed many years. Atrophy of the ovary usually precedes the menopause by a year or more, but is seldom complete for several years after the menopause.

A pathological atrophy of the ovary results from the interference with the nutrition of the organ, and from direct and continuous pressure upon the ovary by tumor formations and inflammatory exudates. Inflammatory adhesions may contract about the ovary and tube, limiting the blood supply and bringing on atrophy. Swellings of the tubes, uterus, and ovaries may cause pressure atrophy. Atrophy of the ovary may follow the infectious and contagious diseases, syphilis, diabetes, the primary and secondary anæmias, myxœdema, morbus Bassedowii, tabes dorsalis, acromegaly, and poisoning by arsenic and phosphorus.

Varicosities of the veins of the mesovarium have been reported by Palmer Dudley as being responsible for atrophy of the ovary. Martin, in his report of forty cases, takes the position that the majority of women with atrophied ovaries suffer from pulmonary tuberculosis.

The menstrual functions become less active as the atrophy of the ovaries progresses. The individual often increases in weight. Nervous disturbances are frequently complained of. These are pain and throbbing in the head, flashes of heat and cold, insomnia,

irritability of temper, and despondency. A positive diagnosis is reserved until direct inspection of the ovaries can be made.

PARASITES AND FOREIGN BODIES OF THE OVARY.

The **echinococcus** has been identified in the ovary by Freund, Schultze, Schatz, Orth, and Pfannenstiel. The diagnosis can only be made by the finding of the organism in the ovary.

Foreign bodies have rarely been found in the ovary. Calcareous concretions and needles have been discovered.

CIRCULATORY DISTURBANCES IN THE OVARY.

Etiology. There is a physiological hyperæmia of the ovary during menstruation, coition, and pregnancy.

The ovaries share in a general pelvic congestion, hence all embarrassments to the general circulation from diseases of the heart, lungs, kidney, and liver, from abdominal tumors, collections of fluid in the abdomen, and constipation will cause passive congestion of the ovaries.

In certain hemorrhagic diseases, such as scorbutus and purpura, there are hemorrhages into the substance of the ovaries. Hyperæmia of the ovary is a constant accompaniment to all the inflammatory lesions in the pelvis. The more acute the lesion the greater the hyperæmia. As remarked in the chapter on Descensus Ovarii, the ovary is congested.

Hæmatoma of the ovary is often of obscure origin. It is possible for hemorrhages to occur in the ovary as the result of any of the above-named causes for hyperæmia. As an underlying factor, we may have degenerative changes in the bloodvessels of the ovary. Such collections of blood are usually found in the follicles; hemorrhages into the interstitial spaces are less common. Virchow and Olshausen each reports a case complicating scorbutus. Torsion of the tube and ovarian ligament may cause hemorrhages into the stroma and follicles of the ovary.

Martin reported 109 cases in which blood collections in the ovaries varied in size from that of a bean to a man's fist. Of this number 25 were observed between the ages of eighteen and fifty-two; 22 were not married; the right ovary was affected forty-seven times, the left fifty-five times, and both ovaries thirty-two times.

In all but 8 cases there was more or less peritonitis, and 4 of the 8 had uterine fibroids, 1 chlorosis, 2 endometritis and metritis, and the eighth practised masturbation. In 26 of the 109 cases a traumatic cause could be traced in the history, such as the passing of the uterine sound, the wearing of pessaries, and the replacing of the uterus. Hæmatoma is an unusual finding in an otherwise perfectly normal ovary. Any of the new formations and inflammatory lesions may accompany hæmatoma.

Anatomical Diagnosis. In hyperæmia of the ovary we find a slight increase in size in all diameters and a more livid color. Following a long-standing hyperæmia there is an increase of the connective tissue. The tunica albuginea is thickened, and the follicles, failing to rupture through the thick and resisting tissue, lead to follicular degeneration of the ovary.

Hæmatoma Ovarii. Hemorrhages into the substance of the ovary are found in one or more of three places—follicles, corpus luteum, or connective spaces.

1. *Hemorrhages into the follicles* may distend them to the size of a man's fist. More than a single follicle may be involved. The stretched walls of the follicles with their contained blood appear of a bluish tint. The contained blood may or may not be coagulated and is dark red or grayish-brown. The inner surface of the follicles is smooth, though occasionally made uneven by coagulated blood adhering to the surface. Fatty degeneration of the epithelium lends a yellowish tint to the inner surface. The contained blood may be wholly absorbed or converted into fibrin, which by contracting may obliterate the follicles. Occasionally the follicle bursts, and the blood escapes into the peritoneal cavity. The escaped blood has been known to set up a peritonitis, and cases are recorded where the hemorrhage was fatal. Infection of the blood may give rise to abscess formation in the ovary.

2. *Hemorrhages into the corpus luteum* are identified by the corrugated lining membrane of lutean cells or by a granular appearance. Such bodies are single, and are located in the periphery of the ovary. Hæmatoma of the corpus luteum has been known to attain the size of a child's head.

3. *Hemorrhage into the connective tissue spaces* is less common. Such hemorrhages are often multiple, and are seldom of large size. Multiple punctate hemorrhages may be distributed through the stroma and add materially to the size of the ovary.

The blood is found in various stages of preservation. In follicular hæmatoma the epithelium lining the blood cyst may be well preserved, assuming a variety of shapes from cylindrical to flattened. Several layers may be found. In the larger hæmatomata there may be but a single layer of flat epithelium, and even this may partially or wholly disappear through pressure atrophy. Blood extravasations and congested bloodvessels may be seen in the tunica propria.

In the hæmatoma of the corpus luteum the wall is more congested and thicker than in the preceding variety. On the inner surface of the cyst there is a deposit of fibrin, in the meshes of which are disintegrated blood and small round cells. Beneath this are the lutean cells, varying in number, size, and form according to the age and size of the hæmatoma. External to the lutean cells is the tunica externa, composed of fibrous tissue.

Clinical Diagnosis. There may be no clinical manifestations. The ovary is usually tender to pressure. Pain in the ovary may radiate to the back and thighs. The pain is at its height during the period of premenstrual congestion, and abates when a free flow is established.

It has been said that when pelvic congestion is present and a throbbing pain develops in the ovary, with no elevation of temperature, it is to be inferred that a hæmatoma has developed in the ovary. A diagnosis can only be made on exploration of the ovary.

In a bimanual examination the ovary is invariably found enlarged, though it is seldom larger than a walnut. The consistency is tense and elastic. Although sharply circumscribed, the ovary is usually irregular in outline. The ovary is found on a lower level than normal, often lying low beside or behind the uterus.

It is difficult and often impossible to differentiate hyperæmia, hæmatoma, and inflammation of the ovary. The pain and tenderness may be equally intense, and there may be no distinction in the physical findings. In inflammation the symptoms are usually of longer standing and more pronounced. The history of the onset should be considered.

INFLAMMATION OF THE OVARY (Oophoritis, Ovaritis).

For practical clinical purposes inflammation of the ovary will be classified as acute and chronic.

I. **Acute Ovaritis.** Acute inflammation of the ovary is due to direct invasion of the ovary by bacteria or to the influence of their toxic products. Certain inorganic poisons (phosphorus, arsenic) act in a similar manner.

All the infectious diseases may be complicated by ovaritis, including the exanthemata, typhoid fever, cholera, pneumonia, influenza, dysentery, wound infections, gonorrhœa, and tuberculosis.

The micro-organisms found in the ovary under such conditions are the staphylococci, streptococci, pneumococci, gonococci, typhoid bacilli, and actinomyces.

In all the above-named causes of ovaritis the same general anatomical changes follow, there being no essential difference in the anatomy of the various etiological forms.

Pfannenstiel considers acute ovaritis under the heads: septic and gonorrhœal.

1. Acute septic ovaritis is a complication of puerperal sepsis, but a similar lesion may arise from the non-puerperal septic agencies above named.

The ovary is uniformly enlarged and reddened, and the stroma becomes infiltrated with a serous exudate and small round cells. The follicular epithelium degenerates, the ovum dies and is absorbed, and the liquor folliculi becomes turbid. Suppuration may follow, leading to the formation of abscesses in the corpus luteum, follicles, and interstitial spaces.

Death may follow, but resolution is the rule, and this is possible either by complete absorption of the exudate leaving the ovary in a normal condition, or by atrophy of the connective tissue, with its subsequent contraction.

2. Acute gonorrhœal ovaritis is rarely primary, and is almost invariably secondary to salpingitis. In exceptional cases the infection is conveyed from the cervix through the lymphatics of the broad ligaments to the hilum of the ovary. Wertheim has succeeded in demonstrating the gonococcus in the ovary.

II. **Chronic ovaritis** is a clinical term designating a long-standing lesion of the ovary characterized by hyperplasia of the stroma and secondary involvement of the parenchyma.

Chronic ovaritis may be the terminal stage of an acute infection of the ovary. Any condition causing prolonged congestion of the ovary will result in chronic ovaritis, such, for example, as sexual excesses, menstrual congestion, subinvolution, malpositions of the

uterus, habitual constipation, incompetency of the cardio-vascular system, pelvic and abdominal tumors, and disorders of the organs of digestion.

Cystic Degeneration of the Ovaries. Both ovaries are commonly involved. They are enlarged, and the external surface is deeply fissured and studded with follicular swellings. They are firm in consistency. On cross-section of the ovary there are seen numerous small cystic spaces distributed throughout the thickened cortex. These cysts are usually not larger than an eighth of an inch in diameter. They may be so numerous as to almost wholly replace the cortical tissue and often protrude upon the surface of the ovary as transparent vesicles. Occasionally they are pedunculated. The Germans (Hegar) speak of this condition as "klein cystiche degeneration." Ziegler regards the lesion as a follicular hypertrophy.

FIG. 168.

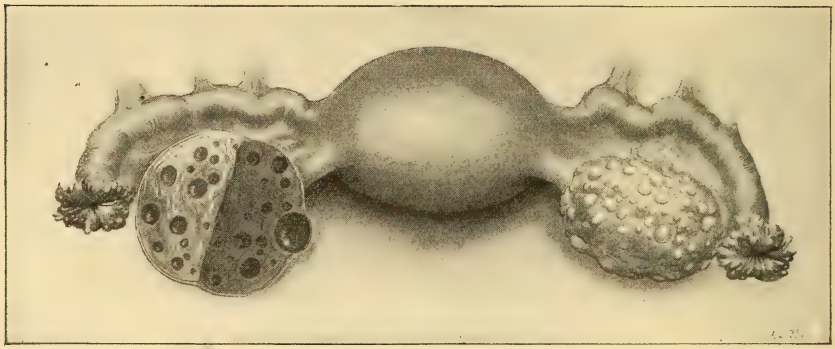

Microcystic degeneration of the ovary; the ovary to the right shows numerous small cysts scattered over the surface; these are Graafian follicles which have undergone cystic degeneration, and may take on excessive growth and develop into large tumors, or may remain as here represented; on the other side is shown a similar condition of the ovary in section. (DUDLEY.)

It is held by many that the hypertrophy of the follicles is of inflammatory origin, the result of chronic ovaritis. Virchow called the lesion catarrh of the follicles. He associated it with accompanying catarrh of the uterus and tubes. Klob, Popoff, and Stratz also contended for the inflammatory origin of cystic degeneration of the ovaries.

Orth raises the question as to whether the lesion is pathological or an exaggerated physiological process. Nagel denies their pathological significance and regards them as purely physiological. They are repeatedly seen in the ovaries of infants and even before the period of viability.

The tunica albuginea is thickened save where it is thinned by pressure of the underlying cysts. The covering germinal epithelium is intact. The connective tissue stroma of the ovary is greatly increased in amount, unless the number and size of the follicles replace the stroma. There is little or no round-cell infiltration except during periods of acute exacerbation. The arteries are thick-walled, and may undergo hyaline degeneration. From the bloodvessels of the tunica interna a serous exudate fills the follicles, giving rise to what is known as hydrops folliculi. In the distended follicle the lining membrane becomes compressed and the ovum is absorbed.

Abscess of the Ovary. We may speak of acute and chronic abscesses of the ovary.

1. Acute abscess of the ovary is seldom recognized in a clinical examination. Such abscesses commonly arise in the course of acute general septic infections with a speedy fatal termination. Hence it is the rule that acute abscesses of the ovary are usually discovered in a postmortem examination.

2. Chronic Abscess of the Ovary. Menge, in 33 cases of ovarian abscesses, found the gonococcus in 9, the colon bacillus in 4, the streptococcus in 1, saprophitic anaërobic micro-organisms in 1, and in 18 the pus was found sterile. Martin found the pus sterile in 20 out of 55 cases.

Anatomical Diagnosis. As in hæmatoma, so in abscess of the ovary, there are three localities in which they may develop—the interstitial spaces, the follicles, and the corpus luteum.

Interstitial abscesses are found in all portions of the ovary. They are usually multiple and irregular in outline. The wall of the abscess is composed of connective tissue infiltrated with small round cells.

Follicular abscesses usually present a smooth wall of connective tissue. They may be single or multiple, and may attain the size of a man's head.

A **corpus luteum abscess** is recognized by the corrugated inner lining of the cyst wall. The abscess lies superficially and is usually single. The blood coagulum in the centre of a corpus luteum is a favorable nidus for pyogenic micro-organisms. This, with the superficial position of the corpus luteum and its intimate connection with an infected tube, makes infection easily possible.

Tubo-ovarian abscess, by which is understood a pyosalpinx directly communicating with an ovarian abscess, may be primary or sec-

ondary. A primary tubo-ovarian abscess begins as a pyosalpinx and an ovarian abscess, which later communicate and form one continuous abscess cavity. A secondary tubo-ovarian abscess arises from a secondary infection of a primary tubo-ovarian cyst.

In 110 cases of ovarian abscesses Martin found a tubo-ovarian abscess in 18.

Clinical Diagnosis of Ovaritis. The clinical picture is a variable one. The ovary is seldom involved alone, hence the clinical picture of ovaritis is seldom observed independently of complicating inflammatory lesions.

Acute ovaritis causes a rise of temperature and increase in the pulse rate. There is exquisite tenderness on pressure over the ovary—so much so, that an anæsthetic is required in palpating the ovary. For practical purposes a diagnosis of acute inflammation of the adnexa is sufficient. When the acute stage of the inflammation has subsided the ovary can be outlined.

In **chronic ovaritis** there is no elevation in temperature. Pain in the region of the affected ovary radiating to the groin and thigh is the most constant symptom. Occasionally the pain recurs at regular intervals between the menstrual periods ("müttleschmertz"). The explanation of this phenomenon is the ripening and bursting of the follicles through the resisting stroma and tunica albuginea. Individuals show a marked difference in their susceptibility to pain. Chronic ovaritis may exist to a marked degree without causing pain, while on the other hand, a very slight involvement of the ovary may cause intense suffering. The pain is aggravated during the period of premenstrual and menstrual congestion. The pain of chronic ovaritis is often but the expression of a general nerve storm, and it is difficult, indeed, to determine just how much the lesion in the ovary has to do with the pain.

In the early stage of chronic ovaritis the menses are increased, but, as the true ovarian tissue gives place to connective tissue, the menses become more and more scanty. Sterility is a common complaint, and is the immediate result of such complicating lesions as salpingitis and endometritis more often than of ovaritis. When the cause of sterility rests in the ovary, the explanation lies in the destruction of the ova and in the failure of the follicles to rupture through the thickened stroma, tunica albuginea, and surrounding adhesions.

When suppuration of an ovary follows upon ovaritis the symp-

toms are all aggravated. In acute abscess of the ovary the symptoms are all marked by the complicating peritonitis, metritis, and salpingitis.

Increase in the pulse rate and elevation of temperature are to be expected in acute abscesses, but are often wanting in the chronic stage.

In determining the cause of the infection it is important to consider the clinical history, as a possible childbirth, abortion, or gonorrhœal infection may play a part. Physical examination of the pelvic viscera and of the leucorrhœal discharge may reveal a gonorrhœal or tuberculous infection of other portions of the genital tract.

The diagnosis is made in part by a consideration of the above symptoms, but an absolute diagnosis cannot be made without a physical examination, and is often reserved until an exploratory incision offers further light.

Tenderness and pain may be complained of in the presence of a perfectly normal ovary, and chronic ovaritis may exist without causing pain or tenderness on pressure.

Direct palpation of the ovary in a bimanual examination under anæsthesia is indispensable in making a diagnosis. The slight increase in size and consistency of the diseased ovary, together with evidence of infection elsewhere in the genital tract, will best suggest the diagnosis.

The diagnosis cannot be based upon the increase in size in the absence of pain and tenderness. Hypertrophy and cystic degeneration of the ovary will cause a similar increase in the size.

Abscess of the ovary cannot be diagnosed from constitutional symptoms. Chills, fever, rapid pulse, and pain may all be absent in the presence of an ovarian abscess.

The diagnosis is based upon the finding of a rounded swelling beside or behind the uterus, and not immediately connected with it. The tube may be traced from the swelling to the horn of the uterus. The ovary is tender to pressure, and is always restricted in its movements by adhesions. Fluctuation is not often elicited.

It is sometimes possible to judge of the liability of the abscess to rupture by the degree of tension associated with the pain. At such a time the temperature and pulse are usually elevated, and there are increasing pressure symptoms referred to the rectum and bladder, and along the sacral nerves to the thighs and back.

On rupture of the abscess the temperature may drop and the pain cease. If the abscess has ruptured through the vagina, rec-

tum, bladder, or abdominal wall there will be an escape of pus, which is usually fetid and mixed with blood. If the abscess ruptures into the peritoneal cavity and the pus is confined by adhesions, there will be a moderation in the temperature and pain. If no adhesions protect the peritoneum there will rapidly follow symptoms of general suppurative peritonitis. Return of the abscess in the ovary is of common occurrence. Fistulæ and chronic suppuration are possible results which demand the removal of the sac long after a spontaneous rupture.

Differential Diagnosis. **Congestion of the ovary** may be mistaken for an inflammation. The history of the development of the lesion and the duration and intensity of the disturbance are the guides to a diagnosis. No sharp line can be drawn between these lesions even by anatomical studies of removed ovaries, and hence it is impossible to clearly define the two conditions.

Salpingitis is often associated with ovaritis, and the two may be inseparably connected, so that it is impossible to distinguish the ovary from the tube in a bimanual examination. Adhesions binding the tube and ovary may unite them into a single rounded or oblong tumor mass.

In general it may be said that inflammatory swellings of the tube are elongated, retort-shaped, and immediately connected with the horn of the uterus, while inflammatory swellings of the ovary are round and not so intimately connected with the uterus.

Parametric exudates lie at a lower level in the pelvis than does an ovarian abscess. The swelling is more diffuse and is absolutely immovable. Furthermore, a parametric exudate is intimately connected with the uterus, and is more often unilateral than are ovarian abscesses. An ovarian abscess is slower in its development and slower in being absorbed than is a parametric exudate.

Perityphlitis is usually not difficult to distinguish from inflammatory lesions of the ovary. The higher location on the right side and the accompanying disturbances of the digestive organs will usually serve to exclude the ovary. The diagnosis will be made with certainty by outlining the ovary apart from the perityphlitic exudate.

New-growths of the ovary, including ovarian cysts, are less tender to pressure, the pain is rarely so fixed, and the outline of the tumor is often quite irregular. Finally, their tendency to grow to a large size will serve as points of distinction.

SIMPLE CYSTS OF THE OVARY.

Among simple cysts of the ovary will be included those cystic formations occupying an intermediate position between the cystic inflammatory lesions and the cystic new formations.

1. **Follicular Cysts.** See Chronic Ovaritis.

2. **Corpus luteum cysts**, as the name implies, arise from the corpus luteum, and hence are single and are located on the periphery of the ovary. As compared with follicular cysts, they are thick-walled. In size they vary from a bean to a man's head.

The wall of the cyst presents the characteristic yellow corrugated appearance of the luteum cell layer, and external to this is the pale, fibrous envelope. The contents of the cyst is commonly a clear, serous fluid ; this is occasionally mixed with blood and degenerated cells.

3. **Tubo-ovarian Cysts.** These have been previously referred to.

Rathorn gives the following groups in explanation of the origin of tubo-ovarian cysts :

Group I.

1. Cases in which a pyosalpinx becomes adherent to the wall of an ovarian abscess, with subsequent communication established between them. Later the formed elements of the pus are absorbed, leaving a serous fluid.

2. Adhesions of the pavilion of the tube to the wall of the supporting ovarian cyst, with subsequent development of hydrosalpinx and perforation of the cyst into the tube.

3. Adhesions of a hydrosalpinx to a papillomatous cyst, with subsequent perforation of the intervening wall by papillary growths.

Group II.

1. Cases in which a hydrosalpinx becomes adherent to the wall of a follicular cyst, with subsequent perforation of the septum.

2. Cases in which the fimbriæ of a previously diseased tube become caught in the opening of a ruptured follicle at the moment of rupture and become adherent to the wall of the follicle.

Anatomical Diagnosis. A tubo-ovarian cyst may distend to the size of a child's head. The general form is that of a retort. The wall is thin and transparent. Occasionally there are adhesions about the cyst. No evident ovarian tissue may be found.

The interior of the cyst resembles a hydrosalpinx on one side and a follicular or corpus luteum cyst on the other. There is but a

single cavity. The point of union of the cyst and tube is sharply defined. The tubal portion is lined with ciliated epithelium and the ovarian portion either with a fibrous or granular surface layer or with a low type of epithelium. The contents is clear serum, rarely blood-stained.

The clinical diagnosis cannot be made from hydrosalpinx. The diagnosis is only made by a careful examination of the specimen after its removal.

INFECTIOUS GRANULOMATA OF THE OVARY.

Of the infectious granulomata we find in the ovary tuberculosis, syphilis, actinomycosis, and leprosy.

Tuberculosis.

Etiology. Tuberculosis of the ovary is a comparatively rare lesion. One hundred and eighty-four cases were reported by von Guillemain, Wolf, Martin, and Bulius. In Wolf's cases 42 were bilateral, 48 unilateral. No case of primary tuberculosis of the ovary has been reported. However, the ovary may be the primary seat of attack in the genital organs when the initial lesion lies elsewhere in the body; but this is rare. As a rule, the primary lesions lie within the tube or in the peritoneal cavity. In 410 cases of tuberculosis of the genital tract the ovary was involved in 84. Bland Sutton says: "An ovarian abscess unassociated with salpingitis is in nearly all cases tuberculous. Records of ovarian tuberculosis require careful and critical consideration before acceptance." The invasion of the ovary is usually by direct continuity from the peritoneum and tubes to the ovary; more rarely by the lymph and blood streams.

Anatomical Diagnosis. Martin classifies the tuberculous lesions of the ovary as follows:

1. **Tuberculous periovaritis,** in which the tubercles are distributed over part or all of the surface of the ovary as miliary or larger tubercles. It is a direct invasion of the ovary from the tube and peritoneum.

2. **Tuberculous ovaritis,** in which miliary tubercles are distributed throughout the ovarian tissue. More often distinct cheesy masses, or tuberculous abscesses, are found to occupy the interior of the

ovary. Cheesy masses rarely reach the size of a hazelnut, while tuberculous abscesses may attain the size of a child's head.

Tuberculous tubo-ovarian abscesses have been reported by Williams, Menge, and Mosler. The author adds another case. As a rule, the lesion is bilateral; occasionally ascites accompanies tuberculosis of the ovary, and is the result of tuberculous peritonitis.

Microscopic Diagnosis. In tuberculous periovaritis there are typical tubercles on the surface and in the neighborhood of the ovary. The surface epithelium is intact, save where the tubercles are located. The superficial tubercles may directly invade the underlying stroma. This is accomplished by way of the lymph or blood stream. In a case of Frank the lutean cell layer was covered with miliary tubercles. No primary invasion of the follicles has been observed. The usual point of invasion is the connective tissue stroma. Cheesy masses are generally sharply defined from the surrounding stroma and are single or multiple. Tuberculous abscesses of the ovary are usually lined with irregular cheesy walls and granulation tissue beset with miliary tubercles. The surrounding connective tissue contains giant cells and tubercles, and commonly undergoes hyaline degeneration. The tubercles may be found in the purulent contents of the abscess or in the abscess wall. Secondary infection with pyogenic organisms have been demonstrated. Dermoid cysts have been known to contain tubercle bacilli.

Clinical Diagnosis. Since primary tuberculosis of the ovary has not been recognized, it has not been possible to say just what the symptom-complex would be. We find the usual general and local evidences of chronic ovaritis. The tuberculous character is inferred from the family and personal history, and the finding of tuberculous lesions elsewhere in the body, particularly in the tubes and peritoneum.

SYPHILIS OF THE OVARY.

Syphilitic lesions are rarely found in the ovary. Orth reported the finding of a gumma. Richet also describes hyperplastic and atrophic changes in the ovary due to syphilis. Lecorché found in a postmortem case hyperplastic changes in the ovaries with calcareous nodules in the cortex. In this case death was caused by general syphilitic infection. Tuberculosis and syphilis have been observed to coexist in the ovary (Baumgarten).

The diagnosis cannot be determined because of the lack of opportunities for observation. In syphilitic infection with accompanying lesions of the ovary, if the regular antisyphilitic treatment results in a cure of the ovarian lesion, the diagnosis is established.

ACTINOMYCOSIS OF THE OVARY.

This is a very rare condition, and is a secondary invasion from the vagina or intestine. Abscesses, single or multiple, are found in the ovary. They are usually interstitial. There is nothing to characterize their true nature from other abscesses save in finding the organism in the pus. The diagnosis cannot be made without a microscopic examination of the purulent contents.

LEPROSY OF THE OVARY.

Babes found inflammatory lesions in the ovary together with the specific organism which he ascribes to leprosy. The presence of leprosy elsewhere in the body with a chronic ovaritis of no assignable origin affords a probable diagnosis.

NEW FORMATIONS OF THE OVARIES.

Etiology. Ovarian tumors were found in 1.4 per cent. of 36,158 cases in Martin's clinic. The following table from Stander shows the relative *frequency* of various tumors of the ovaries :

Cystadenoma	205	=	69.49 per cent.
Carcinoma	40	=	13.56 "
Embryoma	26	=	8 81 "
Sarcoma	20	=	6.78 "
Fibroma	4	=	1.36 "

Referring to the *age* at which ovarian tumors appear, we find Doran reporting a case of sarcoma of the ovary in infancy, and Homans operating upon a tumor of the ovary at eighty-two years of age. The following is a table prepared by Olshausen in which are given the number of tumors found and the respective ages of the patients :

61 under	10 years.
490 between	20 and 29 "
499 "	30 " 39 "
372 "	40 " 49 "
342 at	50 " over.

It will be seen from the above table that tumors of the ovary occur with about equal frequency between the ages of twenty and fifty years.

The *social state* has no influence upon the development of ovarian tumors ; they occur with about equal frequency in the single and married. They may be the cause of sterility, but it is not likely that sterility predisposes to their development.

While two or more members of the same family have been known to be afflicted with ovarian tumors, it is not believed that *heredity* plays a rôle in the development of these neoplasms. In 1000 cases of Spencer's, 8.2 per cent. were bilateral, while Olshausen gives 13.7 per cent. in 322 cases.

Classification. The old classification of tumors of the ovary into cystic and solid tumors was of the greatest service when the operative treatment was limited to the tapping of fluid. At the present time, when tumors of the ovary are removed *en masse,* such a classification does not meet the requirements.

Tumors of the ovary are classified as *benign* and *malignant.* Waldeyer classifies them according to their histology and histogenesis, into epithelial (parenchymatous) and connective tissue (interstitial) forms. Either of these forms is benign or malignant, and may be cystic or solid. A combination of the parenchymatous and interstitial forms are the so-called mixed tumors.

Epithelial new formations of the ovary take their origin from the germinal epithelium of the follicles, rarely from Müller's duct. From these sources are derived the benign and malignant, the cystic and the papillary tumors.

An adenoma, pure and simple, is rarely seen. More often it is a combination of adenoma and fibroma (adenofibroma). When the gland spaces widen we speak of cystadenoma. These large cystic spaces result from the distention of glands by the retained secretions (non-proliferating cysts), and from proliferation of the epithelial and connective tissue elements in addition to the distention of the glands.

The secretion of these cysts differs. Pfannenstiel introduced the terms *cystadenoma pseudomucosum* when the contents is of a mucous character, and *cystadenoma serosum* when the contents is serous fluid.

The purely glandular type may be found, or papillæ may spring from the surface of the cyst. It is possible to have a papillary cyst on one side and a glandular cyst on the other. One may be intra-

peritoneal, the other extraperitoneal. They are rarely of equal size. Intraperitoneal cysts are pedunculated and are usually freely movable, while extraperitoneal cysts seldom have a pedicle and are fixed. Such extraperitoneal cysts are usually completely enfolded in the broad ligament, but are sometimes partly within the free peritoneal cavity. Cysts of very large dimensions may have but a single cavity, but, as a rule, one or more smaller cysts lie within the parent cyst and are known as daughter cysts. These smaller ones give an irregular surface and a variable consistency to the original cyst. By rupture of the daughter cysts into the parent cyst a multilocular may be converted into a unilocular cyst. There are usually some remnants of the walls of the daughter cysts left in the form of ridges and bands.

As the cyst enlarges the wall becomes thinner, more transparent, and glistening. In the wall of the cyst many bloodvessels are seen to take an irregular course; the veins are larger and more numerous than the arteries.

Villous projections are frequently seen growing from the inner surface of the cyst wall. The villosities vary in size and extent and form wart-like excrescences, sometimes long and slender, like a feather. The framework of the papillæ is of connective tissue in which bloodvessels course. Covering the stroma are one or more layers of columnar epithelium, showing many irregular foldings and reduplications which might be mistaken for malignant proliferation. The connective tissue growth does not keep pace with that of the epithelium. Similar papillary growths appear on the external surface of the cyst. These arise either from the surface epithelium or from within the cyst and subsequently penetrate the wall.

Microscopic examination of the cyst wall shows a vascular framework of connective tissue with more or less round-cell infiltration. In the smaller cysts true ovarian tissue is sometimes present. On the outer surface of the cyst wall germinal epithelium is commonly seen, though it may be partially or wholly lost. The inner surface is lined with a secreting epithelium of cylindrical form and often ciliated. This epithelium remains intact, whatever the size and age of the cyst. To the unaided eye the inner surface appears not unlike the mucous membrane of the stomach.

When nutrition is insufficient certain retrogressive changes follow. Occasionally the cyst contents are absorbed, and the cyst wall contracts, thereby diminishing its size.

Calcareous degeneration of the cyst wall may be partial, or, as in the case of Leopold, complete.

Other secondary changes in the cyst, to be described later, are hemorrhage into the cyst, torsion of the pedicle, rupture of the wall, infection of the contents, and malignant degeneration.

Rupture of a cyst may be followed by closure of the rent and refilling of the cyst, or the rent may remain open and the contents be discharged continuously into the peritoneal cavity. In exceptional cases the cyst shrinks and disappears after rupture.

FIG. 169.

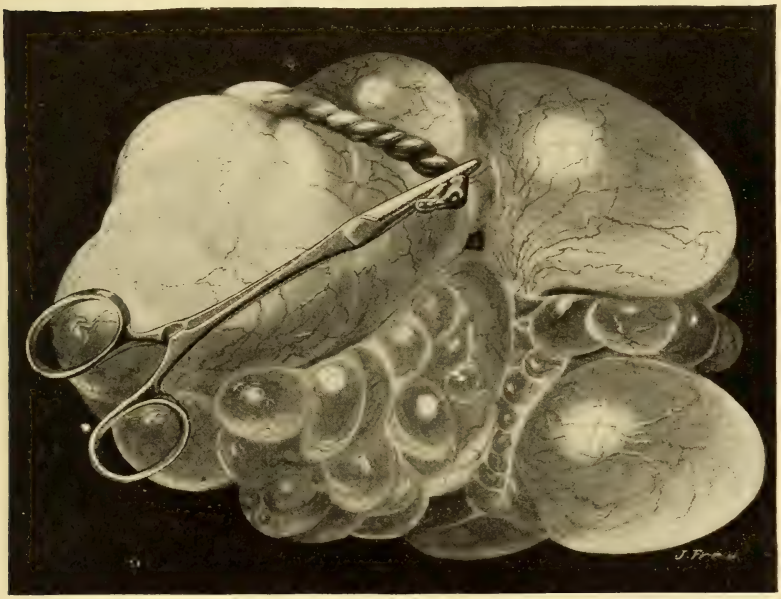

Multilocular ovarian cyst, sometimes called ovarian adenoma, in section; the larger cavity is primary; the smaller cavities, secondary. (DUDLEY.)

If the contents of the cyst are serous the escaped fluid will be absorbed, but if mucus escapes into the peritoneal cavity absorption is slow and a pseudomyxomatous peritonitis may possibly develop. Small hemorrhages into the cyst wall are of common occurrence, and have no clinical significance. Hemorrhagic effusions into the cyst wall predispose to rupture, and life may be endangered by the rupture of large bloodvessels.

When torsion of the pedicle shuts off the blood supply and there are no adhesions through which nourishment is carried to the cyst,

atrophy or gangrene of the cyst will follow. It is possible for adhesions to convey sufficient blood to fully nourish the cyst and even permit it to increase in size.

a. Cystadenoma pseudomucinosum (Hammarstan) contains a mucinous secretion, clear and transparent, or turbid from cell débris and blood. A large amount of blood may give a chocolate color to the fluid. White, flocculent particles float in the fluid. These

Fig. 170.

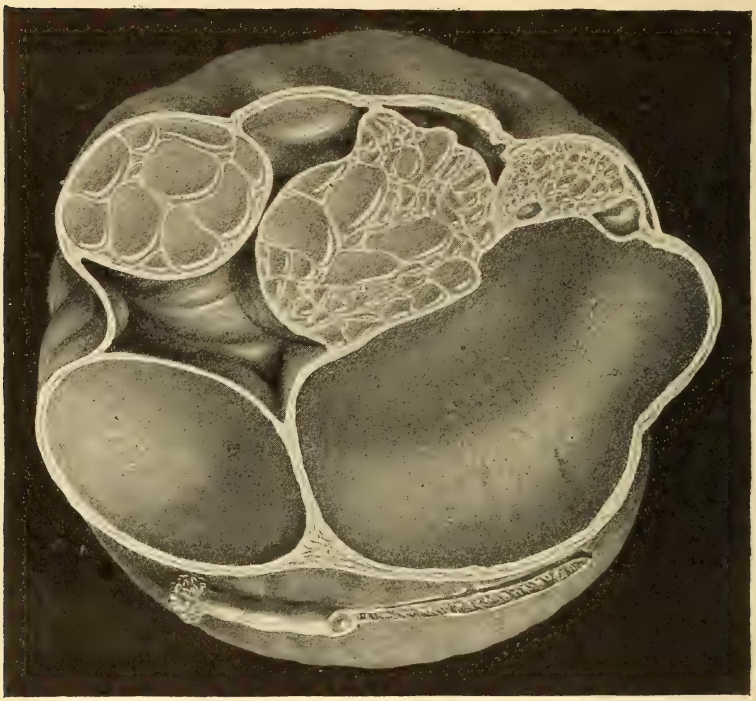

Multilocular ovarian cysts, sometimes called ovarian adenoma. (Dudley.)

consist of mucin, cell débris, cholesterin, blood corpuscles, and fat droplets. The epithelium lining the cyst is a single layer of high, slender, cylindrical cells, with clear, transparent bodies, and oval nuclei near the base.

The pseudomucinous cysts are by far the most common of the large ovarian cysts. They are commonly adenomatous, rarely papillomatous, though a limited number of papillary growths is often found projecting from the cyst wall.

PLATE XL.

Papilloma of the ovary.

FIG. 171.

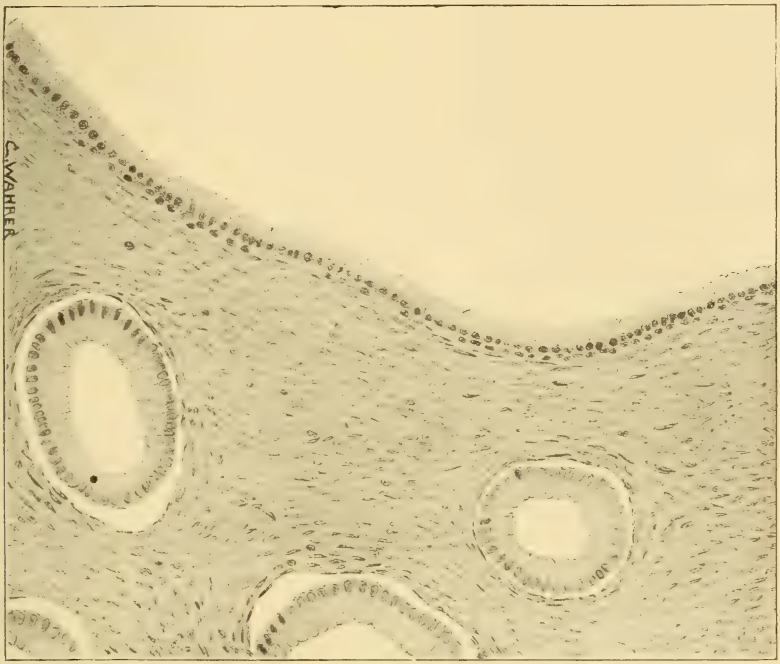

Pseudomucinous ovarian cyst. The cyst is lined within by a single layer of high columnar epithelium with an oval nucleus near the base of the cell. The cyst wall is composed of connective tissue containing gland-like structures.

FIG. 172.

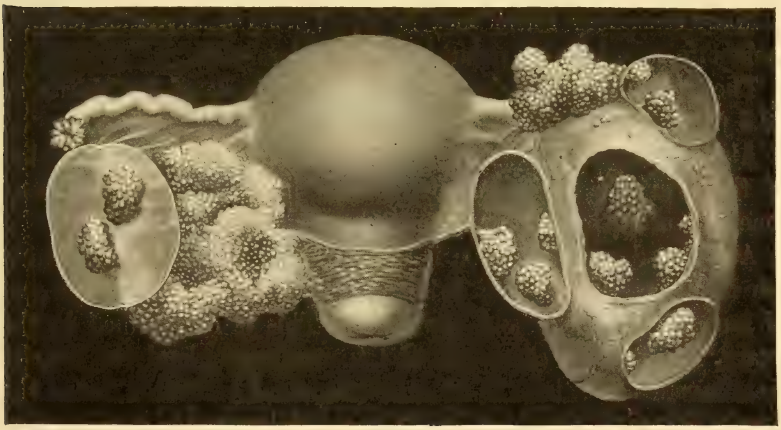

Papillomatous ovarian disease On the right side is a cyst from the paroöphoron or vascular zone of the ovary; in the wall of this cyst have developed three secondary cysts, which are shown in section and which contain warty growths; observe also the warty growths both on the outside and inside of the cyst; to the left is a superficial papilloma of the ovary, which lies between the ovary and the uterus. Papillomatous disease on the inside of this ovary is also shown in section. (DUDLEY.)

According to Martin, more than two-thirds are unilateral; only about 7 per cent. are extraperitoneal. The largest recorded cyst weighed 245 pounds.

b. Cystadenoma serosum contains a clear serous fluid of a pale green color; it is rarely turbid from admixture with cell débris, or chocolate color from admixture with blood.

These cysts rarely attain the enormous size of the mucinous variety. They are frequently papillary, and as such are often bilateral.

Papillary growths may not only cover the inner surface of the cyst and penetrate to the outer, but may spread by continuity of tissue to the peritoneum, where by mechanical irritation ascitic fluid is secreted.

A papillomatous growth of the ovary without cystic formation is an unusual condition. The secreting epithelium consists of low, cylindrical-shaped cells, with round nuclei near the centres.

CARCINOMA OF THE OVARY.

Our knowledge of primary carcinoma of the ovary is very limited. The majority of carcinomata are secondary.

Classification. Waldeyer gives the following classification:

1. Simple (carcinoma simplex).
2. Medullary (carcinoma medullaris).
3. Scirrhus (carcinoma schirrosum).

Many secondary forms may be added, such as atrophic, colloid, melanotic, sarcomatous, gelatinous, and microcystic.

The frequency of carcinoma of the ovary is stated by Martin as 13.6 per cent. of his cases of ovarian tumors.

About three-fourths of them are unilateral. Bilateral invasion of the ovary is always associated with involvement of the peritoneum and other structures, and hence is inoperable.

As pointed out by Sutton, it is a curious rule that organs which are frequently the seat of primary carcinoma are rarely the seat of secondary deposits, and *vice versa*. This is exemplified in the ovary. In primary carcinoma of the mammary gland the ovaries were invaded five times in 85 cases (Coupland.) Sutton found the ovaries invaded six times in 52 cases of inoperable carcinoma of the uterus, and three times in 29 cases of inoperable carcinoma of the breasts.

PLATE XLI.

Cystic carcinoma of the ovary, with extension to the intestinal and parietal peritoneum and to the omentum. (Dudley.)

Olshausen says an important feature in the clinical history of ovarian cancer is the fact that it often occurs at an early age and may even develop during childhood. The following table was constructed by Olshausen :

8 to 19 years	10 patients.
20 " 29 "	17 "
30 " 39 "	8 "
40 " 49 "	15 "
50 years and above	17 "

Anatomical Diagnosis. In solid carcinomatous tumors of the ovary the general form of the ovary is maintained. The surface is uneven and studded with tubercles, nodules, or papillary growths. Rarely is the surface smooth. It is unusual to find normal ovarian tissue, yet the occurrence of pregnancy in bilateral involvement of the ovaries shows that some follicles remain healthy. In the large tumors cystic spaces are invariably present. Malignant degeneration of ovarian cysts is of more common occurrence. In all forms of carcinoma of the ovary the carcinoma cells maintain their cylindrical shape and form cancer nests or gland-like structures not dissimilar to those found in carcinoma of the Fallopian tube.

Papillary growths which have perforated a cyst wall are prone to undergo malignant degeneration and to rapidly spread to the peritoneum. As pointed out by Abel, where cancerous degeneration is suspected, the cyst should not be tapped before removal for fear of contaminating the peritoneum and setting up metastatic growths.

Squamous-cell carcinoma of the ovary has been observed in dermoid cysts.

Metastasis does not occur so widely in carcinoma of the ovary as in carcinoma of the uterus. The most likely points of invasion are the peritoneum, omentum, and retroperitoneal glands.

DERMOID CYSTS OF THE OVARY.

Dermoid cysts, as the name suggests, are cystic tumors containing skin structures.

In Martin's classification we find simple dermoid cysts, complicated dermoid cysts, teratoma, and solid teratoma.

A simple dermoid cyst is a sac lined with a dermal membrane. A complicated dermoid cyst is lined with skin and contains heterogeneous structures, such as glands, bone, and teeth. A teratoma contains formed organs, such as brain, mammary glands, thyroid

glands, etc. A solid teratoma contains no large cysts and is composed of structures similar to those found in ordinary teratoma.

From Bandler we quote: "The pronephros, the Wolffian body, and the Wolffian duct, through their position in the mesoderm, their connection between ectoderm and cœlome, their relation to the normal development of the ovary, their subsequent position at the hilus of the ovary and the extension of the tubules into the vascular layer and their growth through the ovary even up to the surface, and from the fact that their remnants furnish the ciliated growths of the broad ligament and form the cystadenomata of the ovary, are capable of carrying with them mesodermal and ectodermal cells up to or into the ovary, and of forming mesodermal and ectodermal products and structures lined with ciliated epithelium. . . . . Cysts of the testicles lined with ciliated epithelium originate from remnants of the Wolffian body tubules. Therefore, the mesodermal tumors, the mixed tumors, and the dermata of the ovary and testicles originate in this same manner. . . . . If ectodermal cells are displaced to any extent so that their presence is manifested by cutis-like tissue, hair, sebaceous glands, etc., we speak of dermoid cysts. If the displaced cells are, so to speak, located in one part of the organ concerned, and if they grow equally, and if the skin cells, as in the normal skin and the sebaceous glands, excrete their products, a cystic dermoid must result. Since the contents found in dermoid cysts are excreted by the so-called 'derm' of the cyst, they must lie, when secreted, between the derm and the enveloping tissue composing the organ or tissue in which the dermoids grow. The larger the amount of this secretion the greater is the pressure on the secondary tissue. If the mass of the secreted matter reaches a fair amount, and if it causes a tissue growth in its periphery, and if it compresses the overlapping organ so that it is stretched or flattened, we then have a cystic dermoid whose wall consists of so-called 'skin,' of granulation tissue, and of the tissue of the enveloping organ. The original group of displaced cells is found then as a prominence only in one part of the so-called cyst wall, and it is this part which grows gradually for years, and in which are found the hair, the sebaceous glands, and other elements found in the inner surface of a dermoid cyst. The greater the amount of substance secreted, and the greater the amount and number of the products found by the displaced ectodermal and mesodermal cells, the larger the cyst.

"If, on the other hand, the displaced cells are not grouped in one part of the organ concerned, and if, at the same time, the ectodermal cells are not present in too great number, there develops a tumor in which the various tissue forms grow into each other. Since these ectodermal cells do not form in such a case a so-called 'derm,' and since they cannot bring about the formation of a cyst through their excretion as above described, a tumor form results which is relatively solid and which seems to be of an entirely different structure—a so-called 'teratoma.'

FIG. 173.

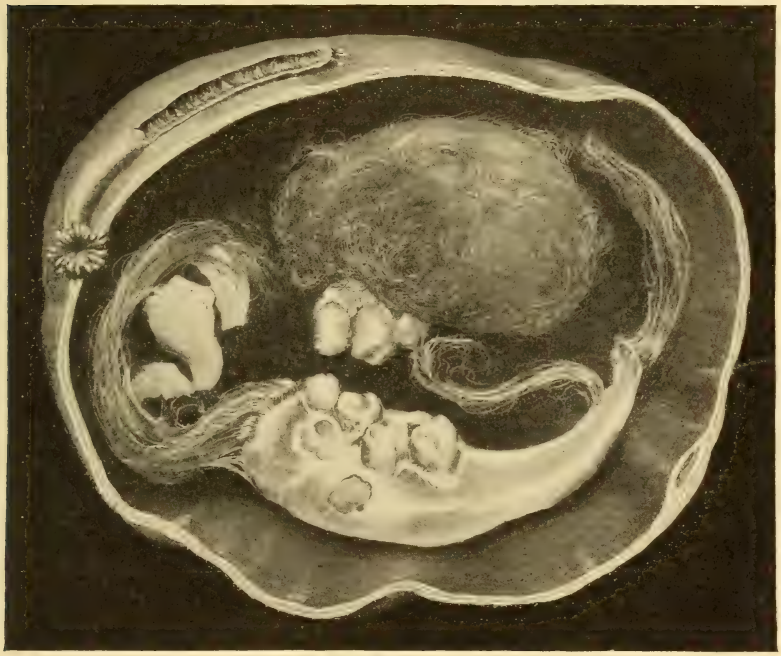

Dermoid ovarian cyst in section, showing inside of cyst cavity, which contains a lower jaw and a fragment of another jaw, with teeth, small fragments of bone, and considerable hair; the upper mass of hair is in the shape of a ball, and is held together by the fatty contents of the cyst, which, at the temperature of the body, is liquid, but becomes solid upon exposure to the ordinary temperature of the air—that is, about 70° F. (DUDLEY.)

"In ovarian dermoids and teratomata ectoderm is present in large amount; therefore, teeth are frequently found, and their occurrence is in contrast with their rarity in the testicle. The origin of teeth is to be explained by the united presence of ectoderm and mesoderm in these tumors."

Anatomical Diagnosis. A dermoid cyst may occupy part or all of the ovary, and as many as five distinct and separate dermoids have been found in the same ovary. They are commonly intraperitoneal and are rarely found between the layers of the broad ligament. Both skin and mucous membrane are found in the cysts. The amount of skin found varies greatly. It may completely line a large cyst or may be confined to a single daughter cyst.

FIG. 174.

A composite drawing of the microscopic appearance of a dermoid. *a*, an epithelial pearl in section; *b*, glandular tissue; *c*, developing hairs; *d*, developing teeth; *e*, sweat gland in section.

Cutaneous appendages found in the skin of the dermoid are hair, teeth, nails, horns, sebaceous and sudoriferous glands, mammæ, bone, unstriped muscle fibre, brain and nerve tissue.

The hair may be rolled into a ball and lie free in the cyst cavity, or tufts of hair may spring from the cyst wall. The hair has been

known (Mundé) to be five feet in length. The color varies from blond to black, and does not usually correspond to the color of the patient's hair. It is known to turn gray in old age, and at this time the cyst may become bald.

The teeth may be embedded in bone resembling a rudimentary jaw or in the fibrous wall of the cyst. More than 400 teeth have been found in a single dermoid cyst of the ovary. They represent teeth of every description and develop on the same plan as teeth in the normal situation. They are not scattered irregularly through the cyst unless present in large numbers, but are grouped together.

Nails and horns project from the surface of the cyst. Sebaceous and sweat glands may be numerous, and may form retention cysts. Bone in shapeless masses or in plates is occasionally found. Nerve matter has been detected in dermoid cysts.

Mammæ, in the form of a nipple attached to rounded projections of tissue containing sebaceous glands and more or less fat, are occasionally found, and completely formed glandular structures have been discovered. Dr. Desiderius reported a case in which the gland secreted milk and colostrum.

Dermoid cysts of the ovary occur at any period of life, from birth to eighty years of age, and are to be regarded as the most common abdominal tumor in girls and young women. The rate of growth varies from a few months to many years in attaining the maximum size. They are rarely larger than the patient's head, and may be self-limiting in their growth. As a rule, adhesions bind the cyst to the intestine. Suppuration and malignant degeneration are the peculiar characteristics of dermoid cysts of the ovary.

CONNECTIVE TISSUE NEW FORMATIONS OF THE OVARY.

Fibroma, myoma, myxoma, enchondroma, osteoma, angioma, lymphangioma.

Fibroma of the Ovary.

Of the connective tissue tumors of the ovary, fibroma is the most frequent. They are found with about equal frequency between the ages of twenty and fifty, and have been met with as early as ten or as late as eighty years of age.

Orthmann classifies fibroids of the ovary as superficial and diffuse.

a. **Superficial fibroids** are commonly small, rarely larger than a walnut. They are single or multiple, and sessile or pedunculated in their attachment to the tunica albuginea. Their consistency is firm, and the external surface is smooth or furrowed. On cross-section whorls and bands of fibres are seen. Germinal epithelium covers the surface of the tumor.

b. **Diffuse fibroids** have rarely grown larger than a man's head. Clemens reported one weighing 40 kilos. The contour varies from round and smooth to irregular and nodular. The amount of blood supply is variable, and hence the color of the tumor varies from a pale gray to a yellowish-red. Unless there are degenerative changes their consistency is uniformly firm.

Adenofibroma of the ovary is an occasional finding and consists of glandular tissue in a fibrous framework.

Myoma of the Ovary.

The origin of myoma of the ovary is probably the muscle fibres of the vessel walls and the ovarian ligament. They are rare. None larger than a man's fist has been reported. In general appearance they closely resemble fibroids.

Myxoma ovarii appears as a degenerative form of an ovarian tumor, not as a primary growth.

Enchondroma and **osteoma** are secondary changes in pre-existing ovarian tumors.

Angioma and **lymphangioma** are extremely rare. A congenital angioma is described by Orth.

SARCOMA OF THE OVARY.

In 66,190 malignant tumors of the ovary 96 were sarcomata. They are found at any period of life, from birth to old age. The periods of puberty and the menopause are the most frequent (Zangemeister). Doran found a sarcoma of the ovary in a seven months' fœtus ; Heinrichs reported one in a woman aged seventy-four years. According to Temesvary, the average age of the patient is thirty-two years. Pfannenstiel finds sarcoma of the ovary most frequent between the ages of twenty-one and thirty. In 25 cases Pick finds 10 occurring before twenty years of age.

Sutton says sarcoma of the ovary differs from sarcoma found elsewhere in that both ovaries are often simultaneously affected. In

121 cases in the literature, I find 42, or about one-third of the number, in which both ovaries were involved.

Many so-called fibroids of the ovary are undoubtedly sarcomata. Russel and Shenck described a sarcoma springing from the theca interna. In form they may resemble a large ovary or are very irregular and nodular. Their consistency varies from firm to soft and the color from pale gray to reddish-white. The rate of growth is variable, the softer tumors growing more rapidly. Chrobak saw a sarcoma of the ovary grow to the size of a five months' pregnancy in a few months. The entire ovary is usually involved, and both ovaries in about one-half of the cases.

Both round and spindle sarcoma cells compose the tumor. About one-third are cystic. Sarcomatous degeneration of dermoid cysts is described. Metastasis occurs later in sarcoma than in carcinoma of the ovary. Metastatic growths are found in order of frequency in the peritoneum, omentum, wall of the stomach, pleura, lungs, uterus, liver, diaphragm, retrovaginal connective tissue, mediastinum, tubes, intestine, and kidney (Temesvary).

A myxomatous degeneration of sarcomatous tissue is occasionally observed.

ENDOTHELIOMA OF THE OVARY.

Marchand and Leopold first observed malignant new formations of the ovary arising from the endothelium of bloodvessels. They are also known to arise from the lymph vessels. Few have been recognized, but doubtless many pass for carcinoma and sarcoma.

PAROVARIAN CYSTS.

The parovarium consists of a series of tubules lying between the layers of the mesosalpinx. When the mesosalpinx is stretched and held between the eye and the light the tubules are seen as narrow cords running in parallel lines from the hilum of the ovary to a longitudinal tubule lying parallel to the tube and immediately beneath it (Gärtner's duct). The tubules are lined with ciliated epithelium. The parovarium is homologous with the vasa afferentia and epididymis of the testis. It is composed of the persistent excretory ducts of the Wolffian body.

As a rule, there are twelve tubules. The tubule running parallel to the Fallopian tube and at right angles to the parovarian tubules

is the duct of Gärtner, which in exceptional cases may be traced to the vagina.

Cysts arising from the parovarium, the so-called parovarian cysts, are of common occurrence. As the cyst develops the layers of the mesosalpinx are unfolded, the tube is crowded upward and runs over the cyst, and the ovary is crowded downward. The Fallopian tube is greatly elongated in large cysts, but the lumen is seldom obliterated. The wall of the cyst is at first thin and transparent, later thick and non-transparent. The epithelium lining the cyst is columnar and usually ciliated in the small cysts, while later the

FIG. 175.

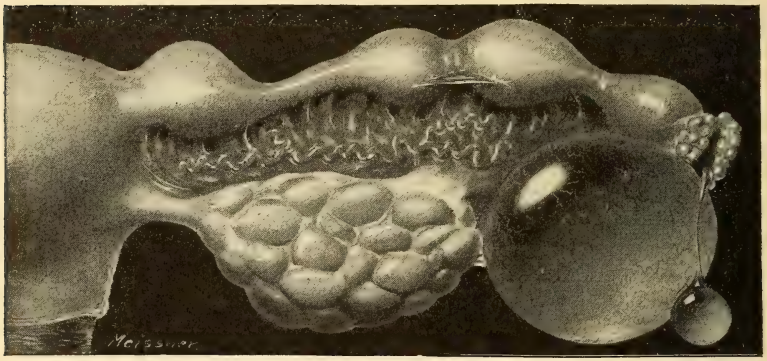

Small parovarian cyst. This cyst has sprung from the parovarium, and is therefore entirely distinct from the ovary; to the right is the hydatid of Morgagni suspended from a long, slender pedicle, which is attached to one of the fimbriated extremities of the Fallopian tube. The hydatid of Morgagni has been known to grow to the size of a small orange, and it then has the same general appearance as the parovarian cyst, but is distinguished from it by the fact that it springs from the extremity of the Fallopian tube. The Fallopian tube shows numerous points of expansion and constriction, one of them being at the isthmus; this is known as the salpingitis isthmica nodosa, common in gonorrhœal salpingitis. Myoma and adenomyoma of the tube present much the same gross appearance. This condition of the tube is rarely found in connection with cysts of the parovarium. (DUDLEY.)

epithelium is stratified and flat. In the very large cysts the epithelium may wholly disappear through pressure. The fluid contents is clear and watery, the reaction is slightly alkaline, and the specific gravity 1002 to 1010.

No parovarian cyst has been recorded in an individual under sixteen years of age (Sutton). They are supposed to form about 10 per cent. of ovarian tumors. Parovarian tumors are rarely adherent; they seldom suppurate, and are less liable to axial rotation than are ovarian cysts, because they are usually fixed and seldom have a pedicle.

The Clinical Diagnosis of New Formations of the Ovary. In the diagnosis of ovarian tumors it is of the greatest importance to recognize a pedicle connecting the tumor to the horn of the uterus. The pedicle is composed of the Fallopian tube, broad

FIG. 176.

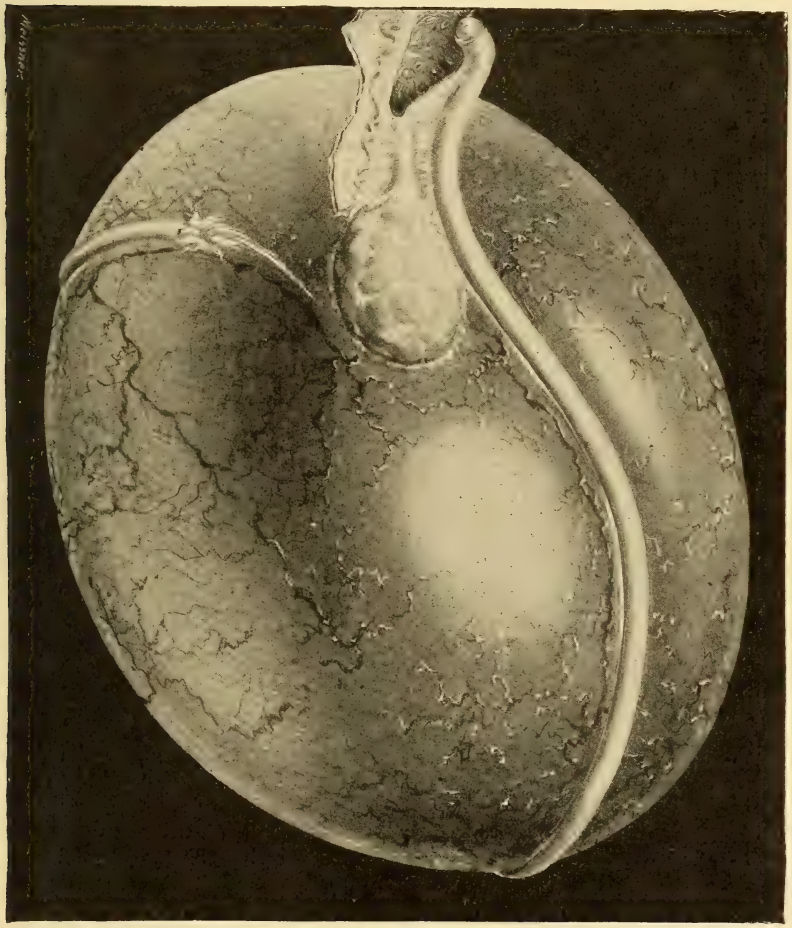

Parovarian cyst. Observe the ovary separate from the cyst and the long, stretched-out Fallopian tube which surrounds the cyst wall. (DUDLEY.)

ligament, and ovarian ligament. A short, thick pedicle holds the tumor close to the uterus, while a long, slender pedicle permits considerable separation. The length and thickness of the pedicle are not proportionate to the size of the tumor. When, as occasion-

ally happens, the tumor grows in the direction of the mesovarian and broad ligament, it becomes intraligamentous. An ovarian tumor may be partly within the broad ligament and partly within the free peritoneal cavity. Having grown between the layers of the broad ligament, the tumor may burrow to the left behind the sigmoid flexure, to the right behind the cæcum, into the parametric tissue behind the uterus, or between the bladder and abdominal wall underneath the peritoneum.

In discussing the diagnosis of ovarian tumors, we will adopt the classification of Winter, devised by him for convenience of description. It is as follows :

1. Small ovarian tumors, which lie wholly or in part within the pelvis.

2. Medium-sized ovarian tumors, which have grown into the abdominal cavity, which have not grown beyond the size of a man's head, and have not risen to the arch of the ribs.

3. Large ovarian tumors, which rise to the arch of the ribs and are in intimate relation to the liver, kidney, and spleen.

The Diagnosis of Small Ovarian Tumors which Lie Wholly or in Part within the Pelvis. The tumor may be closely crowded to the uterus—so close that no pedicle is detected. It is always possible in a vaginal examination to insert the finger between the supravaginal portion of the cervix and the tumor. When the tumor lies behind the uterus it is especially difficult to separately outline the two. Ovarian cysts are round, the surface is usually smooth, and fluctuation is well-marked. They are not tender to pressure unless complicated by adhesions or other inflammatory lesions.

Solid tumors are usually more uneven in outline and have a firm consistency. Cystic tumors with thick walls and surrounded by an inflammatory exudate may give the impression of solid tumor growths. The uterus may be crowded to the opposite side.

Differential Diagnosis. To diagnose small tumors of the ovary from cystic degeneration, chronic ovaritis, hæmatoma, and abscess, it is necessary to consider the history of the onset and the clinical course. Sensitiveness to pressure speaks for inflammatory enlargements, as does fixation. Inflammatory enlargements of the ovary do not show steady growth as do new formations, and, furthermore, they are more likely to be bilateral. In inflammatory swellings of the ovary the accompanying tube is often diseased, and evidences of pelvic peritonitis are frequently to be found. The effect of local

applications is reduction of the size of inflammatory swellings of the ovary, while such treatments have no effect upon new-growths.

Cystic degeneration of the ovary is very constantly associated with chronic ovaritis, and is to be distinguished from new formations of the ovary by its small size and tendency to be self-limited in growth. Such ovaries are rarely larger than a hen's egg.

Uterine Fibroids. It is easy to mistake pedunculated subperitoneal fibroids of the uterus for tumors of the ovary.

Uterine Fibroids.	Ovarian Cysts.
1. Rarely occur early in life.	1. May occur in infancy.
2. Rarely grow after the menopause.	2. Often continue to grow after the menopause.
3. Rate of growth is slow.	3. Rate of growth is usually more rapid.
4. Consistency usually firm.	4. Fluctuating.
5. Intimately attached to the uterus.	5. Less intimately associated with the uterus.
6. Tumor may be attached to any portion of the uterus.	6. Tumor connected with the uterine horn.
7. Pedicle usually short and thick.	7. Pedicle may be long and slender.
8. Uterus usually increased in length.	8. No increase in the length of the uterus.
9. May find both ovaries normal.	9. One or both ovaries abnormal.
10. Venous murmur heard in 50 per cent. of large fibroids.	10. Venous murmur seldom heard.
11. Menorrhagia common.	11. Not common.
12 Functions of the bladder and rectum often disturbed.	12. Not often disturbed.

It must be remembered that uterine fibroids may appear to fluctuate similarly to a cyst with gelatinous fluid. When doubt exists after all of the above points are considered, an exploratory incision should be made.

Tubal Pregnancy. See respective chapter.

Serous perimetric exudates may become sharply circumscribed, slightly or not at all tender to pressure, and may fluctuate from contained fluid. In the early stage the exudate may collect in the pouch of Douglas, and from its form and consistency it may be mistaken for an ovarian tumor. Such exudates are rounded below and flat above, while ovarian cysts are round throughout their entire circumference. The consistency may show variations at different points, while in ovarian cysts it is usually uniform throughout. The exudate blends with the surrounding structures, and is inseparably connected with the uterus.

The history of infection, the rapid development of the mass, and the tendency to remain stationary, or to decrease in size, are important factors in the differential diagnosis of perimetric exudates from ovarian cysts.

Parametric exudates can usually be differentiated from ovarian cysts by the history of infection. This will point to an inflammatory origin. The location of the mass in the connective tissue in close proximity to the vaginal wall is characteristic of pelvic cellulitis. Ovarian tumors lie on a higher level. The consistency of an inflammatory exudate changes from time to time, becoming firmer and irregular, while the consistency of ovarian cysts is constant. It is often possible to palpate both ovaries apart from the pelvic exudate.

The intimate connection with the uterus, the ill-defined outline, the immobility and tenderness to pressure, the history of infection, and the sudden development of the mass, together with its tendency to become smaller as time goes on, are significant points in favor of the diagnosis of a pelvic exudate.

Pericæcal Abscess. A suppurating cyst of the ovary may be confused with an abscess about the cæcum. A history of one or more attacks of appendicitis and existing intestinal disorders will be suggestive. The abscess is largely confined to the right iliac region, and extends downward to the uterus rather than upward from the uterus.

Retro-uterine hæmatocele occupies the pouch of Douglas, and may be so moulded as to suggest an ovarian tumor. A hæmatocele is less tense and elastic, and does not fluctuate. There is no attachment by a pedicle to the horn of the uterus, and it may be possible to palpate both ovaries apart from the mass. A history of ruptured tubal pregnancy is often elicited. An exploratory puncture or incision will disclose the blood.

Intraligamentous hæmatoma in its early development occupies a position altogether impossible for an ovarian tumor, and, later, as it dissects around the uterus, it cannot be confounded with an ovarian tumor. The low situation of the mass, its ill-defined outline, the absence of fluctuation, its tendency to become smaller instead of progressively enlarging, and, finally, an exploratory puncture or incision will determine the diagnosis. There is usually a history of ectopic pregnancy with rupture of the gestation sac.

A retroflexed pregnant uterus has been mistaken for an ovarian cyst. The usual signs of pregnancy are to be considered. In ovarian cysts it is possible to have amenorrhœa, enlargement of the mammæ, secretion of colostrum, discoloration of the cervix and vagina, and nausea. These signs, together with a rapidly growing abdominal tumor, might suggest pregnancy.

The rate of growth of a pregnant uterus is more rapid than that of an ovarian cyst. Its consistency is soft and elastic, as contrasted with the tense elasticity of an ovarian cyst. So long as there is a suspicion of pregnancy the sound should not be employed. When in doubt as to the diagnosis, and immediate interference is not demanded, it is well to keep the patient under observation for several weeks to note the progress of the tumor and the development of positive signs of pregnancy.

THE DIAGNOSIS OF OVARIAN TUMORS OF MEDIUM SIZE.

A tumor lying at the brim of the pelvis that is round or oval, sharply outlined and fluctuating, is in all probability an ovarian cyst. If it can be demonstrated that the tumor is attached to the horn of the uterus by a pedicle, the diagnosis is confirmed. It is most essential to recognize the pedicle, and this is usually possible where the conditions for examination are favorable. Where the pedicle is difficult to palpate, Hegar advises traction on the cervix by a tenaculum while a recto-abdominal examination is carried out.

Winter further advises traction on the tumor by an assistant, as shown in Fig. 10. In this manner the pedicle is made taut and can be more readily recognized. Where the pedicle cannot be palpated, the diagnosis must rest upon the consistency and general outline of the uterus.

Pregnancy in the second and third trimester can only be confounded with an ovarian tumor when there is no evidence of the presence of a fœtus. There will be still greater uncertainty in the diagnosis when it is not possible to demonstrate the direct continuity of cervix and body because of the high position of the uterus.

The uterine souffle is seldom heard in ovarian cysts and will speak for a pregnant uterus or a solid tumor. The finding of the round ligaments running to the tumor will establish the diagnosis.

Advanced Ectopic Pregnancy. The history of pregnancy, together with the finding of an abdominal tumor of unequal soft consistency and absence of fluctuation, will suffice for the exclusion of an ovarian cyst. Where the fœtus is living it is scarcely possible to mistake the tumor for an ovarian cyst. With the death of the fœtus all signs of pregnancy may disappear. The uterus, in an ovarian cyst, is normal in size, while in advanced ectopic pregnancy it fairly resembles a pregnant uterus at the third month.

A distended bladder may resemble an ovarian cyst in general outline, position, and consistency. In every pelvic examination for whatever lesion, it is always advisable to make sure that the bladder is empty. If this rule is observed there will be no question as to the differential diagnosis of an ovarian cyst from a greatly distended bladder. When such a question arises the catheter will obviate all possible error.

Tumors of the omentum rarely simulate ovarian tumors. They are seldom so sharply circumscribed and rounded, and are not connected to the uterus by a pedicle. The finding of the ovaries apart from the tumor will exclude the possibility of an ovarian tumor. Omental cysts have been tapped for ovarian cysts.

Echinococcus cysts of the pelvis form a rounded cystic tumor that closely resembles an ovarian cyst. The presence of a tumor of the liver speaks in favor of echinococci, but an absolute diagnosis is only made by an exploratory puncture and the finding of the hooklets.

Parovarian cysts have thin walls and are less tense than ovarian cysts. Unless the ovary can be palpated distinct from the cyst a diagnosis cannot be made with certainty.

Phantom tumors of the abdominal wall, caused by muscular contraction, may simulate an ovarian cyst in form and consistency. The swelling has no connection with the uterus and will disappear under anæsthesia.

THE DIAGNOSIS OF LARGE OVARIAN TUMORS FILLING THE ABDOMINAL CAVITY.

It is often quite impossible to palpate the pedicle because of the close proximity of the large tumor to the uterus. When it is demonstrated that the swelling is a cystic tumor and not free fluid, the diagnosis of an ovarian cyst is highly presumptive, because it is most unusual for a cystic tumor of such size to grow from any other source than the ovary. The superficial veins of the abdominal wall are distended, and markings resembling striæ gravidarum are usually seen over the abdomen. The percussion note is dull over the swelling, and tympanitic in the flanks, and over the stomach where the intestine and stomach have been crowded by the tumor. Changing the position of the patient does not alter the outline of the area of dulness as it does in free ascites.

Fluctuation is easily demonstrated. Because of the great distention of the abdomen it is difficult to outline the uterus. When pregnancy can be excluded the uterine sound will determine the position of the uterus. In cysts of extreme size the upper border lies beneath the sternum and ribs, bulging them forward; the tympanitic note of the transverse colon and stomach is lost. The splenic dulness is lost, the liver dulness cannot be defined from that of the tumor, and the heart and lungs are pressed upward. The abdomen is symmetrically enlarged, hence measurements are of no value in the largest cysts. Those of smaller size present an asymmetrical enlargement which can be demonstrated by inspection and by certain measurements. These measurements are taken from the umbilicus to the anterior superior spine of the ilium, and from the linea alba to the spine of the vertebræ. A comparison of the measurements of the two sides will afford reliable information. Auscultation is of little service. A bruit is sometimes heard, and will serve to differentiate the cyst from ascites.

Differential Diagnosis. **Free ascites** is very often mistaken for large ovarian cysts. Cases occur where a diagnosis cannot be made until the abdomen is opened. Still greater difficulty arises when an ovarian cyst is associated with ascites. Much can be ascertained from inspection of the distended abdomen.

Ascites.	Large Ovarian Cyst.
1. Diseases of the heart, lungs, liver, and peritoneum to account for the presence of the fluid.	1. Absent.
2. Rapid development.	2. Development usually slow.
3. Inspection of abdomen.	3. Inspection of abdomen.
a. Enlargement symmetrical.	*a.* Enlargement asymmetrical unless the entire abdomen is filled.
b. Flattening anteriorly and bulging in the flanks with patient on her back.	*b.* Round anteriorly and flat in the flanks with patient on her back.
c. Lower portion of abdomen bulges and epigastrium is flattened with patient erect.	*c.* No change in the outline of the tumor by change of position of the patient.
d. Navel prominent and thin.	*d.* Navel not prominent.
e. Costal arch does not bulge.	*e.* Costal arch bulges.
4. Percussion of abdomen.	4. Percussion of abdomen.
a. Dulness in flanks.	*a.* Dulness over abdominal prominence.
b. Tympany in median line.	*b.* Tympany in flanks and epigastrium.
c. Change of area of dulness by change of position of patient.	*c.* No such change.
5. Palpation of abdomen.	5. Palpation of abdomen.
a. No outline of tumor can be palpated.	*a.* Outline palpated.
b. Fluctuation in all vaginal fornices.	*b.* More limited.
6. Exploratory puncture. Contain serous fluid.	6. Exploratory puncture. Contains serum or mucus.
7. Hydragogues and diuretics temporarily improve the condition.	7. Have no effect.

Fig. 177.

Free fluid in the abdominal cavity. The dark lines show the area of dulness on percussion with the patient lying on her back.

FIG. 178.

Large ovarian cyst. The dark lines show the area of dulness on percussion in any position the patient may assume.

The percussion note is of greatest value in differentiating free from encysted fluid. The area of dulness increases as the fluid collects, and is last to disappear in the epigastrium. In ascites of extreme grade there may be no area of tympany, and the same may be true of very large ovarian cysts. If the mesentery is short, the tympanitic note disappears early ; if long, so as to permit the bowels to float on the surface of the ascitic fluid, or to be crowded in advance of the cyst, the tympany can be demonstrated until the abdomen is overdistended.

Certain fallacies must be guarded against. A very short mesentery or the presence of adhesions may confine the intestine to the flanks in free ascites and give a tympanitic note in this region. In ovarian cyst the bowel may be adherent to the anterior abdominal wall and give a tympanitic note in the median line. Gas generated within the cyst may give a tympanitic note. Again, the absence of gas within the bowel may give a dull note where tympany would otherwise be found.

In an ovarian cyst the percussion note is always dull over the tumor, whether the percussion is superficial or deep, while in ascites superficial percussion may be tympanitic and deep percussion dull.

It is especially difficult to differentiate between ascites and a thin-walled cyst, such as a large parovarian cyst. In the latter the fluid may gravitate to the dependent portions of the abdomen, and it may not be possible to outline the tumor by palpation. An exploratory incision may alone clear up the diagnosis.

As an aid to the differential diagnosis of ascites and ovarian cysts, Landau advises putting the patient in the lithotomy position and elevating the hips. If there is a large quantity of free fluid in the abdominal cavity, the uterus, in an abdomino-vaginal manipulation, may be demonstrated to lie upon a water cushion.

Pancreatic Cysts. No confusion should arise in the early development of pancreatic cysts. They take their origin in the region of the pancreas and grow from above downward. The most prominent portion of the tumor is located in the region of the navel.

It is possible for a small or moderate-sized ovarian cyst with a long pedicle to occupy a similar position. Such a cyst is usually more movable than a pancreatic cyst, and the demonstration of its attachment to the uterus by a pedicle will determine the diagnosis.

In doubtful cases an exploratory puncture, together with a chem-

ical analysis of the aspirated fluid, will identify a pancreatic cyst. The danger of perforating the stomach is to be borne in mind.

Splenic Tumor. It is possible for a tumor of the spleen to extend to the inlet of the pelvis, and when cystic (echinococcus) an ovarian cyst may be diagnosed. Most splenic tumors are solid, and these are not likely to be mistaken for ovarian tumors. A splenic tumor grows from above downward, while an ovarian tumor grows from below upward. The finding of a pedicle connecting the tumor with the horn of the uterus identifies it as ovarian in origin. An analysis of the blood will often disclose the nature of a splenic tumor (splenic leukæmia, malaria). The notched border and the respiratory movements of the spleen are significant. A number of cases has been reported in which a spleen of about normal size has occupied the pelvis and has been mistaken for solid tumors of the ovary. It is important in all such cases to seek for a pedicle connecting the tumor with the horn of the uterus. As a last resort an exploratory incision may be made.

Tumors of the Liver. It is possible for tumors of the liver to reach to the inlet of the pelvis. An ovarian tumor, because of its great size or long pedicle, may reach to the right costal arch and the tumor and liver become one inseparable mass.

A uniform enlargement of the liver should be recognized by its sharp lower border and by the characteristic fissure separating the right from the left lobe. The mass should move with respiration, a fact not observed in ovarian tumors. An irregular enlargement of the liver, as from echinococcus cysts, abscess, and new formations, is more likely to be mistaken for an ovarian tumor than is a uniform enlargement. Here, as at all times, it is essential to determine the relation of the tumor to the uterus, whether or not there exists a pedicle. In pedunculated tumors of the liver the greatest mobility is at the lower portion of the growth, while in freely movable ovarian tumors the greatest mobility is at the upper portion of the tumor.

Fatty Tumors. Enormous fatty tumors may spring from the omentum and subserous tissue, and suggest the possible presence of ovarian tumors.

A distended gall-bladder containing eleven pints of fluid was operated upon by Lawson Tait, who mistook it for an ovarian cyst.

A chylous cyst of the mesentery may attain an enormous size, and closely simulate an ovarian cyst.

Obesity. A very thick abdominal wall may suggest the presence of an ovarian tumor. It may be impossible to say that an ovarian cyst does not exist without making an exploratory incision.

Allantoic or **urachus cysts** may give rise to suspicion of an ovarian cyst. They may attain a large size, and are always found in the median line between the abdominal wall and peritoneum.

Hydronephrosis has been mistaken for ovarian cysts. A hydronephrosis may occupy the pelvis and an ovarian tumor may occupy the region of the kidney. Moreover, a hydronephrosis and an ovarian tumor may coexist.

The characteristic physical signs of renal tumors can usually be relied upon. The colon lying in front of the kidney gives a tympanitic note on light percussion. In exceptional cases the bowel may lie in front of an ovarian cyst. In hydronephrosis the tumor may intermit, and such diminution in size is accompanied by an abundant flow of urine. Examination of the urine may disclose important facts. It is possible for an ovarian cyst to rupture, and this in turn be followed by diuresis.

The ovarian cyst when large and fixed may cause hydronephrosis by pressure upon the kidney or ureter.

The diagnosis of bilateral ovarian tumors is readily made when from either tumor a pedicle is traced to the uterine horns. The smaller the tumor the easier the diagnosis. In very large tumors the diagnosis may be impossible. When in the absence of pregnancy and in the presence of a large cystic tumor of the abdomen the menses are suppressed, a bilateral ovarian tumor is suspected. The two tumors are rarely of the same size, and rarely lie on the same level. A furrow may separate the two, and two separate and distinct percussion waves may be elicited. The tumors may be moved separately by bimanual manipulation. Not infrequently the diagnosis is deferred until an exploratory incision has been made.

INTRALIGAMENTOUS DEVELOPMENT OF OVARIAN TUMORS.

It is not always possible to recognize an intraligamentous tumor of the ovary without opening the abdomen. Such tumors lie within the two layers of the broad ligament in close proximity to the uterus and are usually firmly fixed. No pedicle can be palpated. In very exceptional cases the tumor will distend the broad ligament and draw it out into a broad pedicle. Such tumors have some degree

of mobility. Intraligamentous tumors of the ovary rarely grow to a large size. The uterus and tumor appear as one mass, or the uterus may be distinctly outlined from the tumor. In exceptional cases the tumor may burrow beneath the peritoneum behind or to the front of the uterus. When bilateral the uterus may be lifted out of the pelvis.

Ovarian Cysts.	Parovarian Cysts.
1. Develop from the oöphoron.	1. Develop from the parovarium.
2. Commonly multilocular.	2. Usually unilocular.
3. May reach enormous size.	3. Seldom large.
4. Growth usually rapid.	4. Usually slow.
5. Usually pedunculated and movable.	5. Rarely pedunculated and usually fixed.
6. Adhesions about cyst common.	6. Adhesions not common.
7. Tapping not curative.	7. Often curative.
8. Character of contents: contains albumin; is mucinous or thin and watery; clear and transparent, or coffee colored.	8. Character of contents: little or no albumin; clear, watery fluid of sp. gr. 1003 to 1010.
9. Papillomatous growths common.	9. Not common.
10. Rarely intraligamentous.	10. Always.
11. Tendency to become malignant.	11. Seldom becomes malignant.
12. Rarely self-limited in growth.	12. Self-limited in growth.
13. No ovary visible.	13. Ovary attached to the periphery of cyst.
14. Bloodvessels seldom seen to radiate over the surface of the cyst.	14. Large, radiating bloodvessels frequently seen on the surface of the cyst.

Adherent Tumors of the Ovary. From an operative point of view it is very important to recognize the presence of adhesions. It is manifestly more difficult to recognize adhesions in large cysts which have little or no range of motion than in small cysts which under ordinary conditions are freely movable. Adhesions are recognized by the immobility of the tumor, its greater or less degree of tenderness, and, in exceptional cases, by palpating the adhesions in a conjoined examination.

In large cysts the respiratory excursions are less marked when adhesions are present. It may be impossible to determine the degree of mobility unless an anæsthetic is administered. When the cyst is adherent to the parietal peritoneum the abdominal wall moves with the cyst; friction sounds and fremitus may be heard. Adhesions to the mesentery and intestine may permit free mobility of the tumor.

Torsion of the Pedicle. It is of the greatest importance to make an early diagnosis of torsion of the pedicle. Delay in recognizing the condition may terminate disastrously.

Certain conditions are recognized as predisposing to this event, namely, a long pedicle, ascitic fluid, sudden alterations in the intra-abdominal pressure from overexertion, falls, and blows, a growing

pregnant uterus, and the emptying of a pregnant uterus. Torsion of the pedicle is said to occur in about 10 per cent. of ovarian and parovarian tumors.

When both ovaries are cystic the liability to torsion is about as great as when a single cyst complicates pregnancy.

Twisting of the pedicle occurs in all ages and in all kinds of ovarian tumors. Thornton observed it in a thirteen-year-old girl, and Potter in a woman, aged eighty-three years. Dermoid cysts are particularly liable to this accident.

FIG. 179.

An adherent multilocular cyst crowding the uterus into extreme anteversion.

As a result of torsion of the pedicle, many grave complications may arise. Hemorrhage into the cavity of the cyst may rapidly distend it, even to the point of bursting, and may prove fatal. Gangrene of the cyst will rapidly follow when the circulation is completely shut off; peritonitis is then inevitable. If adhesions convey sufficient blood to the cyst, gangrene will not follow and the cyst may remain intact. It is possible for the cyst to be entirely severed from the uterus. In order that the cyst may not undergo

speedy destruction, adhesions must convey a sufficient supply of blood. The tightness of the twist varies with the thickness of the pedicle. Tumors of medium size are most liable to this accident.

The diagnosis cannot be made with certainty. Having previously recognized a pedunculated tumor of the ovary, torsion of the pedicle will be suspected, when the patient is seized with severe pain in the

FIG. 180.

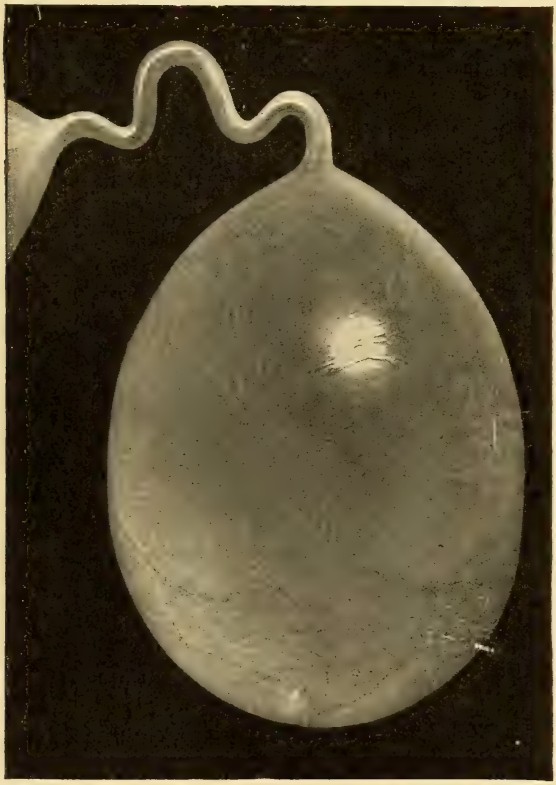

Ovarian hydrocele, natural size. The tortuous, retort-shaped Fallopian tube connects the tumor with the uterus. (DUDLEY.)

region of the tumor, and at the same time the tumor increases in size and is tender to pressure. Collapse may follow immediately upon the twisting of the pedicle. An absolute diagnosis must be reserved for an exploratory incision. Operative interference must be advised upon a provisional diagnosis; the expectant plan of treatment is not to be followed.

A limited degree of torsion may cause no symptoms; there is pain of variable intensity followed by symptoms of peritonitis, including fever, rapid pulse, tympany, and abdominal tenderness. Peritonitis complicating ovarian cysts is most often the result of secondary infection of the cyst.

Torsion of the pedicle of an ovarian tumor must be differentiated from hepatic colic, renal colic, intestinal obstruction, strangulated hernia, appendicitis, ruptured tubal pregnancy, and rupture of a sactosalpinx.

Rupture of an ovarian cyst results from direct violence, torsion of the pedicle, degeneration of the cyst wall, hemorrhage within the cyst and in the wall of the cyst. Spontaneous rupture from thinning of the cyst wall has been reported.

When the cyst ruptures there is a feeling of relief from pressure; the cyst is no longer evident, but if sufficient fluid has escaped the contents may be recognized free in the abdominal cavity. From absorption of the contained fluid the temperature may be slightly elevated and the bowels and kidneys become unusually active. The cyst may rapidly refill.

Leakage of the cyst is a term implying a slow and limited emptying of a cyst into the peritoneal cavity. The daughter cysts, which so often bulge on the surface of the parent cyst, have an extremely thin wall, which may give way at some point and permit the contents to be discharged into the peritoneal cavity. Secondary cysts also rupture into the parent cyst, and in this manner a multilocular cyst may be converted into a unilocular cyst.

Rupture of the cyst may occasion hemorrhage that is either confined within the cyst or that escapes into the free peritoneal cavity. The hemorrhage may prove fatal; this is particularly true of rupture following upon torsion of the pedicle. The escape of the fluid from the cyst is often hindered by the plugging of the rent with a daughter cyst.

Rupture of an ovarian cyst into hollow viscera is possible. Dermoid cysts are particularly likely to adhere to the bowel and to subsequently rupture into it; such cysts are invariably infected.

Hemorrhage into the cyst is the common result of torsion of the pedicle, and the symptoms are usually masked by those caused by the torsion. Puncture and direct violence are additional causes of hemorrhage.

A moderate hemorrhage may cause no clinical symptoms. When the loss of blood is considerable the symptoms are those of internal hemorrhage, together with a rapid increase in the size of the tumor, pain, and high tension in the cyst.

Suppuration of an ovarian cyst was formerly believed to follow tapping and the accidental admission of air. This is possible, but more often suppuration occurs independently of such events. Dermoid cysts are particularly liable to suppuration. The infected cysts are invariably adherent to the bowel, bladder, or vagina, and through these adhesions the infection is conveyed to the cyst.

In acute cases the patient dies from septic infection, unless operative interference is instituted. The symptoms of acute suppuration are characteristic. The temperature is elevated and irregular, the pulse is rapid and feeble, exhaustion and emaciation rapidly develop. The cyst increases in size, and is very tender to pressure. Sutton has observed the temperature to become subnormal in long-standing cases with foul-smelling pus.

When gas generates in the cyst the dull percussion note gives place to tympany. After suppuration the cyst may discharge its contents into the bowel, bladder, vagina, rectum, peritoneal cavity, or through the abdominal wall.

When a fistulous communication is established between the cyst and a hollow viscus, or the abdominal wall, the discharge of pus may be prolonged indefinitely, and the patient finally become exhausted. Fragments of bone, teeth, and hair have sloughed into the bladder from an adherent dermoid cyst. These fragments may become the nuclei of vesical calculi.

It is most unusual for such fistulæ to close spontaneously. The infection frequently travels to the cyst by way of the Fallopian tube. From an infected tube adhesions may develop between the cyst and the omentum, bowel, bladder, and abdominal wall. In a similar manner the appendix is the starting-point of an infection in and about the cyst. Adhesions between the appendix and cyst must be looked for in the course of the removal of the cyst, otherwise death may be caused by tearing through the appendix and bowel.

The diagnosis of malignant degeneration of an ovarian tumor is of the utmost importance, but unfortunately cannot be made with certainty without a microscopic examination.

Bilateral ovarian tumors of the ovary are often malignant, but all forms of benign tumors of the ovary are occasionally bilateral.

The presence of ascites is also suggestive of malignancy, yet malignant tumors of the ovary may exist without ascites, and all forms of new-growths of the ovary may be associated with ascites; this is particularly true of papillomatous growths.

The most suggestive signs of malignant degeneration of new-growths of the ovary are rapid growth, immobility of the tumor, and their firm, nodular character. Partial development within the broad ligament is also said to be suggestive of malignant degeneration. Metastatic growths may be found on the peritoneum and in the viscera. Finally, an exploratory incision will be required in many cases, and even then the diagnosis must sometimes be deferred for a microscopic examination. The consideration of the age of the patient is not of great importance in that malignant tumors of the ovary are known at all ages from the time of puberty.

OVARIAN TUMORS COMPLICATING PREGNANCY.

All forms of ovarian tumors may complicate pregnancy. Probably the most frequent are the dermoids, because they occur early in life, grow slowly, and are very often fixed in the pelvis, where they offer obstruction to labor.

The dangers to be apprehended during pregnancy are:

1. Axial rotation of the tumor.
2. Rupture of the cyst.
3. Incarceration of the tumor in the pelvis.
4. Impediment to respiration when large.
5. Interference with the functions of the abdominal viscera from pressure.

The dangers to be apprehended in labor are:

1. Rupture of the cyst.
2. Torsion of the pedicle.
3. Suppuration of the cyst.
4. Hemorrhage into the cyst.
5. Rupture of the uterus and vagina.
6. Interference with the passage of the fœtus and with contraction of the uterus in the third stage.

Very often pregnancy and labor are not affected by the presence of an ovarian cyst.

The diagnosis of the variety of ovarian tumors is only possible to a limited degree. The diagnosis between a cystic and solid tumor

is seldom difficult. Fluctuation and an exploratory puncture will demonstrate the presence of fluid.

It is manifestly impossible to differentiate clinically a unilocular from a multilocular cyst. When smooth and regular in outline and consistency the cyst is assumed to be unilocular ; when nodular and irregular in consistency and when of enormous size it is assumed to be multilocular. A positive statement can only be made when the cyst is opened.

Dermoid cysts are suspected when a slow-growing tumor, irregular in outline and consistency, is observed early in life.

Papillary cysts are suspected when the new-growths of the ovary are bilateral or intraligamentous, when ascites accompanies them, and when they are irregular in outline.

Exploratory puncture of ovarian cysts was at one time universally employed, not only as a diagnostic measure, but for the purpose of emptying the cyst. The procedure has given way to the more satisfactory and equally safe method of exploratory incision. The fluid removed by aspirating may be so characteristic as to permit a diagnosis not only of the presence of an ovarian cyst, but of the particular variety. Mucinous fluid is characteristic of a pseudomucinous multilocular cyst of the ovary. The serous fluid of an ovarian cyst cannot be recognized from that of ascites or hydronephrosis. Contrary to former belief, the chemical and microscopic analyses are of no special value in differentiating the serous contents of ovarian cysts from ascites. The dangers involved in an exploratory puncture of a cyst are infection of the contents, puncture of a bloodvessel followed by alarming hemorrhage, injury to adherent coils of bowel, escape of the contents of the cyst into the peritoneal cavity, and finally, though rarely, torsion of the pedicle.

Exploratory incision may be regarded as a safer and more satisfactory method. The incision is to be made after the usual preparation for abdominal section.

FATE OF OVARIAN TUMORS.

1. Parovarian cysts are self-limiting in their growth, and if they rupture it is possible that they will never refill.

2. Ovarian cysts may disappear after rupture and torsion of the pedicle, though this is exceptional.

3. Simple cysts of the ovary are self-limited in their growth, but multilocular proliferating cysts are not. According to Olshausen,

proliferating multilocular cysts will cause death from pressure within three years.

4. Proliferating cysts of the ovary cause death by :

a. Exhaustion due to interference with nutrition, sleep, and breathing.

b. Cystitis and pyelitis.

c. Pressure on the ureters, causing hydronephrosis, pyonephrosis, and uræmia.

d. Intestinal obstruction.

e. Suppuration and gangrene of the cyst.

f. Peritonitis.

g. Hemorrhage.

h. Impediment to labor.

CHAPTER XXX.

THE DIAGNOSIS OF PERITONITIS.

THE pelvic peritoneum covers the concave surface of the floor of the pelvis. From the anterior abdominal wall it is reflected to the fundus of the empty bladder, passing downward and backward to the posterior surface of the bladder and reflected on the anterior surface of the uterus at about the level of the internal os. It closely adheres to the body of the uterus in front and behind, and to a point about one-half inch below the attachment of the vagina to the cervix. From this point it is reflected upon the rectum. Between the bladder and uterus the peritoneum forms the so-called vesico-uterine pouch. Between the uterus and rectum is a much deeper and more important pouch, the cul-de-sac of Douglas, which is defined as follows : the upper lateral boundaries are the uterosacral ligaments, the lower lateral boundaries and the floor are of peritoneum, the anterior boundary is the supravaginal portion of the cervix and the upper half inch of the vagina, and the posterior boundary is the rectum and sacrum covered with peritoneum.

At the sides of the uterus the peritoneum forms two laminæ running outward and backward to the sides of the pelvis to a point immediately in front of the sacro-iliac synchondrosis. These laminæ are closely approximated above, where they envelop the Fallopian tubes and are widely separated below by loose connective tissue. These folds are known as the broad ligaments. They enclose the Fallopian tubes, the parovarium and an abundance of connective tissue at the base. The peritoneum is reflected upon the side walls of the pelvis. Over the bladder it is readily separated ; over the uterus it is closely adherent save at the lower portion, where it can be easily stripped from the organ. The upper part of the rectum is closely invested with peritoneum ; the lower portion is loosely so.

GENERAL PERITONITIS.

In general peritonitis the entire peritoneum from the diaphragm to the floor of the pelvis is involved in the inflammatory process.

We will here consider the subject from a gynecological standpoint. Schroeder speaks of:

1. **Benign non-infectious peritonitis** arising from mechanical causes, such, for example, as the escaped fluid and papillomata from an ovarian cyst.

There are none of the clinical manifestations of sepsis, and all general and local clinical evidences of peritonitis may be wanting. In the abdomen there are usually pain, tenderness, and tympany.

2. **Septic peritonitis** arises from the invasion of the peritoneum by septic micro-organisms. These organisms gain access to the peritoneum from infected tubes, ovaries, and pelvic cellular tissue; also, from wounds incident to labor and surgical operations.

In this form there are present the general and local clinical evidences of septic infection. The pelvis and abdomen are tender to pressure; nausea, vomiting, and hiccoughing are usually present; the temperature rises, and the pulse becomes rapid, weak, and irregular. In a streptococcus infection death almost invariably ensues within a week. The general symptoms of septic infection are out of proportion to the local evidences.

Putrid, saprophytic peritonitis due to infection from the bacterium coli and anaërobic bacteria forms a clinical picture which varies in its general and local signs.

There may be few or no local manifestations, but a profound general intoxication is invariably present. Menge says that painlessness and fetid odor to the breath are evidences of colon infection.

Gonorrhœal peritonitis unquestionably exists, but the cases are few. Cushing and Wertheim were first to demonstrate that gonococci can live upon the human peritoneum. Hunner and Harris, of Johns Hopkins, recently reported six cases of gonorrhœal peritonitis.

The general symptoms of infection develop quickly and often to an alarming degree, but the course is usually brief and the prognosis is relatively good.

In all forms of general peritonitis all of the usual signs of peritonitis may fail, and the diagnosis must be held in abeyance until the abdomen is explored.

Tympany is the earliest and most reliable symptom. Pain cannot be relied on; it may be altogether absent. Nausea and vomiting are rather constant symptoms, though unreliable in making a diagnosis. While the temperature is usually elevated it may be normal or subnormal, and does not correspond with the extent of

involvement of the peritoneum. The character of the pulse is a more reliable guide to the general condition of the patient than is the temperature. In direct proportion to the general septic infection the pulse is increased in rate and becomes irregular in rhythm and force. Unrest and anxiety are depicted upon the face.

TUBERCULOUS PERITONITIS.

This disease runs an acute or chronic course with a low grade of fever. A fluid exudate commonly occupies the abdominal cavity. More often the fluid is free, but at times it is encysted between adherent coils of bowel.

Less often the exudate is fibrinous or serofibrinous, resulting in a shortening of the mesentery and adhesion of the peritoneal surfaces of the abdominal viscera. Tubercles stud the peritoneal surface.

The diagnosis may be extremely uncertain or impossible without an exploratory incision. In the absence of other causes, such as puerperal and gonorrhœal infection, and in the presence of tuberculosis elsewhere in the body, the tuberculous nature of the lesion is suspected.

CARCINOMATOUS PERITONITIS.

Carcinomatous peritonitis arising from a cancerous focus in the uterus, tubes, and ovaries may give rise to many of the symptoms common to peritonitis.

It is especially difficult to differentiate a carcinomatous peritonitis from a tuberculous peritonitis. The discovery of the primary lesion will suggest the diagnosis.

Even after opening the abdominal cavity the diagnosis may be uncertain and require a microscopic examination of an excised portion.

PELVIC PERITONITIS.

Definition. Part or all of the pelvic peritoneum is involved in the inflammatory process. We therefore speak of diffuse and localized pelvic peritonitis. When localized various terms are employed to designate the location and extent of the lesion. We speak of *perimetritis* when the peritoneal covering of the uterus is involved; of *perisalpingitis* and *periovaritis* when involving the peritoneal coverings of the tube and ovary.

Of greater clinical importance is the distinction between a general abdominal and pelvic peritonitis and a well-defined pelvic peritonitis. A pelvic peritonitis may be primary or secondary to a general abdominal peritonitis—a fact of prime importance in its bearing upon the diagnosis and treatment.

The infection is usually conveyed through the uterus and tubes to the peritoneum immediately surrounding these organs. A direct invasion from the uterus, tubes, rectum, appendix vermiformis, or bladder occurs with less frequency.

FIG. 181.

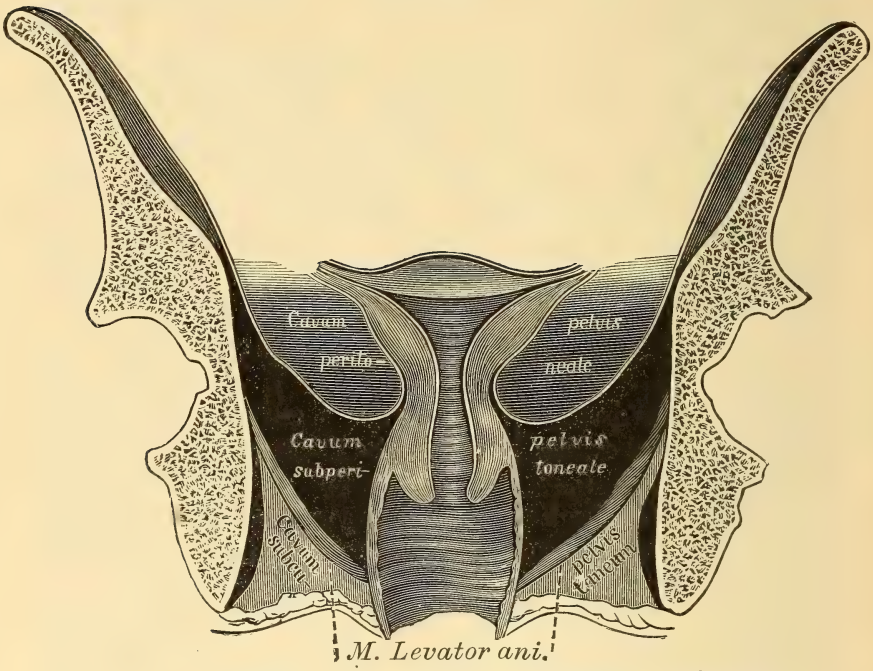

Three divisions of the pelvic cavity, viz., peritoneal, subperitoneal, and subcutaneous. (FEHLING.)

It is possible for infection to be conveyed along the mucosa of the uterus and tubes to the peritoneum without causing anatomical changes in the uterus and tubes, or such changes may be limited to portions of the mucosa.

Likewise, the lymphatic channels may be mere carriers of infection without themselves being involved. We are, therefore, not justified in concluding that infection has not passed by a given route because there are no anatomical evidences of such an event.

Etiology. All that has been said of the etiology of endometritis will apply to pelvic peritonitis, inasmuch as the infection very often primarily attacks the endometrium. Pelvic peritonitis has its starting-point less frequently in an infection of the bowel, bladder, vagina, or general peritoneum. Traumatisms of the perineum, cervix, and vagina incident to parturition and surgical operations may open the way for infection, which is conveyed by the bloodvessels and lymphatics to the peritoneum. The micro-organisms chiefly found in the infected peritoneum are those common to endometritis, salpingitis, and ovaritis—that is, the staphylococcus pyogenes albus, aureus, and citreus, streptococcus pyogenes, gonococcus, colon bacillus, tubercle bacillus, Klebs-Loeffler bacillus, pneumococcus, typhoid bacillus, and actinomycosis.

We speak clinically of acute and chronic pelvic peritonitis, of peritonitic exudates and adhesions.

1. **Acute pelvic peritonitis** shows a marked congestion of the bloodvessels or a diffuse blush of the peritoneal surface. Clinically, this stage is recognized by intense pain and tenderness in the pelvis, contraction of the abdominal muscles, tympany, vesical and rectal tenesmus, and painful menstruation. The temperature is elevated; the pulse is accelerated in proportion to the degree of temperature and general intoxication. Vomiting and hiccoughing are often present in advanced cases, and the patient lies with both legs flexed upon the thighs.

In the acute stage all examinations and manipulations should be restricted as far as possible. It must be borne in mind that acute exacerbations of chronic peritonitis will give all the clinical evidences of a primary acute attack. Upon opening the abdomen, however, evidences will be found of previous involvement. Bandl says that high fever, great tenderness, and tympany in the pelvic regions are sure signs of pelvic peritonitis. It is only after the acute stage has subsided that a bimanual examination will make sure that the pelvic connective tissue is not diseased and that the peritoneum alone is affected. As a rule, the early symptoms must be relied upon in making the diagnosis, for in the majority of cases no palpable exudations take place.

2. **Chronic pelvic peritonitis** usually begins as an acute infection, but may be chronic from the beginning. Bandl says: "The lesion can be diagnosed in girls and sterile women when, during the menstrual period or at any other time, with or without fever, there

exist deep-seated pain in the pelvis and more or less tenderness over the lower portion of the abdomen. If the symptoms are confined to one side, as is usually the case, the process is most probably present in the form of a perisalpingitis and perioöphoritis." In the opinion of the author, it is not possible to arrive at any intelligent conclusion from the above data as to the existence of chronic pelvic peritonitis. Too often mistakes are made by relying upon the complaints of nervous and ignorant patients. A physical examination will alone serve to differentiate the many possible causes of such complaints as are found in the inflammatory involvements, the displacements, and the new formations of the uterus and adnexæ. The anatomical evidences of chronic pelvic peritonitis are inflammatory exudates and adhesions.

Peritoneal exudates follow closely upon the initial acute stage. The exudate is serous, seropurulent, or purulent, and may be found to occupy part or all of the pelvic cavity. The most dependent portion of the peritoneal cavity is the cul-de-sac of Douglas, and into it the peritoneal exudate naturally gravitates. It is possible for such an exudate to cause a bulging of the posterior vaginal fornix, though this is not the rule unless the underlying cellular tissue is involved. In a vaginal examination an exudate in the pouch of Douglas is sharply outlined, rounded below, and flat on the top. When too abundant to be wholly contained within the cul-de-sac, the exudate spreads out upon the posterior surface of the uterus, may extend laterally, and has been known to fill the entire inlet of the pelvis. The adherent and oftentimes distended intestine gives an indefinite outline to the upper border of the exudate.

The consistency of the exudate is variable. Fluctuation may be marked, or the exudate may appear firm by virtue of the surrounding inflammatory infiltration.

In exceptional cases the exudate is located at the side or in front of the uterus. It is difficult to palpate it through the vagina because of the high location. Without anæsthesia there is an indefinite sense of resistance at the seat of the exudate. Under anæsthesia the inflammatory mass may be fairly outlined. Where a fluid exudate is encapsulated by adhesions, "adhesion cysts," it is possible to mistake it for a sactosalpinx or an ovarian cyst.

Peritoneal adhesions may follow a serous or purulent exudate, or may develop independent of a fluid exudate. The adhesions may

involve any part or all of the pelvic peritoneum. They manifest great variations in development, from a delicate fibrillar structure to dense bands. They are most frequently found about the adnexæ and behind the uterus. Much less frequently are they found in front of the uterus, for the reason that the infection commonly travels through the tubes to the peritoneum, and it is unusual for the tubes to lie in front of the uterus.

Fig. 182.

Peritoneal adhesions bind the uterus in retroposition.

Gonorrhœa is the most common cause of adhesions, and next in point of frequency are the infections following labor and abortion. As a result of the adhesions the uterus and adnexæ are more or less fixed, and their position is altered by contraction of the adhesions. With the exception of prolapsus and inversion of the uterus, all sorts of malpositions are caused by adhesions about the uterus and its appendages.

The clinical diagnosis rests upon the physical findings. In a conjoined examination the adhesions are recognized as cords and bands,

rarely as a diffuse thickening surrounding the viscera of the pelvis and uniting their peritoneal surfaces.

The abnormal fixity of the organs and their displacement are suggestive of the presence of adhesions. Not infrequently such fixity and displacements are recognized in an examination without anæsthesia, and it is presumed that adhesions exist, though they are not demonstrated without the administration of an anæsthetic.

Where displacements of the uterus and adnexæ with restricted range of motion are associated with tenderness and an indefinite sense of resistance at the side of or behind the uterus, an anæsthetic should be administered to determine the possible presence of adhesions and exudates.

Differential Diagnosis. It is at times extremely difficult to differentiate a pelvic peritonitis from a *hyperæsthesia peritonii* found in women of nervous temperament. The general nervous state of the individual, the absence of all causes of infection, and, finally, a conjoined examination under anæsthesia will serve to establish the diagnosis.

A retroflexed gravid uterus may be confounded with a peritonitic exudate. The fact of pregnancy should be determined by the usual signs. In the first trimester the cessation of menstruation and nausea is occasionally simulated by like complaints due to the inflammatory lesion about the uterus in the absence of pregnancy. Such exudates are most often found in multiparæ in whom the changes in the breast are not usually well-marked during the early months of pregnancy. Of greatest importance are the changes in size, form, consistency, and the rate of growth of the uterus. An effort to replace the uterus without anæsthesia, or, if this fails, with anæsthesia, will determine the presence or absence of adhesions.

In exceptional cases a uterus fixed by adhesions cannot be distinguished from an incarcerated uterus without an exploratory incision. This is particularly true where adhesions bind the uterus loosely to such movable structures as the bowel, omentum, and bladder.

Where the uterus is fixed and tender to pressure adhesions are suspected, even though they cannot be felt under anæsthesia.

A retro-uterine hæmatocele may organize into peritoneal adhesions in the absence of infection. The history and physical evidence of an ectopic pregnancy, together with the usual signs of a hæmatoma and the absence of a history of infection, will serve to differentiate this condition from true inflammatory peritonitic adhesions.

Tuberculous peritonitis with encysted fluid, according to H. Dure, is differentiated from an ovarian cyst by a family history of tuberculosis, signs of the existence of other tuberculous lesions, a history of frequent abortions or of the death of several children from tuberculosis; general symptoms of tuberculosis, such as loss of weight, strength, and appetite, evening rise of temperature, night sweats, pelvic pains, amenorrhœa, leucorrhœa, and the previous occurrence of salpingo-oöphoritis.

The differential diagnosis of pelvic inflammatory exudates from sactosalpinx and ovarian cysts is referred to in the chapters on Diseases of the Tubes and Ovaries.

CHAPTER XXXI.

THE DIAGNOSIS OF PARAMETRITIS (PELVIC CELLULITIS).

THE loose connective tissue of the pelvis lies immediately beneath the peritoneum. It surrounds the supravaginal portion of the cervix, and extends laterally between the layers of the broad ligament and along the sides of the pelvis. There is but a small amount of connective tissue in front of the uterus beneath the vesico-uterine fold of peritoneum. Behind the uterus and beneath the uterorectal fold of peritoneum is a considerable amount of loose connective tissue so intimately connected with the rectum, cervix, and vagina that it frequently becomes the seat of infection.

A knowledge of the location, loose texture, and relation of the connective tissue to the neighboring structures will serve as a basis for our understanding of pelvic cellulitis.

Definition. By parametritis is meant an inflammation of the cellular tissue of the pelvis. The extent of the lesion varies. While sometimes diffuse, it is usually localized. According to the location of the lesion we recognize *paracystitis*, when the limited amount of connective tissue about the base of the bladder is involved; *paraproctitis*, when the inflammation is in the cellular tissue about the rectum; *paravaginitis*, when it is about the vagina; *posterior parametritis*, when in the connective tissue lying within the uterosacral folds and beneath the floor of the pouch of Douglas, and *lateral parametritis*, when between the layers of the broad ligament.

Classification. Freund classifies parametritis as follows:

I. ACUTE INFLAMMATION OF THE PELVIC CONNECTIVE TISSUE WITH OR WITHOUT ABSCESS FORMATION.

a. Simple phlegmon.

b. Septic phlegmon.

II. CHRONIC INFLAMMATION OF THE PELVIC CONNECTIVE TISSUE.

a. Circumscribed atrophic.

b. Diffuse atrophic.

The causes of pelvic cellulitis are identical with those of pelvic peritonitis, and it is the rule that these lesions rarely exist singly.

I. **Acute Parametritis.** The initial symptoms are, as a rule, less violent than in acute pelvic peritonitis. This is particularly true of the pain and tenderness. The effect upon the pulse and temperature may be equally severe.

FIG. 183.

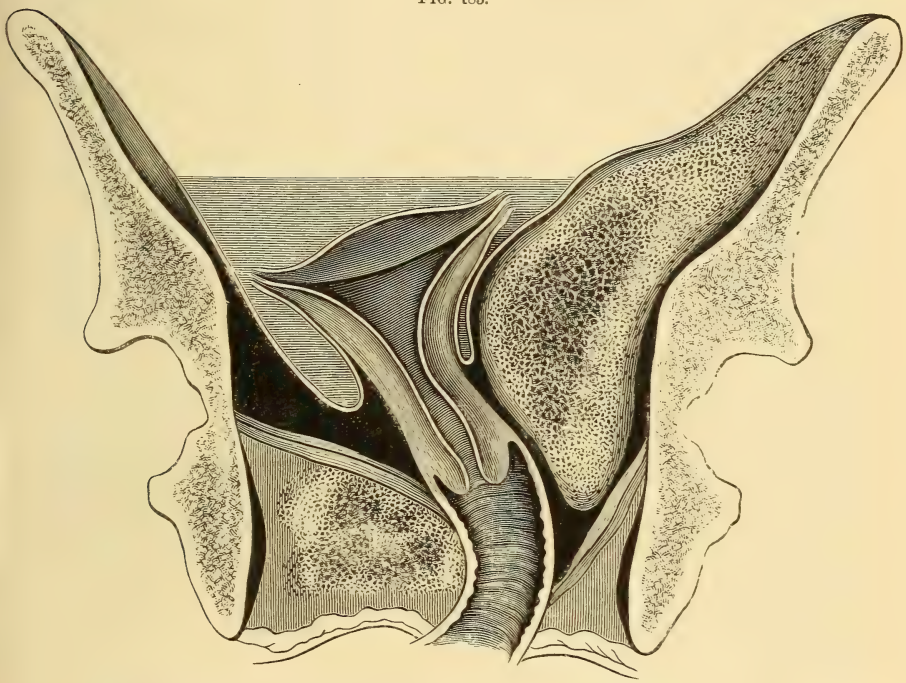

Parametritis. Exudate in left subperitoneal cavity, crowding corpus uteri to right. Paracolpitis in right subcutaneous cavity, crowding cervix uteri and vagina to left. This latter would produce a perianal abscess, and would usually be followed by fistula in ano. (DUDLEY.)

Bandl says: "If a day or two after an attack of fever and the appearance of the described initial symptoms the uterus is found enlarged transversely in the region where the broad ligaments leave it, parametritis certainly exists, and it is hardly necessary to prove it by bimanual examination. If after fever has lasted for several days points of resistance are found over Poupart's ligament corresponding to the seat of pain and tenderness; or if swellings have formed above or extend to the centre of Poupart's ligament, or internally to the anterior superior spine of the ilium, the convex

border of which is readily felt or even seen ; or if by firm pressure of the abdominal wall tumors corresponding to the broad ligament are found, then it is also certain that the process involves the parametrium. If still doubtful, the diagnosis may be confirmed by vaginal examination, which in most cases will reveal the presence of large masses at the sides of the uterus, extending anteriorly or laterally to the pelvic wall, or filling one side of the pelvic cavity, showing clearly that the swellings felt through the abdominal wall are masses of exudation extending below the peritoneum."

In many cases the exudate cannot be felt through the abdominal wall, because it lies low in the pelvis and is only to be palpated through the vagina. " If with more or less inflammatory symptoms masses form in the neighborhood of the cervix, or extend to the deeper portions of the pelvis, being doughy and soft at the beginning but rapidly becoming harder, or if large, well-defined swellings form in the true pelvis, in front of or behind the uterus, the process can be none other than phlegmonous inflammation of the cellular tissue."

II. **Chronic parametritis** is diagnosed from the position and consistency of the exudate and its relation to neighboring structures. The history of the infection, together with the general and local symptoms, can no more than suggest the probable nature of the lesion.

Position of the Exudate. The exudate occupies the position of the pelvic connective tissue and with greatest frequency in localities where the connective tissue is most abundant, namely, behind the uterus and between the layers of the broad ligaments. In either case the exudate lies low in the pelvis.

When involving the connective tissue at the base of the broad ligaments the exudate spreads to the sides of the pelvis. Behind the uterus it bulges down into the vagina, forming a rounded, tender swelling in the posterior cul-de-sac. When involving the connective tissue at the sides of the pelvis, it spreads into a flat mass which may or may not connect with the uterus by an elongated exudate within the broad ligament.

It is possible for the exudate to dissect in front and behind in the subperitoneal connective tissue of the abdominal wall. It is impossible for the exudate to burrow to a level above the umbilicus, because at this level the subperitoneal connective tissue disappears, nor can the dissection go beyond the median line. In this manner

an abscess may burrow, there being a greater tendency on the part of purulent collections to gravitate to a lower level than is the case with non-suppurative exudates. The abscess is finally discharged through the bladder, vagina, rectum, abdomen, or through one of the pelvic foramina.

The form of the exudate varies according to its consistency and location. The exudate moulds itself to neighboring structures. Beneath the cul-de-sac of Douglas it is somewhat rounded because of the limited resistance offered by the surrounding soft structures. Between the resisting layers of the broad ligaments the exudate is flattened, and the same is true to a greater degree at the sides of the pelvis. As the exudate is absorbed its form changes, because this removal proceeds irregularly.

Mobility in the exudate is scarcely perceptible. If attached by a broad base to an immovable structure the exudate will be firmly fixed. A small exudate within the broad ligament may show some degree of mobility, but as a rule we speak of cellular exudates as fixed and immovable.

The consistency is also subject to great variations, depending upon the character of the exudate, whether œdematous, fibrinous, or purulent. At one time it is soft and fluctuating, and again it is as firm as cartilage. In the early development of the exudate the consistency is elastic and yielding ; later it becomes firm from organization and contraction. If suppuration ensues there will be a boggy and possibly fluctuating mass. The consistency is best determined by rectal and vaginal palpation.

Tenderness to pressure is characteristic of all inflammatory lesions. Large exudates may exist with very little tenderness, but usually the tenderness is a reliable guide to the inflammatory character of the mass.

The relation of the exudate to neighboring organs is most important in the consideration in differentiating from new formations in the pelvis. The exudate blends intimately with adjacent structures and cannot be outlined apart from them.

In intraligamentous exudates the mass lies snugly against the side of the uterus, sometimes surrounding the supravaginal portion of the cervix, but never extending to the fundus. In paravaginitis it may be impossible to move the vaginal mucosa from the exudate. In paraproctitis the exudate may bulge into the rectum, narrowing the bowel and so intimately blend with the wall of the rectum that it

moves as one mass. In the absorption of the exudate the periphery is first to disappear. In an intraligamentous exudate the mass may retreat from the side of the pelvis and form an elongated or rounded swelling firmly adherent to the uterus.

Differential Diagnosis. The distinction between a perimetric and a parametric exudate is at all times difficult. Certain well-defined points of distinction serve to differentiate the two lesions, but it is to be remembered that they commonly coexist.

Parametritis.	Pelvic Peritonitis.
1. Exudate lies low in the pelvis.	1. Lies high in the pelvis.
2. Pain may not be great, and is dull and continuous.	2. Pain usually more intense, sharp, lancinating, and paroxysmal.
3. Exudate commonly at the side of the uterus, never extending to the fundus.	3. Exudate commonly behind the uterus, often extending to the fundus.
4. Exudate of firm consistency; tendency to suppuration.	4. Commonly less firm; no great tendency to suppurate.
5. Uterus partially fixed.	5. Uterus may be firmly fixed.
6. Tympanitis usually absent.	6. Tympanitis usually present.
7. Facial expression may be natural.	7. Facial expression anxious.
8. Nausea and vomiting not common.	8. Nausea and vomiting common.
9. One leg flexed.	9. Both legs flexed.

Retro-uterine Parametritis.	Retro-uterine Perimetritis.
1. Outline rounded below and sharply circumscribed.	1. Outline diffuse, not sharply circumscribed.
2. Exudate cannot extend to fundus.	2. Exudate may extend above fundus.
3. Uterus may be crowded forward; usually only the cervix is crowded forward.	3. Uterus may be crowded forward by the exudate or drawn backward by adhesions.
4. Rectum firmly and closely surrounded by exudate in front and at the side.	4. Rectum crowded backward by exudate.
5. Mucosa of rectum does not move upon the exudate.	5. Mucosa moves independently of the mass.
6. Posterior vaginal fornix depressed.	6. Usually not depressed.

A paratyphlitic exudate is not infrequently confounded with an intraligamentous parametritis. It is possible for a paratyphlitic exudate to burrow between the layers of the broad ligament to the side of the uterus.

Perityphlitis.	Parametritis.
1. Initial symptoms: nausea, vomiting, constipation, fever, pain at McBurney's point.	1. Initial symptoms: fever, constipation, pain low in the pelvis at the side of the uterus, rarely nausea and vomiting.
2. Tendency of a parametric abscess is to rupture into the bowel and peritoneal cavity.	2. Little tendency to rupture into the bowel and peritoneal cavity.
3. Tendency to recurrence.	3. Tendency to recurrence not so great.
4. Exudate lies high on the right side and spreads from above downward.	4. Exudate lies low in the pelvis and spreads from below upward.

A pelvic hæmatoma may so closely resemble a parametric exudate as to be indistinguishable without an exploratory incision or punc-

ture. Both lesions are confined to the cellular tissue of the pelvis and in general contour, size, and consistency they may be quite similar. The following tabulated points will usually serve to differentiate the two :

Pelvic Hæmatoma.	Parametritis.
1. Develops suddenly.	1. Develops more gradually.
2. History of ectopic pregnancy.	2. Absent.
3. Onset marked by normal or subnormal temperature and rapid, feeble pulse.	3. Onset marked by rise of temperature and increased pulse rate.
4. Exudate usually beside the uterus and circumscribed.	4. Exudate beside or behind the uterus and less circumscribed.
5. Exudate at first doughy, later firm, never tender unless infected.	5. Exudate firmer and tender.
6. Exploratory puncture, blood.	6. Exploratory puncture, serum, pus, or negative.

Subserous fibroids may be confounded with a parametric exudate. When the exudate is round and attached by a broad base to the uterus and not especially tender on pressure, the diagnosis is difficult and may not be cleared up without an exploratory incision. The difficulty of diagnosis is especially great in intraligamentous fibroids. The more movable the mass the more likely it is to be a fibroid. In a cellular exudate there is a history of infection and the mass grows rapidly. In fibroids there is no history of infection and the growth develops slowly. The depth of the uterine cavity is increased in case of fibroids beyond that found in parametritis. The effects of treatment will aid in the diagnosis ; in parametritis the mass should diminish under treatment, while in fibroids little or no effect will be observed.

Malignant diseases of the pelvis, involving the parametrium, may arise from a primary focus in any of the pelvic viscera. There is absence of a history of infection, no acute onset being experienced, and there are present the general symptoms of malignancy rather than of infection. The primary seat of malignancy can usually be determined, and the hard, irregular character of the infiltrated area will serve to indicate the condition.

Parametritis.	Psoas Abscess.
1. Usually of acute origin.	1. Usually of chronic origin.
2. Absence of spondylitis.	2. Spondylitis present.
3. Exudate tender to pressure.	3. Exudate not tender to pressure.
4. Fluctuation may be absent; induration about abscess always present.	4. Fluctuation only occasional; no hard exudate about abscess.
5. Thigh flexed, not rotated.	5. Thigh flexed and rotated inward.
6. Temperature may be high.	6. Temperature absent or slight rise, especially in the morning.
7. Exploratory puncture shows absence of tuberculous exudate and tubercle bacilli.	7. Presence of same.
8. Tuberculin gives no reaction.	8. Tuberculin usually gives a reaction.

PART III.

THE DIAGNOSIS OF THE DISEASES OF THE URINARY SYSTEM.

CHAPTER XXXII.

THE DIAGNOSIS OF THE DISEASES OF THE URETHRA AND BLADDER.

WINCKEL, in his monograph on "Diseases of the Female Urethra and Bladder," has pointed out that much that is now known of the diseases of the urethra and bladder was known hundreds and thousands of years ago, and, having been forgotten, was rediscovered by late observers. The Cnidian school possessed a fairly accurate knowledge of diseases of the bladder, as did the Indians 100 B.C. Ætius (502–575 B.C.) described ulcerative affections of the bladder, and Paul of Ægina (670 A.D.) treated diseases of the bladder by means of injections through a catheter. In the nineteenth century Simon devised a series of conical specula with obturators, by which the urethra could be dilated to the extreme degree, permitting a digital examination of the bladder. From that time to the present methods of examining the urinary tract have been rapidly introduced and perfected. We are especially indebted to Max Nitze, K. Pawlik, M. Sänger, and Howard Kelly, whose contributions to this department of the diseases of women rank with the most important of the past century.

Anatomy and Physiology of the Urethra and Bladder. **Urethra.** The average length of the female urethra is one to one and a half inches. It runs from below upward and backward in a straight or slightly curved line, and its anterior extremity lies about four-tenths of an inch below the symphysis.

The wall of the urethra is about one-fifth of an inch thick, and possesses an unusual amount of elastic fibre, which permits a great

degree of stretching. The epithelium in the lower segment of the urethra resembles the stratified epithelium of the vagina, while that of the upper segment is like that of the bladder.

Near the external urethral orifice Skene found two lacunæ which he regarded as glands. They are known as Skene's ducts. Their orifices, which open into the urethral canal, are about one-twentieth of an inch in diameter. The ducts are about one-quarter of an inch long and run upward along the wall of the urethra. A fine probe can be inserted into them for about one inch.

Numerous smaller lacunæ lie along the course of the urethra. These are lined with transitional epithelium, the lowermost being a single layer of cylindrical epithelium. Higher up it becomes stratified cylindrical, and near their mouth it becomes flat pavement. In addition to these lacunæ there are numerous small mucous glands opening into the canal. Beneath the mucosa is the submucosa composed of an elastic network, and external to this is the muscular wall composed of longitudinal and circular muscular fibres.

The external orifice of the urethra is a vertical oval opening one-fifth of an inch long, while the internal orifice is a mere slit.

Bladder. The empty female bladder lies in the median line behind the pubis and in front of the vagina. When the fundus is distended it inclines slightly to the right side and may reach to the level of the umbilicus. The average capacity is 400 grammes, which is somewhat less than that of the male bladder. The minimum capacity is 20 to 30 grammes, and the maximum 3320 grammes (Fritsch). The bladder wall consists of three layers—peritoneal, muscular, and mucous.

1. The PERITONEUM covers the fundus of the bladder and is reflected to the anterior surface of the body of the uterus and to the anterior abdominal wall. It is loosely adherent to the muscularis. When the bladder is greatly distended the peritoneum is so drawn upward that a hand's breadth of the bladder not covered with peritoneum presents above the pubis—a fact to be remembered in suprapubic operations on the bladder.

2. The MIDDLE LAYER consists of unstriped muscular fibres arranged in three sublayers, namely, an external layer of longitudinal fibres, a middle layer of oblique and transverse fibres, and an internal layer of longitudinal fibres.

3. The INTERNAL LAYER—mucosa—is composed of several layers of transitional epithelium resting upon a loose connective

tissue base. Folds or rugæ are found over the entire inner surface of the bladder, with the exception of the trigone and openings. These are due to laxity of the mucosa. In the trigone the mucosa closely adheres to the submucosa, and therefore no folds are to be seen. Small acinous glands which secrete mucus are distributed in the mucous membrane of the fundus and about the internal sphincter.

The bladder is rich in bloodvessels. A thick, capillary network runs beneath the superficial epithelium of the mucous membrane. The vertex is not so richly supplied with bloodvessels as the deeper parts. The arteries supplying the bladder are the vesicularis superior and inferior branches of the arteria hypogastrica. The veins empty into the plexus pudenda vesicularis.

The nerve supply comes from the plexicus hypogastricus inferior of the sympathetic system and from the third and fourth sacral nerves.

The bladder has three openings: the internal orifice of the urethra and the two orifices of the ureters, which lie one and one-half inches above and to either side of the urethral opening. The ureteral openings are separated about one inch and are connected by a prominent fold of the mucous membrane known as the ligamentum uretericum. The three openings form the angles of a triangle known as the *trigone.* Above the trigone on the posterior wall of the bladder is the *bas fond,* and all the bladder lying above the level of the ureteral openings is known as the body or fundus. That which will be spoken of as the sphincter vesicæ probably consists of the folds of mucous membrane at the internal orifice of the urethra.

Physiology of the Bladder. The ureters and bladder possess peristaltic movements by which the urine is forced through the ureters into the bladder and from the bladder past the sphincter internus. These systolic and diastolic movements of the bladder have an important clinical bearing in that rest cannot be given to the inflamed bladder without artificial drainage. The anterior wall of the empty bladder lies upon the posterior wall. When the urine enters the bladder it first gravitates to the side pockets and gradually elevates the anterior wall. Before the bladder is distended the walls are lax and flat; after distention they become tense and rounded.

Topography of the Bladder. By the present perfected methods of examination it is possible to bring into view and to directly

treat all lesions of any portion of the bladder ; hence the necessity of exact means of describing the location and extent of these lesions. The following scheme of divisions and subdivisions of the interior of the bladder is proposed by Howard Kelly :

1. The natural landmarks within the bladder.
2. The relation of the bladder to surrounding structures.
3. An artificial division into hemispheres and quadrants.

1. **The Natural Landmarks in the Bladder.** (*a*) The INTERNAL ORIFICE OF THE URETHRA marks the junction of the urethra and bladder.

(*b*) The URETERAL ORIFICES are to be regarded as the most important of the landmarks of the bladder. The orifices lie at the top or to one side of the so-called ureteral prominences, which are truncate cones 5 x 3 mm.

(*c*) URETERAL FOLDS is a name given by Kelly to designate rounded elevations sometimes seen in the mucosa stretching backward and outward from each ureteral opening toward the pelvic walls and for a distance of about three-quarters of an inch. They are regarded by Kelly as the terminal ends of the ureters as they pass through the bladder walls.

(*d*) The TRIGONE is a triangular area at the base of the bladder, having angles formed by the internal urethral and the two ureteral openings ; the sides connecting these openings bound the trigone and are about one inch long at the base and three-quarters of an inch long at either side. Many of the lesions of the bladder are confined to this area.

(*e*) The INTERURETERIC LIGAMENT connects the ureteral eminences and is seen as a line sometimes elevated and separating the smooth, deeper colored surface of the trigone from the paler surface of the bladder.

(*f*) Kelly calls attention to the important points relating to the FIXED AND MOVABLE PORTIONS OF THE BLADDER. As the bladder is emptied the upper and more movable portions settle down into the lower and more fixed portions like one saucer within another. He observes that the location of inflammatory lesions is determined somewhat by the movable and fixed areas. Viewing the interior of the bladder with a cystoscope, the respiratory movements define the movable area as contrasted with the fixed portion.

The edges where the two saucers meet form *three folds*, a pos-

terior and two lateral folds. The apices formed by the meeting of these folds are known as the *right* and *left vesical cornua.*

2. **Relations of the Bladder to Surrounding Structures.** The trigone lies in close proximity to the anterior vaginal wall. Above this the base of the bladder is in direct apposition to the supra-vaginal portion of the cervix. The upper half of the bladder is loosely covered with peritoneum. The above relations are important in operative procedures upon the bladder and surrounding structures.

FIG. 184.

Expression of pus from the ducts of Skene's glands. (KELLY.)

3. **Artificial Division of the Bladder into Hemispheres and Quadrants.** The distended bladder may be regarded as a sphere divided into right and left hemispheres. The intersection of sagittal and horizontal planes further divides the bladder into quadrants—the right upper and lower quadrants and the left upper and lower quadrants.

Methods of Examining the Urethra and Bladder:

1. PERCUSSION.
2. PALPATION.
3. CATHETER and SOUND.
4. INSPECTION (specular).
5. URINALYSIS.

1. By **percussion** a bladder distended with fluid may be outlined. The area of dulness may extend to the umbilicus. The more dis-

tended the bladder, the more conical the shape. A bladder distended with air gives a high-pitched tympanitic note.

2. By **palpation** many of the lesions of the urethra and bladder are detected.

(*a*) The urethra is directly palpated along the median line of the anterior vaginal wall. In urethritis palpation will be painful in proportion to the intensity and extent of the inflammation; the urethra may be felt as a firm cord.

FIG. 185.

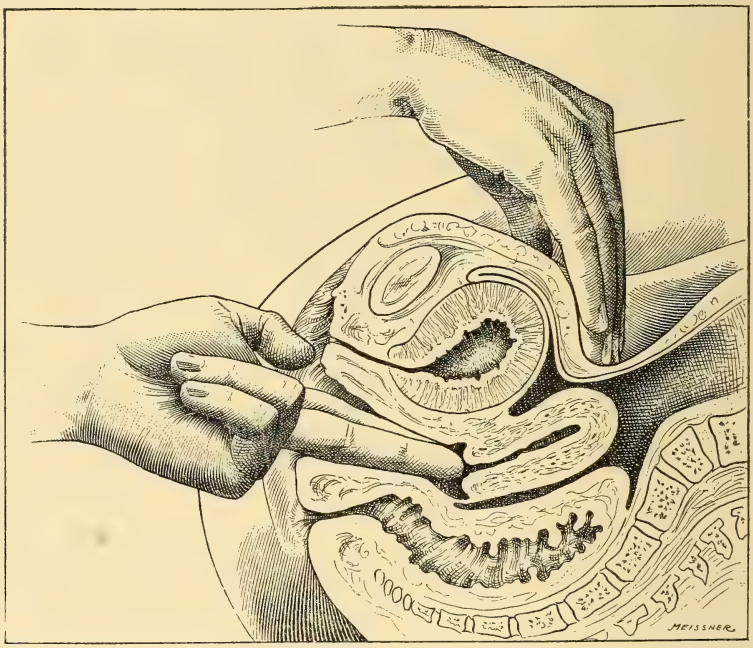

The thickened bladder is engaged between the index and middle finger of the right hand in the vagina, and the fingers of the left hand over the abdomen.

Fissures and caruncles at the urethral orifice are exquisitely sensitive to pressure.

By previously dilating the urethra with bougies it is possible to insert the finger through the urethra into the bladder for the purpose of detecting irregularities and foreign growths.

(*b*) The bladder when empty is seldom recognized in a bimanual examination. In cystitis tenderness and pain are proportionate to the intensity and extent of the lesion. In chronic cystitis, and particularly in tuberculous cystitis, the thickened bladder wall may be

distinctly palpated through the vagina. Stone may sometimes be palpated and outlined in an abdomino-vaginal examination.

Kelly recommends placing the patient in the knee-chest position and letting the air distend the vagina, when the fingers of both hands can be brought close together and the entire bladder be distinctly outlined.

While possible to palpate a portion of the interior of the bladder through the dilated urethra, such a procedure is no longer to be recommended in view of the more efficient and less objectionable method of direct inspection.

3. By **Catheter and Sound.** By the use of the catheter the urine is evacuated from the bladder and can be examined free of contaminations with products of the urethra and vagina. By the catheter foreign bodies, stricture, and fistulæ are sometimes detected in the urethra and bladder. The sound is a more efficient instrument for the detection of such conditions.

4. **Inspection** of the urethra and bladder has been made possible by the contributions of Nitze, Casper, Pawlik, Skene, Simon, Kelly, and others. In almost all diseases of the urethra and bladder it is desirable to make an exact diagnosis by direct inspection.

FIG. 186.

Urethral calibrator.

The lesions involving the urethral orifice can be recognized by direct ocular inspection. Pus seen to ooze from the urethra is, with few exceptions, recognized as of gonorrhœal origin. The orifices of Skene can be directly inspected by separating the lips with the fingers. By separating the labia and introducing a speculum direct inspection will disclose a vesicovaginal fistula, vesicocele, and tumors of the base of the bladder and urethra growing into the vagina.

Urethroscopy. An endoscope is introduced the entire length of the urethra. Light is reflected by a head mirror into the urethra as the instrument is withdrawn. The mucosa collapses about the end of the urethroscope, forming a flat funnel which can be directly inspected. By virtue of the compression the mucosa is unnaturally pale. Polyps, new-growths, foreign bodies, ulcers, and inflamed surfaces are thus brought into the field of vision and are made accessible to direct treatment.

Cystoscopy. Two methods of inspecting the interior of the bladder will be described—the Kelly-Pawlik and the Nitze. There

are numerous modifications of these methods, all worthy of consideration were there space to devote to them.

FIG. 187.

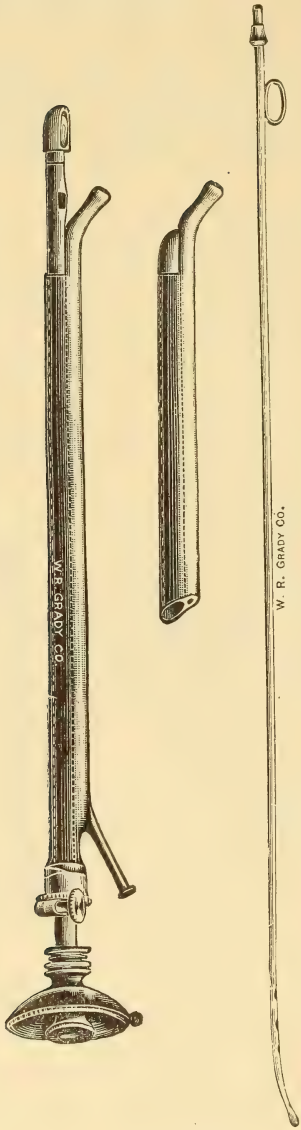

FIG. 188.

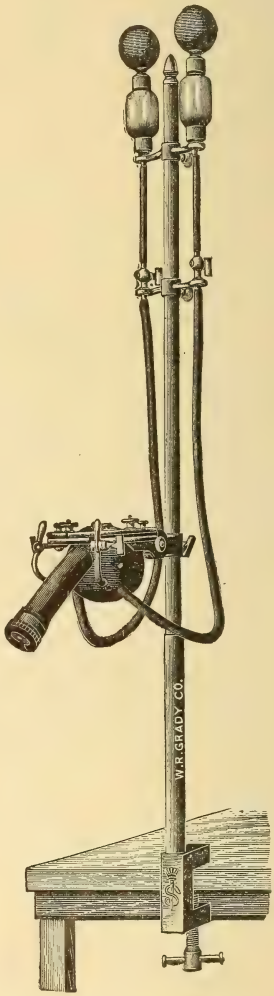

FIG. 187.—Nitze's ureter cystoscope for illuminating the bladder and simultaneous catheterization of the ureters.

FIG. 188.—Janet-Frank's bladder phantom. Intended for practising cystoscopy, ureteral catheterization, and intravesical operations.

The *Nitze cystoscope* is not in general use in the United States, preference being given to the direct method of Kelly and Pawlik. On the Continent the Nitze and various modifications, such as Casper's, are quite generally used. Each has its merit, and is deserving of full consideration.

The following are the advantages of the Nitze cystoscope as compared with the Kelly-Pawlik :

1. A general anæsthetic is seldom required.
2. The lithotomy position is used to the best advantage.
3. The bladder is more completely dilated with water than with air.
4. The urethra is not widely dilated, hence incontinence of urine seldom occurs.
5. No assistance is required in making the examination.
6. Less skill and a shorter time is required in making the examination.

Technic. Four conditions are prerequisite to the use of the Nitze cystoscope :

1. Permeability of the urethra, sufficient to easily permit the passage of the cystoscope. This requires a diameter of not less than 5 mm.
2. A capacity sufficient to retain at least 100 c.c. of fluid.
3. Power on the part of the sphincter vesicæ to retain the fluid.
4. Transparent fluid.

1. *Permeability.* It is essential that the cystoscope should pass into the bladder without meeting unusual resistance. Otherwise the pressure on the mucus glands may smear the lamp with mucous secretion and thereby obscure the field of vision. Where an obstruction exists in the urethra it must be removed before the cystoscope is introduced. Strictures and foreign growths of the urethra are uncommon in women. Spasmodic contractions of the sphincter vesicæ may obstruct the passage of the cystoscope, but this may be overcome by slow, continuous pressure and by an anæsthetic.

2. *Capacity of the Bladder.* The usual amount of fluid injected into the bladder preparatory to making a cystoscopic examination is 250 c.c. A capacity of less than 100 c.c. precludes the examination, because of imperfect distention of the bladder and the danger of overheating the mucous membrane. If irritability of the urethra and bladder does not permit the retention of a sufficient amount of

fluid with which to distend the bladder, it may be possible to overcome the irritability by the application of a 2 per cent. solution of cocaine to the sphincter vesicæ. Injection of the solution into the bladder is not regarded as a safe procedure. Where this will not overcome the irritability, rest must be enjoined until it has subsided. In the absence of cystitis the irritability readily reacts to the influence of cocaine applied to the urethra.

Several fatal cases of cocaine poisoning have resulted from injection of the solution into the bladder.

If the indication for a cystoscopic examination is urgent in the presence of an irritable bladder and urethra, a general anæsthetic may be given.

The female bladder will not distend so evenly as will the male bladder, because of the union of the posterior wall with the cervix and vagina, and because of the encroachment of the uterus, adhesions, pelvic tumors, and other swellings upon the bladder.

3. *Integrity of the Sphincter Vesicæ.* If for any reason the bladder will not retain the urine, the Nitze cystoscope should be discarded in favor of the Kelly-Pawlik.

4. *Transparent Medium.* The injected fluid must be sterile, non-irritating, and transparent. A normal salt solution, sterile water, or, preferably, a saturated solution of boric acid may be used. Carbolic acid, bichloride solution, and formalin are too irritating, causing an unnatural congestion of the mucosa.

The lithotomy position is preferred, the patient lying on a high table. The urethral opening is cleansed as for the passing of a catheter. The urine is then withdrawn through a soft-rubber or glass catheter, and without withdrawing the catheter the bladder is irrigated with a boric acid or normal salt solution. A fountain syringe may be employed, but a piston syringe holding 250 c.c. is better. When the injected fluid is returned clear, about 250 c.c. of the fluid is left in the bladder preparatory to the introduction of the cystoscope. As a rule, the fluid returns clear after two or three injections. Where there exists a sediment of mucus, blood, or pus several injections may be required, and there are cases in which it is impossible to bring about perfect clarity. In such cases the contained fluid is being continually contaminated by blood and pus from the kidneys and ureters. When this is the case it is best to slowly inject a small amount of the fluid and to repeat the injection before all of the fluid is returned. By taking this precaution the

sediment at the bottom of the bladder will not be disturbed. It sometimes occurs that mucus, pus, and concretions so cling to the wall of the bladder that it is impossible to carry out a cystoscopic examination. The fluid may appear cloudy because the lamp is smeared with mucus in its passage through the urethra. In such an event the instrument must be withdrawn and cleansed.

CYSTOSCOPIC APPEARANCE OF THE NORMAL BLADDER.

With the bladder moderately distended *the surface of the mucous membrane* is smooth. Circumscribed nodular swellings appear late in life and are caused by the intersection of muscular bands—the so-called trabeculæ, which traverse the wall in all directions. Such nodular elevations are not to be mistaken for tubercular nodules. Between the trabeculæ, which cross one another at all angles, are irregularly shaped depressions. These are the forerunners of the pathological condition known as diverticula and hernia.

The color of the mucosa varies within wide limits. In the normal state this variation in color is found not only in different bladders, but in various portions of the same bladder. By reflected artificial light the normal color is gray or yellowish-rose. The variations in color presented at different points in the bladder are accounted for by the relative position of the prism to the field of vision. For this reason the shades of color change with the movements of the prism. The nearer the prism approaches the surface, the brighter the color. As the heat of the lamp warms the contained fluid, the mucosa shows a hyperæmic reaction.

The *bloodvessels* appear as a fine network of veins and arteries; the base of the bladder is more vascular than are other portions. With the exception of the field near the sphincter vesicæ, the veins are rarely seen in the normal bladder.

From a clinical point of view the most important parts of the bladder are the *trigone* and *base.* It is here that foreign bodies and pathological lesions are most often observed. The trigone presents a smooth, glistening surface, varying in color from gray to dark red, and contains a close network of capillaries.

As the cystoscope is slowly introduced the first image to greet the eye is that of the *sphincter vesicæ,* which appears in the upper or lower segment of the field of vision, depending upon the respective direction of the cystoscope; the image above is the lower

segment of the sphincter, and *vice versa.* Pushing the instrument forward the image is slowly lost to view. At the base of the bladder the *ligamentum uretericum* is seen as a ridge of more or less prominence, running transversely for a distance of about one inch. Turning the instrument slightly to the right or left the *ureteral prominence* is seen at the end of the ureteric ligament. The prominence varies in size, form, and color. This is often true of the two prominences in the same bladder. The image increases in size and transparency as the prism is moved toward the object, decreasing in size and becoming darker as the prism is withdrawn. It is important to look for small vessels radiating from the ureteral prominence, for at the point from which the vessels radiate the ureteral opening is found. It is often possible to see the ureteral openings in the centre or at one side of the prominence.

Difficulty in finding the *ureteral opening* is experienced when, as occasionally happens, the prominence is wanting. When one ureteral opening is found, the other is to be sought for at a corresponding point at the opposite extremity of the ureteric ligament. Slight variations in position are sometimes observed. One or both ureteral openings may be found close behind the sphincter vesicæ, or they may lie some distance beyond the boundaries of the trigone. When it is seemingly impossible to discover the position of the ureteral openings, it is well to quietly and patiently look for the ripple of the urine as it is discharged into the bladder from the ureters. When the ureteral openings are hidden from view by folds of mucous membrane, a greater quantity of fluid may smooth out the folds and present the ureteral openings to view.

Air-bubbles are usually present. It is impossible to avoid introducing them, but happily they are no embarrassment in the examination. They are round, oval, or hour-glass in form, and move together with the contained fluid.

Movements of the bladder are seen, and are ascribed to the respiratory excursions and to the movements of neighboring structures.

Salt deposits of a red or grayish-white color are found on the surface of the bladder under perfectly normal conditions. They are distinguished from pus and tubercles by their color, their sharp margins, and by the fact that they are a deposit upon and not an infiltration of the mucosa.

Small cystic elevations, the size of a pinhead, may extend over the entire surface of the bladder. They are particularly noticeable

near the sphincter vesicæ. No pathological significance is to be attached to them.

The KELLY-PAWLIK METHOD, when efficiently carried out, is the most satisfactory of all methods of cystoscopy. The fundamental principles of a cystoscopic examination as given by Kelly are :

1. The introduction of a simple cylindrical speculum into the bladder.

2. The atmospheric distention of the bladder, induced slowly by posture.

3. The illumination and inspection of the vesical mucosa, either by means of a direct light, such as a little electric lamp attached to the examiner's forehead or to the mouth of the speculum, or by means of a strong light reflected by a head mirror.

THE TECHNIC OF THE EXAMINATION. The field of operation, the instruments used, and the hands of the operator are to be sterilized as for an operation. The bladder and bowel should be emptied immediately before the examination.

FIG. 189.

Glass tube, with rubber catheter.

On account of nervousness on the part of the patient or unusual irritability of the urethra, chloroform anæsthesia may be chosen if not contraindicated. In the majority of cases no anæsthetic is required. Kelly recommends the application of a 10 per cent. cocaine solution to the urethra just within the external orifice. The application is made on a pledget of cotton wound on a metal rod. By this means the urethra can be dilated to the required degree without great suffering.

The Posture of the Patient. Kelly recommends the elevated dorsal and the knee-chest positions. While the *elevated dorsal position* is the most convenient and least fatiguing to the patient, it is not so efficient, because the bladder does not distend so perfectly as in the knee-chest position.

In the elevated dorsal position the hips are elevated from the table eight to twelve inches by firm pillows. The head and thorax rest on the table. As a preliminary measure to secure perfect dis-

Fig. 190.

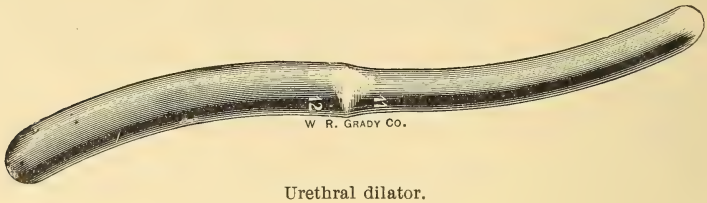

Urethral dilator.

tention of the bladder, the patient may assume the knee-chest position and a catheter be introduced into the bladder, through which

Fig. 191.

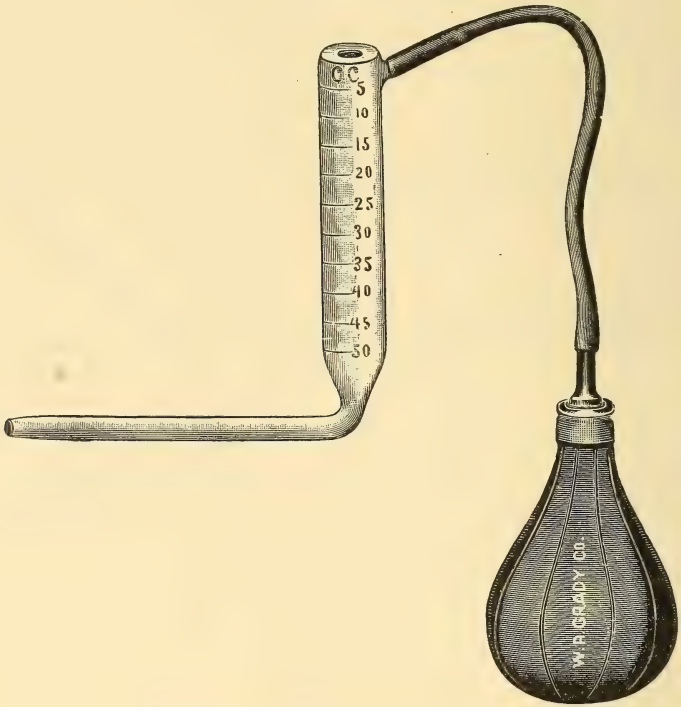

Glass graduate, with rubber tube and bulb.

the air may enter. In a minute or two the patient may resume the elevated dorsal position, taking care that the hips are constantly held at a higher level than the abdomen. By so doing the weight

of the small intestines is taken from the bladder and when the urethra is dilated the bladder will be perfectly distended.

FIG. 192.

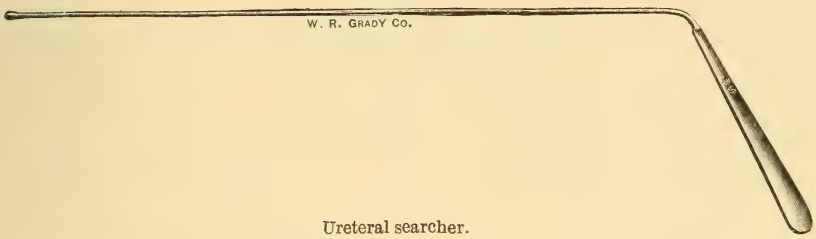

Ureteral searcher.

FIG. 193.

FIG. 194.

FIG. 195.



FIG. 193.—Ureteral catheter, with handle sufficiently reduced to allow speculum to be withdrawn after catheter is engaged in ureteral orifice.

FIG. 194.—Delicate mouse-toothed forceps.

FIG. 195.—Vesical curette. (KELLY.)

The *knee-chest position* is preferred by Kelly, who regards it as applicable to all cases. When the patient can endure the exertion no anæsthetic need be given. The patient kneels close to the edge

Fig. 196.

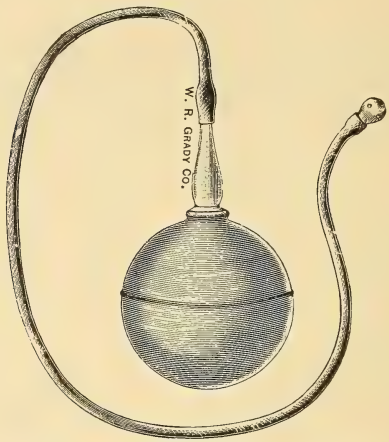

Evacuator used for withdrawing residual urine.

Fig. 197.

Cystoscope.

Fig. 198.

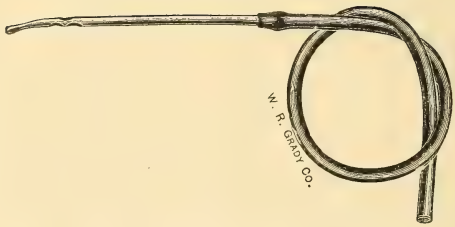

Ureteral catheters, with rubber tube.

of a firm table. The hips are kept at the greatest elevation, while the breast and side of the face lie flat upon the table. The small of the back curves inward. The knees are separated about twelve inches. Where an anæsthetic is required the body may be supported by an apparatus shown in Fig. 199, or by an assistant at either side.

Of immense advantage over the dorsal and knee-chest positions is the elevated lithotomy position as advocated by Webster in

FIG. 199.

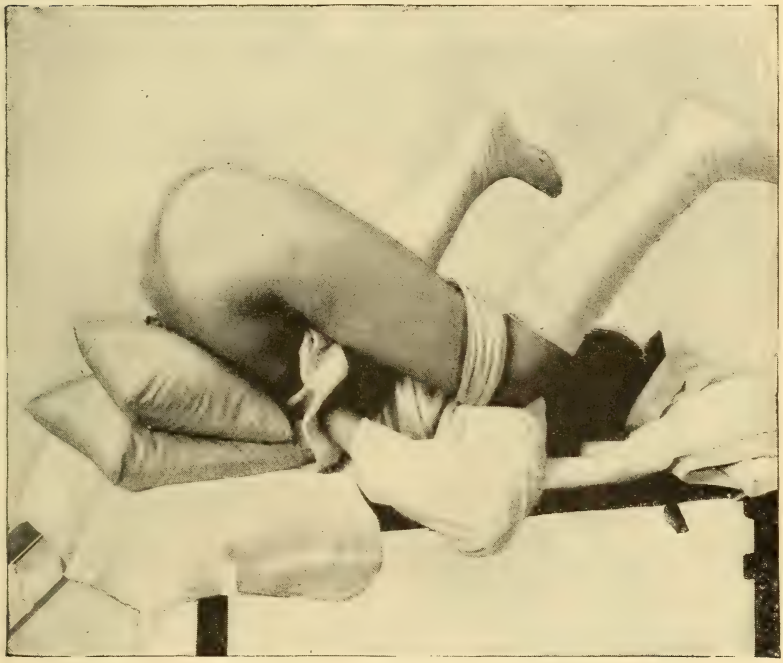

Dorsal position. Elevated pelvis. (KELLY.)

the *Journal of the American Medical Association*, May 17, 1902. During the past three years Webster has employed the following method :

" The patient is placed on a Bolt operating table in the lithotomy position, the ankles being fastened to upright rods, the buttocks projecting slightly over the end of the table resting on a rubber pad. A steel bar, with two padded supports, is attached to the top of the table so as to support the shoulders. After the external genitals and vagina are cleansed the patient is enveloped in sterile

sheets, the urine is withdrawn from the bladder, the urethra is dilated to the necessary size, and a speculum containing its obturator introduced into the urethra. By means of a crank the top of the table is turned on a transverse axis so that the lower end is elevated and the upper end depressed. The patient is thus made to rest on an inclined plane, being held by the shoulder supports, her trunk

FIG. 200.

Introducing searcher into left ureteral orifice. (KELLY.)

being flat against the table and not bent in any way, so that her respiration is free and the anæsthetic easily administered. The table-top is usually raised until its lower end is twenty-three inches above the normal level. The obturator is then removed from the speculum, allowing air to enter and dilate the bladder. The examination of the bladder and ureters is then carried out, the examiner standing on a stool so the eyes may be well above the outer end of the speculum.

"This posture has all the advantages of the genupectoral position and none of its disadvantages. In difficult cases in which the distention of the bladder has not been thoroughly satisfactory, I have

FIG. 201.

Bolt table for cystoscopic examination.

not been able to get better results by trying the genupectoral position."

Dilating the Urethral Orifice. The dilators are lubricated with boroglycerin and introduced into the urethra by a boring motion.

It is well to first calibrate the urethral orifice in order to select the proper size of dilator. The small end of the conical dilator is crowded into the urethra until it meets with resistance. The index finger is so placed as to mark the point in contact with the

Fig. 202.

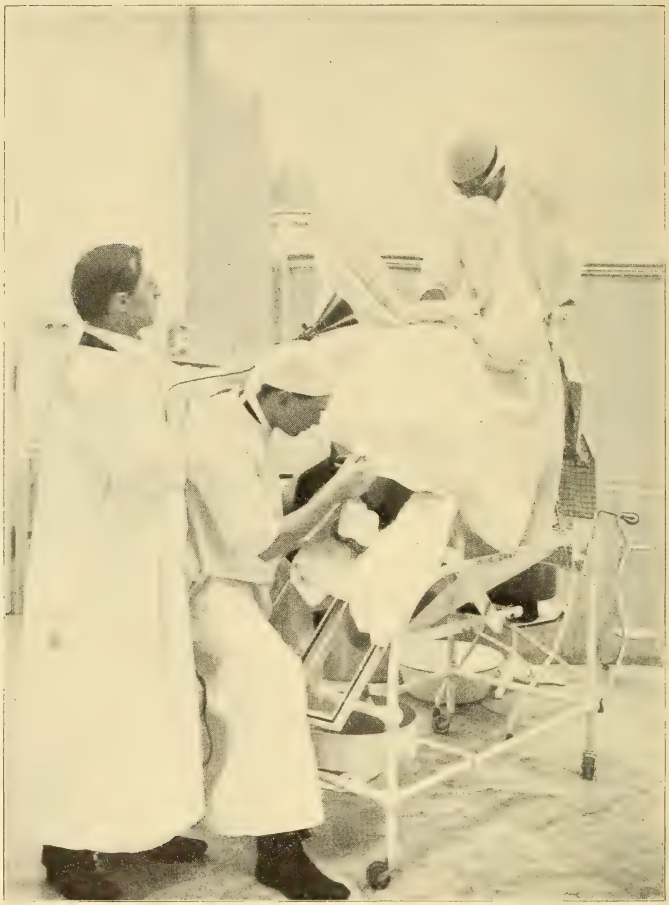

Cystoscopic examination. (Webster.)

urethral orifice. The dilator is withdrawn and the index finger is found to point to the number of millimetres. Anything below ten millimetres will probably require dilating. A dilator slightly less in diameter than the calibrator is chosen and larger dilators are

successively employed until the diameter of the urethra is increased to the desired degree. Where the orifice is unusually resistant and small, Simon suggests cutting it posteriorly.

FIG. 203.

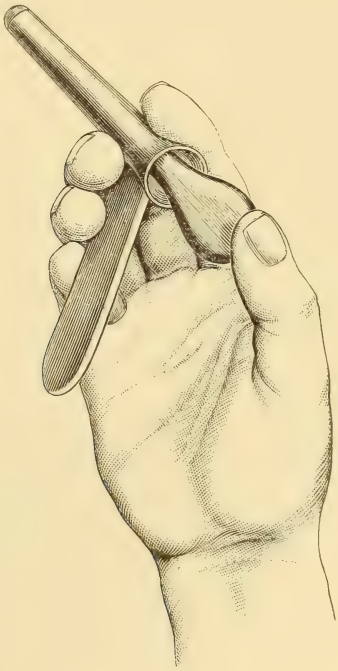

Hand holding cystoscope in act of introduction. (KELLY.)

INTRODUCTION OF THE SPECULUM.

The size of the speculum should vary from 7 to 12, according to the case. When the urethra is small and sensitive, No. 7 or 8 may best answer the purpose. With experience a No. 10 will be satisfactory in the majority of cases. The urethral orifice is cleansed with boric acid, an assistant holds the labia and buttocks apart, while the operator grasps the speculum, as shown in Fig. 202, and gently forces it through the urethra into the bladder. The obturator is held in place by the thumb until the cystoscope has entered the bladder, when it is withdrawn. A head mirror reflects the light from an electric drop lamp.

The interior of the bladder should be explored systematically, moving the speculum from side to side and up and down as the occasion requires.

The Segregator. By this ingenious instrument, first introduced by Harris, and modified by Downes, the urine is separately collected from each ureter as it passes into the bladder.

FIG. 204.

Knee-breast position. Cystoscope introduced; sound shows position of anal orifice (KELLY.)

Two catheters are arranged side by side within a flattened tube, each separate and movable on its longitudinal axis. When introduced into the bladder the catheters are rotated outward on their long axes and separated at the bladder end. A metallic lever introduced into the vagina of the female and into the rectum of the male provides a water-shed in the bladder, on either side

of which the urine is collected from the corresponding kidney. The urine flows through the catheters into bottles.

Fig. 205.

Downes' segregator.

The application of the segregator is simple and has the great advantage of collecting the urine from either kidney separately without catheterizing the ureters. However, it has not proven of universal value.

Fig. 206.

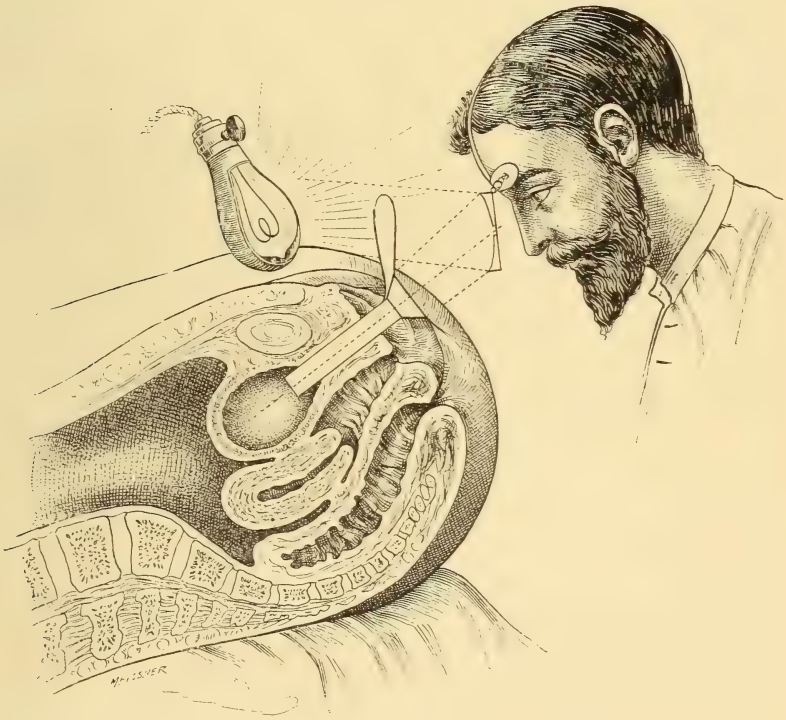

Kelly-Pawlik method of cystoscopy. The hips are elevated, the bladder is distended with air, the cystoscope is inserted into the bladder, and artificial light is directed through the cystoscope into the bladder.

MALFORMATIONS AND DISEASES OF THE FEMALE URETHRA.

I. **Congenital malformations of the urethra** are uncommon. They consist of partial or complete absence of the urethra, atresia, displacements, epispadias, and hypospadias.

1. **Partial or complete absence of the urethra** may occur in the presence or absence of other congenital malformations of the genito-urinary tract. All trace of the urethra may be wanting, in which case the bladder and vagina may form a single cavity.

2. **Atresia of the urethra** as a congenital defect is almost invariably associated with malformations of the bladder, vagina, and uterus. An outlet for the bladder is commonly found to communicate with the vagina or through the patent urachus to the navel. If no such communication exists the bladder, ureters, and kidneys will be widely distended.

3. **Displacements of the urethra** are very uncommon as a congenital defect, but are occasionally observed as an acquired one (*vide infra*).

4. **Epispadias**, including a defect in the upper wall of the urethra, a division of the clitoris, and a separation of the labia minora, is exceedingly uncommon. As associated defects may be mentioned separation of the symphysis and an exstrophy of the bladder.

5. **Hypospadias** is a defect in the lower wall of the urethra, thereby establishing a communication between the urethra and vagina.

II. **Acquired malformations of the urethra** are dilatations, strictures, diverticula, dislocations, and prolapsus.

1. **Dilatation of the urethra** may be confined to any portion of or involve all of the urethra. Dilatation of the entire urethra is usually the result of coitus or masturbation *per urethram;* more rarely from the presence of a new-growth and foreign bodies. The partial incontinence of urine following repeated labors is undoubtedly due to injury to the circular fibres of the urethra. Incontinence of urine is an almost constant accompaniment.

Local dilatation of the urethra, known as a urethrocele or diverticulum, affects the posterior wall of the urethra immediately back of the meatus. But few cases are recorded.

2. **Stricture** of the female urethra is uncommon as compared with men. The *causes* of these strictures are :

a. Cicatrization in the anterior vaginal wall following injuries through labor.

b. Chronic urethritis, usually of gonorrhœal origin, is the most frequent cause of stricture in the female as well as in the male.

c. Tumors of the urethral wall rarely constrict the urethra.

d. Tumors about the urethra and displaced uteri may directly constrict the urethra.

e. Cicatrization following a chancre.

f. Contraction of the urethra without an assignable cause.

The diagnosis is made from the difficulty and pain experienced in urinating and from the character of the flow, which comes in a fine stream or in drops. Not only the existence of a stricture but its size, exact location, and the calibre of the urethra are diagnosed by calibrating with bougies and by direct inspection through the urethroscope.

3. **Dislocations of the urethra** may occur in any direction, and such dislocations may involve the entire thickness of the urethral wall or merely the mucous membrane. Displacements of the urethra are not common, because of the anatomical relations. It is a short canal lying immediately underneath the symphysis and firmly embedded in connective tissue. Misplacement of the whole urethra is the usual occurrence and is almost invariably secondary to a displacement of the bladder, as commonly observed in a vesicocele. Inspection and the use of the sound demonstrate the exact position of the urethra. The external orifice is directed forward and upward and the internal orifice backward and downward. The urethral canal may be so distorted as to render the passing of a catheter or sound difficult. Great difficulty may be experienced in voiding the urine.

The urethra may be elongated and elevated by tumors which draw the bladder upward, by extreme distention of the bladder, and by the pregnant uterus.

4. **Prolapse of the urethral mucous membrane** results but rarely, and in patients who have long suffered from dysuria and vesical catarrh. Displacements of the uterus and anterior vaginal wall are frequent accompaniments. Near the urethral orifice the mucosa is loosened and is protruded from the urethral orifice as a pale red or bluish, annular, or crescent-shaped fold of mucous membrane. This condition may occur at any age, but is more common in girls of a generally weakened constitution.

Urethritis. In the female as in the male, gonorrhœa is the common cause of urethritis. In the absence of an established cause for

urethritis the lesion is assumed to be gonorrhœal in origin. Long after all clinical evidences of urethritis have disappeared, the gonococcus may inhabit the mucosa. Steinschneider examined thirty-four cases of recent gonorrhœal infection, and found the gonococcus in the urethra in all of them.

Sometimes the purulent secretion is seen to exude from the urethral orifice, but, as a rule, it is demonstrated by milking the urethra. So characteristic is a purulent discharge from the urethra and so seldom is it found in other than gonorrhœal infection, that it may be regarded as almost conclusive evidence of the gonorrhœal nature of the lesion. A cover-slip preparation of all secretions of the urethra should be made, and at the same time of any existing secretions from the cervix. If, as stated by Kelly, the gonococcus is found in the secretion of the cervix and not in the urethra, a complicating urethritis may be assumed to be also due to gonorrhœa. Suchanek found in 166 cases both the vagina and the urethra affected in 122 and urethral gonorrhœa existing singly in only 3 cases.

No effort will be made to make a clinical distinction between the hyperæmic and the inflammatory lesions of the urethra. They are dependent upon the same underlying causes and only differ in degree. Hence as additional causes which occasionally operate to bring about a congested or inflamed urethra may be mentioned diseases of the bladder and kidneys which extend to the urethra or in which the urine irritates the urethra. The mechanical irritation of the catheter and infections acquired by the use of unclean catheters are occasional sources. A urethritis sometimes complicates the infectious and contagious diseases. The wearing of an ill-fitting pessary, the habit of masturbation, and of excessive sexual intercourse may result in urethral congestion.

Urethritis is acute and chronic.

1. **Acute Urethritis.** In this stage it is well to limit the local examinations as far as possible. Under normal conditions the mucous membrane is pale red in color and there is a slight glairy secretion. In the acute inflammatory stage the mucosa about the urethral orifice appears red and swollen, sensitive to pressure, and secretes a variable amount of pus.

In acute gonorrhœal infection of the urethra there is at first a prickly, burning pain during and immediately following urination. Dysuria and frequent urination are constant symptoms. Three or four days later there appears at the urethral orifice a serous, sticky,

transparent secretion, which by the eighth day becomes greenish and purulent and continues so for about two weeks, when it decreases in amount, and by the end of the first month may have entirely disappeared. Vivid red points are often seen about the meatus which mark the mouths of infected glands. The discharge may cause an intense itching about the vulva. When it is desired to inspect the urethra a 10 per cent. solution of cocaine should be applied to the orifice by a swab before introducing the urethroscope. Slight bleeding will be caused by the instrument. The congested mucous membrane will not appear so reddened because of the pressure of the instrument.

2. **Chronic urethritis** exists as a diffuse and circumscribed lesion easily recognized through the urethroscope. The initial stage may be an acute infection, but more often it is chronic from the beginning. The secretion is limited; the mucosa is but slightly swollen and is of a livid blue color. There is little or no sensitiveness to pressure.

NEW-GROWTHS OF THE URETHRA.

New-growths of the urethra are more common in the female than in the male. The following forms have been described:

1. Caruncle.
2. Fibroma.
3. Carcinoma.
4. Sarcoma.

1. **Caruncle.** Vascular tumors of the urethra, the so-called caruncles, are most frequent. No age is exempt, but they are more common in advanced years. They are located at the urethral orifice, sometimes extending into the urethra. They are sessile or pedunculated, the form varying from flat and nodulated to pedunculated and crenated. The growth is very vascular, bleeding freely to the touch, and is sensitive to pressure. The orifice is covered with pavement epithelium. In the connective tissue stroma is an abundant distribution of nerve filaments and capillary bloodvessels, this supply of nerves accounting for the great sensitiveness to pressure and the pain in urinating. Sexual intercourse becomes intolerable, and the suffering racks the constitution.

The diagnosis can be made by direct inspection. Where doubt exists as to the character of the growth a microscopic section of the excised tumor should be made.

2. **Fibroma.** But few cases are recorded.

3. **Carcinoma** of the urethra is rarely primary, but is not infrequently secondary to carcinoma of the vagina, cervix, and vulva. I am able to find only twenty-eight cases of primary carcinoma of the urethra in the literature. The reported cases show a variety of anatomical forms: the papillomatous, nodular, smooth and infiltrating, and, finally, the ulcerative. Almost all arose late in life, as is common with carcinoma.

The patient complains of burning and smarting while urinating; later there is more or less bleeding. The endoscope should be used in all cases when complaint of such symptoms is made. When in doubt as to the character of the growth a portion may be excised or scraped from the suspected area and submitted to a microscopic examination.

4. **Sarcoma.** But four cases of primary sarcoma of the urethra have been described. One was a myxosarcoma, another a melanosarcoma.

URETHRAL FISTULA.

A fistula of the urethra leading into the vagina is a very unusual accident of labor. It is more often artificially induced in the treatment of dysuria (Emmet's button-hole operation).

Fig. 207.

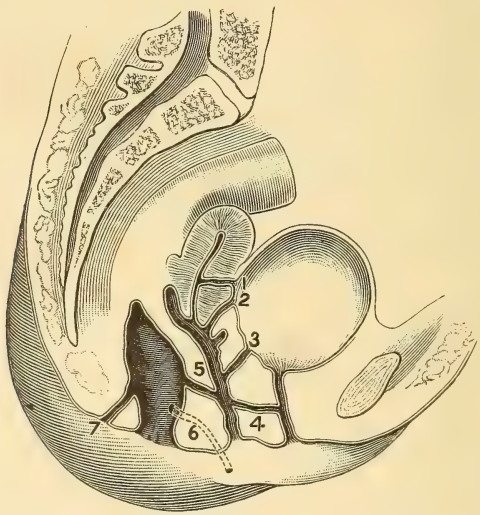

1. Vesico-uterine fistula. 2. Vesico-utero-vaginal fistula. 3. Vesicovaginal fistula. 4. Urethro-vaginal fistula. 5. Rectovaginal fistula. 6. Perineo-anal fistula. 7. Anal fistula. (Dudley.)

These fistulæ seldom assume large proportions, often no larger than a pinhead. They are usually located in the floor of the urethra ; those artificially induced are situated well forward, while those caused by labor are usually found near the sphincter vesicæ and may involve part of the bladder.

Foreign bodies in the urethra are rarely found. They are introduced from without in masturbating or in the passage of sounds and catheters, or a vesical stone may lodge in the urethra.

The diagnosis is based upon the complaints of frequent painful urination, the presence of pus, blood, and mucus in alkaline urine, and the finding of the foreign body by palpating the course of the urethra through the vagina, by sounding the urethra, and by means of the urethroscope.

Calculi in the urethra are almost invariably composed of phosphates.

DISEASES OF THE BLADDER.

The vesical diseases of women differ materially from those of men, and are deserving of special consideration. We will consider :

1. Developmental deformities.
2. Malpositions and malformations.
3. Foreign bodies.
4. Traumatisms.
5. Inflammations.
6. New formations.

1. DEVELOPMENTAL DEFORMITIES.

(*a*) **Vesical fissure** (exstrophy) is the most frequent and important of the congenital deformities of the bladder. It depends upon a deficiency of the anterior wall, and is mostly associated with developmental defects in the genital organs. Various grades of this maldevelopment are observed. It may consist of a simple cleft of the most dependent portion of the bladder or is less frequently located near the umbilicus. In the other extreme may be found an absence of the entire anterior wall of the bladder. A corresponding portion of the abdominal wall is cleft and the gap is filled with a swollen, red, mucous membrane continuous with the external skin. The pubic bones are separated one-half to three inches and are connected by a fibrous band. The urethra is usually wholly wanting and not

infrequently the clitoris is bifurcated. It is possible for the vagina and uterus to be divided by a septum, or for two separate vaginæ and a bicornuate uterus to exist in connection with the fissured bladder. At times the posterior wall of the bladder inverts through the abdominal fissure. According to Voss, a distended bladder in the fœtus accounts for these deformities. The distended bladder forces the horizontal rami of the pubes apart, then ruptures and establishes a communication between the bladder and the abdominal cleft.

The diagnosis is based upon direct inspection of the protruding bladder. The red mucous membrane of the bladder is sensitive to the touch, the ureteral openings may be visible, and urine may be seen dribbling from the ureters. The lower margin of the fissure is reddened, eroded, burning and itching from irritating urine.

As to frequency of occurrence, Winckel reports two observed cases, and Sickel found two cases in 12,689 newborn children.

(*b*) **Double bladder** is due to a failure of the two parts of the allantois to fuse in early fœtal life. But few cases are recorded.

(*c*) **Loculate Bladder.** Projections are sometimes seen on the outer surface of the bladder formed by diverticuli of the bladder wall. They are congenital defects, and are not to be confounded with diverticula of inflammatory origin. They have been mistaken for supernumerary bladders.

2. MALPOSITIONS AND MALFORMATIONS OF THE BLADDER.

The female bladder is subject to malpositions and malformations to a far greater degree than is that of the male.

The normal position of the bladder is in the median line. In moderate distention the greatest diameter is transverse, and in extreme distention the greatest diameter is the vertical. The distended bladder may incline considerably to the right or left of the median line and may reach the level of the umbilicus. The author recalls seeing in Vienna a postmortem examination of a patient in whom the bladder had been opened and stitched to the abdominal wall in the right lower quadrant of the abdomen. The bladder, which was greatly distended, lay to one side of the median line and was thought to be a broad ligament cyst. The mistake was discovered in the postmortem examination.

Elevation of the bladder occurs when the pelvis is filled with a tumor mass and when the uterus greatly enlarges and extends into the abdominal cavity, dragging the bladder with it even to the level of the umbilicus. When the elevated bladder is partly filled with urine it forms a protruding, fluctuating swelling in front of the tumor.

Downward displacement of the bladder (cystocele) is the most frequent malposition, and is the result of injury to the pelvic floor and of an increase in intra-abdominal pressure. It is most unusual for a cystocele to exist in a nullipara. Occupations which involve much standing and lifting predispose to cystocele, even in nulliparæ.

In slight degrees of descent the lower part of the bladder is somewhat sunken, and in extreme cases the bladder becomes shaped like an hour-glass, being divided into an upper and lower part by the urethra. In extreme grades associated with prolapsus uteri, the urethra may run vertically, the external orifice pointing directly upward. Virchow, Philips, Braün, and others have observed dilated ureters and hydronephrosis as the result of obstruction to the flow of urine through the stretched and twisted ureters.

The diagnosis is largely based upon the physical findings; the complaints of the patient will give but little clue to the diagnosis. There is a frequent desire to urinate, and this is associated with more or less pain. Advanced cases may continue with little or no disturbance of the bladder functions. A number of cases of cystocele have been reported in which the passage of the child was impeded. The patient, when she is first aware of the protruding vaginal wall, regards it as "falling of the womb."

With the patient in the lithotomy position the labia are separated and she is instructed to bear down. The anterior vaginal wall suddenly bulges into a rounded mass, which, if filled with urine, will fluctuate when grasped by the fingers. A metallic sound placed in the bladder will demonstrate the pouching of the bladder into the vaginal tumor.

When a cystocele is observed the examination is not complete until the position of the uterus, the conditions of the pelvic floor, and the urine are carefully determined, because malpositions of the uterus, injuries to the pelvic floor, and chronic cystitis are almost constantly associated with cystocele.

Eversion of the bladder through a dilated urethra is rarely observed. Before such an event can occur there must be a relaxed

bladder wall and a dilated urethra, which, together with an increase in the abdominal pressure, may produce the condition. A sound passed through the urethra will demonstrate the absence of the bladder. Reducing the protruding mass, the bladder is restored to its normal position.

Hernia of the bladder through the inguinal or femoral rings and through the foramen ovale have been observed.

3. FOREIGN BODIES IN THE BLADDER.

Winckel divides the foreign bodies found in the bladder into those that originate in the organ itself, those that come from other parts of the body, and those that are introduced from without.

(*a*) **Foreign bodies originating in the bladder** are in large part vesical calculi. Calculi may arise from the precipitation of urinary salts independent of the previous existence of a foreign body, or they may have as nuclei certain foreign elements introduced into the bladder from without or from the upper urinary tract. They are not so common in the female as in the male, because of the shortness of the urethra, the rarity of urethral strictures, and the readiness with which lesions of the female bladder are cured.

In 1792 cases of vesical calculi found in Moscow by Dr. Klein, only four occurred in women. In 10,000 women examined by Winckel from 1860 to 1884, only once did he find calculi in a woman. In 3500 autopsies done upon women in the Dresden City Hospital, stone in the bladder was found six times. These statistics speak for the infrequency of vesical calculi in women.

The calculi are usually lodged in the fundus immediately back of the trigone. Not infrequently they lie in the pouch of a cystocele.

In the only case observed by the author a cystocele was filled with about twenty stones varying in size up to that of a hickory-nut. These were found in a woman, aged sixty-five years. A fistulous communication had developed in the cystocele, and through it the stones were extracted.

The stones vary in number, size, color, consistency, and composition. They have been known as large as a child's head. Hugenberger removed one weighing three and one-half pounds. Hundreds of stones may be present at one time in the bladder. They are composed of phosphates, urates, oxalates, and rarely of cystin.

(*b*) **Foreign bodies in the bladder that originate from other parts of the body** are the oxalic and uric acid calculi coming from the kidney, the contents of ovarian cysts which have ruptured into the bladder (teeth from dermoid cysts have formed the nucleus of stone), the products of extra-uterine pregnancy following rupture of the gestation sac into the bladder, fecal matter from an ulcerated bowel, and echinococci.

(*c*) **Foreign bodies in the bladder introduced from without** are portions of catheters, sutures, hairpins, pessaries which have ulcerated through the vesicovaginal septum, toothpicks, and the like.

The diagnosis of foreign bodies in the bladder is based upon the patient's complaint of an irritable bladder; later, on the clinical evidences of cystitis, and, finally and conclusively, upon the finding of a foreign body within the bladder by palpation and inspection, or upon the spontaneous expulsion of the body.

If the body is large it may be palpated through the vagina. A sound passed into the bladder will often disclose the presence of a foreign body. By inspection of the interior of the bladder not only the presence of a foreign body is determined, but also the character, number, size, form, and exact location. Direct inspection is of special value where the stone lies in a diverticulum beyond the reach of the sound. Fine gravel, too fine to be detected by the sound, is also demonstrated by the cystoscope. Not only the presence of a foreign body, but the accompanying cystitis is recognized by the aid of the cystoscope. Irritation of the bladder by the foreign body may render the viscus too sensitive for a cystoscopic examination without general anæsthesia.

4. VESICAL FISTULÆ.

By means of a fistula a communication is established between the bladder and the vagina, uterus, or intestine.

(*a*) **A vesicovaginal fistula** is most often the result of traumatism during labor. Protracted parturition, in which the head firmly presses upon the vesicovaginal septum, destroys the vitality of the tissues and leads to a sloughing, with the formation of a permanent fistulous communication between the vagina and bladder. I have at the present writing a case under observation in which the vesicovaginal fistula was caused by direct violence during the attempted delivery of a child. It is seldom, however, that fistulæ are caused

by direct violence in the use of forceps. More often, as Kelly puts it, "they are due not to the use of forceps, but to the too long delay in using them."

Carcinomatous invasion of the vesicovaginal septum is second in point of frequency. Other causes are vesical calculi, injuries sustained in vaginal operations, and ulceration from the pressure of an ill-fitting pessary. Forced catheterization during labor may perforate the bladder. Finally, pelvic abscesses may perforate both into the bladder and vagina, thereby forming a vesicovaginal fistula.

Fig. 208.

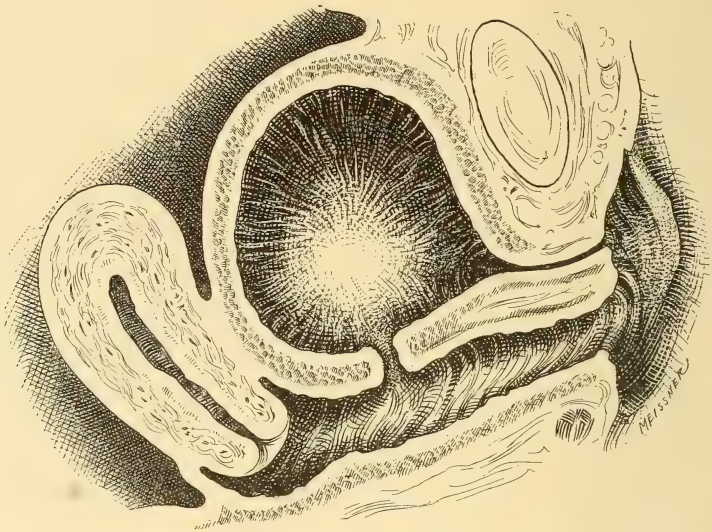

Vesicovaginal fistula. A communication is established between the base of the bladder and the vagina at a midpoint in the anterior wall of the vagina.

The *diagnosis* of vesicovaginal fistula is made by the history of a possible cause, the complaint of incontinence of urine with its disagreeable consequences, and, finally, by direct inspection.

It is unusual for a fistula developing after labor to manifest itself before the end of the first week, though it is possible for urine to escape through the vesicovaginal septum during labor.

The symptoms are quite characteristic. Before the urine escapes through a fistula there are usually symptoms of cystitis, bloody urine, and rise of temperature. A foul-smelling vaginal discharge indicates the sloughing of the vaginal wall, and this is soon followed by a dribbling of urine into the vagina. The vagina, vulva,

perineum, and inner aspect of the thighs soon show the irritating effect of the urine in the form of vulvovaginitis and local dermatitis. The distress and inconvenience of the dribbling lowers the vitality of the patient, and she may become extremely weak and emaciated. Such individuals are almost invariably sterile. Menstruation may be absent, irregular, or painful, but may also be perfectly normal. When the fistula is high up and small, the disturbance may be slight and the general health unimpaired.

Difficulty in voiding urine, following labor, should always suggest the possible development of a urinary fistula. Under such circumstances it is well to avoid vigorous manipulation for fear of creating or extending a fistula in tissue already devitalized.

FIG. 209.

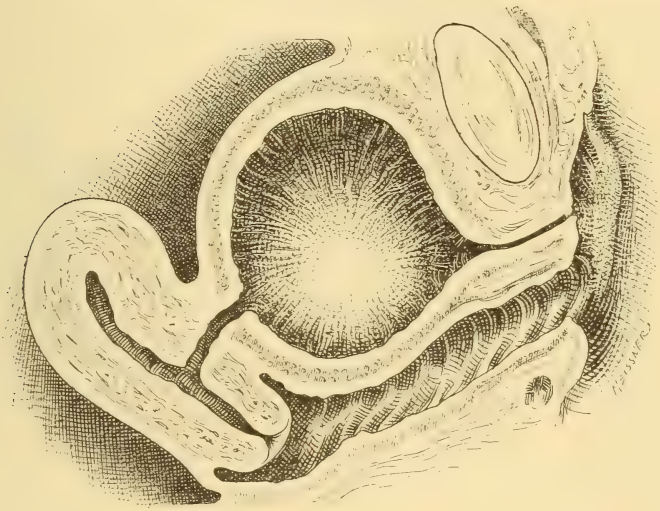

Vesico-uterine fistula. A communication is established between the fundus of the bladder and the uterus at about the level with the internal os.

Palpation of the fistula seldom affords satisfactory information when the tissues about the fistula are soft and necrotic. This is particularly true of a small opening. In long-standing cases the puckered scar tissue and an opening possibly filled with soft mucous membrane may often be recognized.

A sound placed in the bladder and the index finger of the opposite hand in the vagina may be brought together through a fistulous opening.

Inspection will give positive information as to the location and

size of the fistula. A Sims speculum introduced into the vagina will expose the fistula if large enough. Sterilized milk or some colored aseptic fluid injected into the bladder may be seen to flow through the fistula. The cystoscope will expose the opening from the vesical side, and at the same time afford information respecting the condition of the bladder—whether cystitis exists and foreign bodies lie within.

Having established the diagnosis of vesicovaginal fistula, it becomes important to consider the nature of its borders, their fixation, tension, and the possible existence of other fistulæ.

Fig. 210.

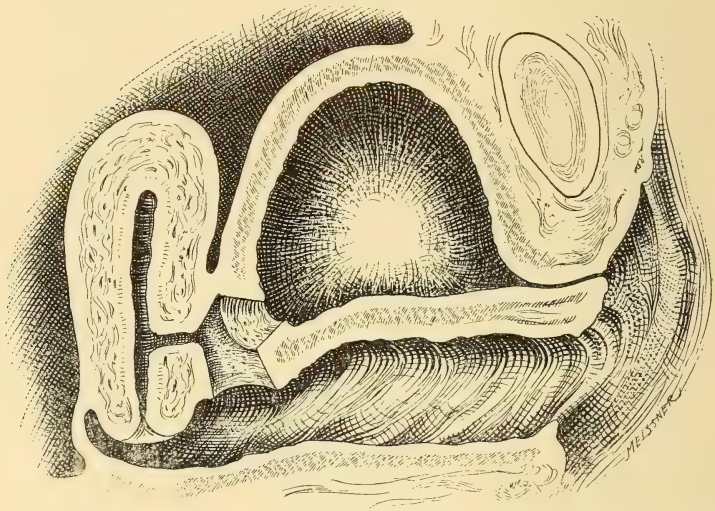

Cervico-vesico-vaginal fistula. A communication is established between the cervical canal vagina, and bladder.

(*b*) **Vesico-uterine Fistula.** When a laceration of the cervix extends into the lower uterine segment and the adherent bladder, it is possible for healing to be complete in the lower portion of the wound, leaving a fistulous opening above between the uterus and bladder.

The urine may be discharged in part through the cervix and in part through the urethra, depending upon the size of the fistulous opening and the position of the patient. To demonstrate a communication of the bladder with the uterus, inject sterile milk or sterile-colored fluid into the bladder and observe through a speculum that the fluid escapes from the cervix. To demonstrate that it is

not a uretero-uterine fistula observe that the flow of urine from the cervix is not intermittent. Catheterizing the ureters will demonstrate them to be intact.

(*c*) **Vesicocervical Fistula.** Likewise in extensive lacerations of the cervix involving the supravaginal portion and the base of the bladder a fistulous communication between the cervical canal and the bladder may persist. Such fistulæ are demonstrated in a manner similar to that indicated in vesico-uterine fistula.

5. CYSTITIS.

Cystitis is an inflammatory lesion of the bladder due to invasion of the walls of the bladder by pathogenic micro-organisms.

Etiology. In 2500 postmortem examinations of women, cystitis was found sixty-eight times (2.7 per cent.).

Virchow holds that the urine must first become ammoniacal, and by its irritating effects cause the epithelium to become loosened before bacteria can gain a lodgement in the bladder wall. Under apparently normal conditions the urine may contain bacteria, hence there must exist a predisposing cause for cystitis before the bacteria manifest their pathogenic properties.

As predisposing causes of cystitis may be mentioned congestion due to overdistention of the bladder, the presence of foreign bodies in the bladder, structures crowding upon the bladder from without (displaced uteri, pelvic exudates, and tumors), traumatisms sustained in labor and surgical operations, the passage of catheters and sounds, ill-fitting pessaries, the irritating influence of internal remedies, of fluids injected into the bladder, and of toxins developed within the body in the course of infectious diseases and intestinal disturbances. Congestion of the bladder from any of the above-named causes will prepare the tissues for invasion by pathogenic micro-organisms.

The micro-organisms found in the inflamed bladder are the staphylococcus pyogenes aureus, albus, and citreus; streptococcus pyogenes, bacillus coli communis, gonococcus, bacillus tuberculosis, bacillus typhosis, and numerous micro-organisms of lesser clinical importance, as, for example, the bacillus aërogenes capsulatus of Welsh, diplococcus ureæ pyogenes, cocco-bacillus, urea pyogenes, and the urobacillus liquefaciens.

Not infrequently two or more of the above-named bacteria are found in the same case. There is a condition known as *bacteriuria*,

in which the urine swarms with bacteria in the absence of any considerable amount of pus or other foreign elements.

The avenues by which these micro-organisms enter the bladder are :

1. The *urethra*, the most common of all. Micro-organisms which always exist in large numbers in the urethra, vagina, and vulva may be carried by instruments through the urethra and into the bladder. It is possible for bacteria to pass through the urethra into the bladder without the introduction of instruments. This is notably true of the gonococcus.

2. The *kidney*, when infected, may involve the bladder through the medium of the urine. It has been demonstrated that the urine may convey pathogenic micro-organisms to the bladder and there cause an infection without deranging the kidney.

The colon bacillus and tubercle bacillus probably most often gain access to the bladder from the blood by way of the kidney.

3. The *bowel*, when adherent to the bladder, may transmit the colon bacillus and other micro-organisms to the viscus.

4. *Inflammatory areas* surrounding the bladder and intimately connected with it may be the sources of infection, as, for example, pelvic abscesses, suppurating dermoid cysts, pyosalpinx, and perityphlitic abscesses.

5. *Hæmatogenous* infection of the bladder is an infrequent mode, though fully demonstrated.

The following summary is from Kelly :

1. Cystitis is always caused by the presence of bacteria.

2. The mere presence of bacteria is insufficient to cause a cystitis ; a further predisposing cause is necessary.

3. There are various modes of entrance for bacteria : through the urethra, through the ureter from the kidney directly, from inflammatory areas in the uterus or Fallopian tubes, and probably from the rectum under similar conditions ; still another probable avenue of entrance is through the blood.

4. Under favorable conditions any pathogenic organism may give rise to cystitis.

Anatomical Diagnosis. With the exception of the tubercle bacillus the anatomical changes do not differ essentially in the various kinds of infections.

Kelly classifies cystitis as diffuse, circumscribed, and scattered, and calls attention to the important and often overlooked fact that

PLATE XLII.

Figure 1. Cystitis originating in the Trigone and extending to adjacent surfaces. Magnified.

Figure 2. Normal Bladder Mucosa. Magnified.

PLATE XLIII.

Figure 1. Linear Ulcer of Bladder Mucosa. Magnified.

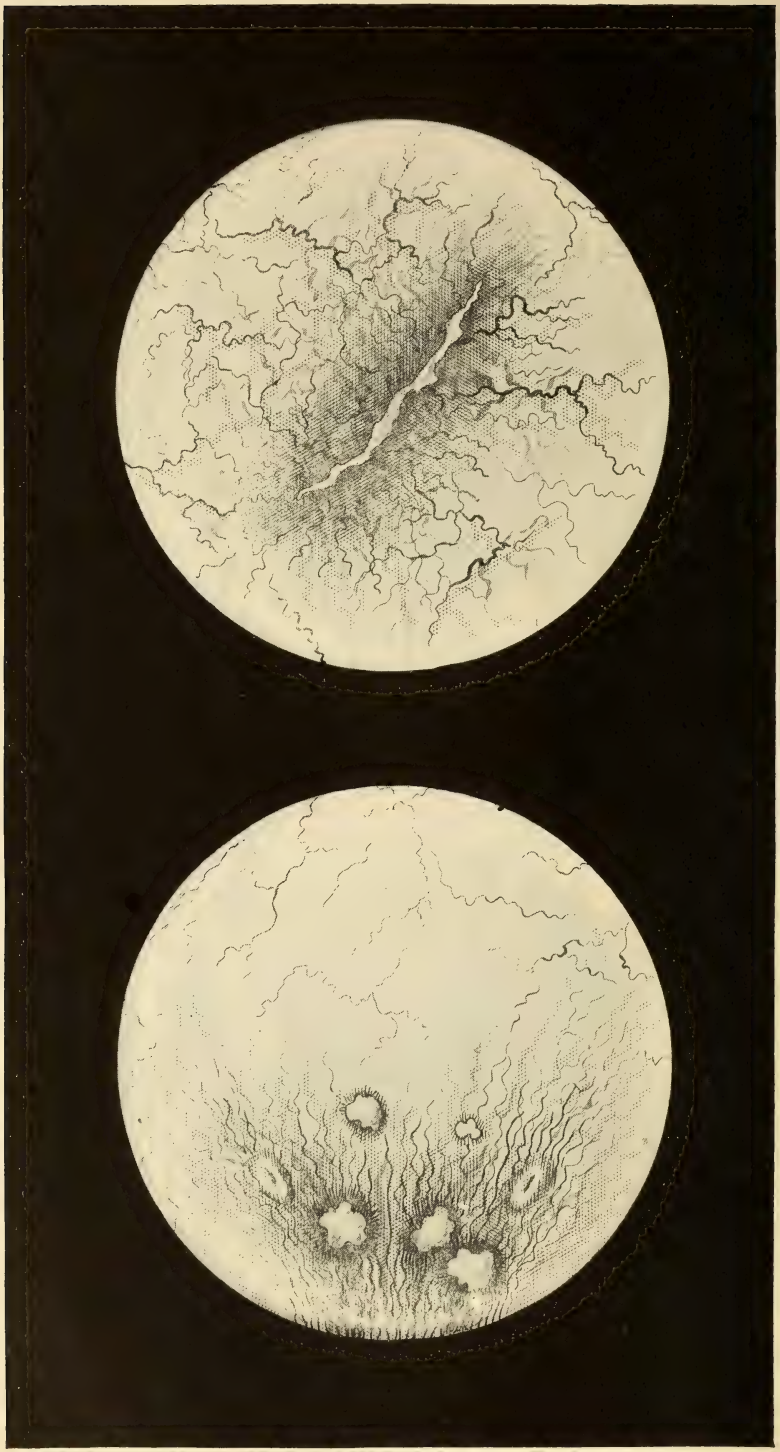

Figure 2. Ulcerated Patches in the Trigone. Magnified.

cystitis is not always a disease of the entire mucosa of the bladder, but is more often found in patches with normal mucous membrane intervening. This fact speaks for the efficacy of direct applications to the involved areas rather than to the entire surface by injections.

Both acute and chronic lesions are recognized.

In acute cystitis the bloodvessels are prominent, causing a swelling and reddening of the mucosa ; small hemorrhages are frequently seen.

In the chronic stage the reddening is less intense; the mucosa appears grayish and is thrown into folds. Papillomatous elevations may appear on the surface, and over the surface may be a deposit of pus, degenerated epithelium, micro-organisms, and salts, forming a false membrane which adheres rather firmly to the mucosa.

In cases of long standing the muscular wall of the bladder may be involved, being greatly thickened and giving rise to trabeculæ of muscle bundles intersecting at various angles. Abscesses may develop in the wall, and superficial ulcers are not infrequently seen on the mucosa. The entire mucous membrane may be thrown off in the so-called exfoliative cystitis.

Clinical Diagnosis. Frequent painful urination characterizes cystitis. The voiding of urine affords very little relief in the marked cases. The patient may suffer from a constant desire to urinate. The amount of urine voided may be no more than a few drops, and this may be passed every few minutes. It is possible for cystitis with marked changes to exist in the bladder wall without seriously disturbing the functions of the bladder. The temperature and pulse are seldom influenced unless the urethra or kidneys are involved. The bladder is tender to pressure, and an attempt to catheterize the bladder or to pass the sound into it causes suffering, and should not be done without local or general anæsthesia.

The diagnosis is made from a history of the above symptoms, from an examination of the urine, and from direct inspection. The urine is usually alkaline in reaction, though sometimes acid, and contains albumin, pus, bladder epithelium, crystals of triple phosphates, a variety of micro-organisms, membranous shreds, and occasionally some blood. When the bacteria are found in pure culture or vastly predominating over other forms they are the probable cause of the infection. The presence of the gonococcus or the tubercle bacillus in the urine is conclusive evidence of the true underlying cause.

The clinical distinction between the acute and chronic forms of cystitis is in duration and in the intensity of the symptoms. They are dependent upon the same underlying causes.

The cystoscopic diagnosis of cystitis is often difficult and may be impossible, but, as a rule, the results are readily obtained and are conclusive. In acute cystitis the difficulty arises from the pain caused by the manipulation of the instrument. Unless the indication is urgent no cystoscopic examination should be made, and then only under anæsthesia.

Local anæsthesia at the neck of the bladder may suffice. When possible to delay the examination the patient should be confined to her bed and sitz baths, diluent drinks, and sedatives administered. Chronic cystitis may present equally great difficulties because of the contracted bladder and the deposit upon the bladder wall.

Acute cystitis is recognized through the cystoscope by the prominence of the bloodvessels in the mucosa. This congestion of the mucosa presents a variable shade of red, having an irregular distribution over the surface. The more acute the inflammation the deeper the color. Hemorrhages into the mucous membrane are seen varying in size from a pinhead to a pea, and in color from bright red to almost black. They are most often located near the mouths of the ureters, but may be found at any point in the mucous surface.

Chronic cystitis presents a paler surface of a grayish color; the bloodvessels are faintly traceable; hemorrhagic areas are darker and smaller than in the acute stage. The surface has lost its lustre and presents an irregular appearance. The folding and swelling of the mucous membrane may hide the mouths of the ureters, and be so enormous as to suggest the possible presence of a new-growth.

There may be no secretion, and, again, the secretion may be so abundant and tenacious as to resist all efforts for removal by irrigating. Accumulations of the secretion may be mistaken for new-growths. Trabeculæ and diverticula are often seen in cystitis, and are largely confined to the inflamed areas.

Tuberculous Cystitis. It is not sufficient to merely diagnose cystitis and to distinguish between the acute and the chronic forms, but it is of the greatest importance to recognize, as far as the present methods of examination will permit, the bacteriological factors involved. This is particularly true of gonorrhœal and tuberculous

cystitis, since the organisms causing these lesions are well known and we are in possession of the means of detecting them.

Tuberculosis of the bladder is caused by infection through the blood, by extension of a tuberculous process from the kidney, the genital organs, or peritoneum. The lesion is more often found in early and middle life, and is more frequent in the male than in the female. It may be the primary infection in the bladder, or other micro-organisms may have previously invaded the bladder. A mixed infection is common. In tuberculosis of the kidney it is possible for tubercle bacilli to pass through the bladder in the urine for years without infecting the bladder. As in other forms of infection, the healthy, intact mucous membrane resists the invasion of the micro-organisms.

The ureteral openings and the trigone are the most common seats of tuberculosis. Grayish tubercles are seen to stud the mucous surface, and are usually in groups. Later the tubercles coalesce and form cheesy masses, which in turn break down into lenticular ulcers with a flat base and sharp, undermined, ragged borders within which small tubercles are seen. The ulcers may perforate the bladder wall and form fistulous tracts leading to the paravesicular tissue, rectum, and vagina.

The diagnosis is based upon the clinical evidences of cystitis, associated with the presence of tuberculosis elsewhere in the body, particularly in the kidney, upon the bacteriological examination of the urine, the cystoscopic appearance of the bladder, the microscopic examination of excised pieces and scrapings removed from the bladder through the cystoscope or a fistulous opening, and upon inoculation experiments. Unimpaired general health does not exclude the possible presence of tuberculosis. Renal tuberculosis may closely resemble vesical tuberculosis. Only by microscopic examination and inoculation experiments with catheterized specimens of urine is it possible to exclude renal tuberculosis. Careful and repeated examinations may be required.

HYPERÆMIA OF THE BLADDER

Hyperæmia, irritable bladder, and neuralgia are terms in common usage, and imply a disturbance of the bladder functions with vascular congestion of the mucosa. This hyperæmia may be diffuse, but is more often confined to a definite portion of the bladder, particu-

larly to the trigone. The involved areas are red, swollen, and tender to the touch of an instrument. There is no possible way of distinguishing such a condition from a mild, localized cystitis. The symptoms are identical. Hyperæmia of the bladder should be diagnosed without difficulty by a cystoscopic examination.

6. NEW FORMATIONS OF THE BLADDER.

Tumors of the bladder are more rarely found in the female than in the male. Nearly every variety of tumor, both benign and malignant, is found in the bladder. Of the benign tumors there are myoma, fibroma, papilloma, adenoma, and dermoid cysts, and of the malignant tumors carcinoma and sarcoma.

Fere has shown the places of predilection of tumors in a table constructed from the reports of 107 cases. In the 107 reported cases, 25 were found in the base of the bladder, 17 in the posterior wall, 13 in both the base and walls, 8 close to the left ureter, 5 near the right ureter, 2 in the anterior wall, 1 in the anterior and superior wall, 12 were multiple, and 8 diffuse.

More than half the tumors of the bladder are single.

Myoma originates from the muscular wall of the bladder, and is composed of smooth muscular fibre and a limited amount of connective tissue. The tumor is sessile or pedunculated. But few cases are reported.

Fibroma usually appears as a fibrous polyp with a long, slender pedicle. The tumor is composed of fibrous tissue. They are rare.

Papilloma of a benign character protrudes into the cavity of the bladder as a wart-like growth, with villous projections on the surface of the tumor. In the place of villosities there may be nodular projections. They are vascular, bleeding freely to the touch. A single tuft may be found on the trigone or the entire inner surface of the bladder may be covered. Its growth may be slow, extending over years with but little increase in size. The tumor is rarely so large as a child's fist, and is to be regarded as the most common of the tumors of the bladder.

Adenoma of the bladder is a rare new formation of epithelial origin. It is sessile or pedunculated, and seldom attains a large size. The histogenesis of the growth is uncertain.

Dermoid cysts of the bladder have been recorded by Paget and Boucher. Their existence has been questioned. Cases are not

wanting in which a dermoid cyst of the ovary has discharged its contents into the bladder and there formed a nucleus for vesical calculi.

Carcinoma of the bladder is primary or secondary. In secondary carcinoma the primary seat of the lesion is usually in the cervix, having spread thence to the bladder by continuity of tissue. It exists as a vegetating villous growth or as a diffuse infiltration, and is usually multiple. It bleeds freely to the touch and is exceedingly friable. Ulceration quickly follows upon infiltration, and there is a peculiar tendency on the part of the growth to remain localized for a surprisingly long time. Secondary growths are frequently found near the primary lesion.

Sarcoma appears in the female bladder more frequently than in the male, and is found at any period of life from childhood to the postclimacteric period. These growths are said to be prone to extend through the urethra and to appear at the vulva.

The diagnosis of tumors of the bladder is determined by palpation and inspection. The clinical signs in the early stage are about the same, whatever the character of the growth. All show more or less tendency to bleed. Hemorrhage is the most characteristic symptom. The bleeding is increased during the period of menstrual congestion, and has been observed to be greatest in the night. Pain may be present in the benign as well as in the malignant growths, though seldom to so great a degree, but is strangely absent in many cases. Late in the course of the lesion emaciation and cachexia develop in cases of malignant growths, and serve to distinguish these from benign new formations.

Examination of the urine is of little value in distinguishing tumors of the bladder from calculi or cystitis. Evidences of cystitis will usually be found in the urine, but this is not invariably the case even in the presence of large tumors of long standing. On the contrary, the bladder wall may present a normal appearance or may be anæmic. The loss of blood may be so great as to produce a high degree of anæmia and exhaust the strength of the patient. The presence of cylindrical cells in the urine is regarded by some authorities as conclusive evidence of the existence of a papillary growth.

Palpation reveals the presence of a foreign growth if it is sufficiently large. It may be possible to detect infiltration by a malignant growth in the neighboring tissues. Two fingers inserted into

the vagina and the other hand on the abdomen may engage the tumor. A soft, pedunculated growth may elude detection by this method. Such soft, pedunculated growths and all small tumors can be detected only by a cystoscopic examination. Direct palpation of the tumor through the urethra is an obsolete method.

Direct inspection gives positive evidence of the presence of a tumor, of its size, form, color, and location, of the number of growths, whether pedunculated or sessile, ulcerated or intact; also, as to whether there exists a cystitis and the extent of the inflammatory complications. Through the speculum a piece of the growth may be removed for microscopic examination.

CHAPTER XXXIII.

THE DIAGNOSIS OF THE DISEASES OF THE URETERS.

Anatomy. The ureters lie behind the abdominal and pelvic peritoneum and are slightly movable, flattened cords, extending from the kidney to the bladder. Under normal conditions they run symmetrically in an irregular, curved course on either side. The average length is ten to twelve inches, the left being slightly longer than the right because of the higher position of the left kidney.

There is no variation in the diameter of the ureter except at either end, where it distends above into the funnel-shaped pelvis and below into the ureteral prominence. The average diameter is 5 mm.

The ureters are traced through the pelvis in a sigmoid course. They lie close to the posterior lateral wall of the pelvis beneath the peritoneum and near the internal iliac artery. From this point they turn forward, passing underneath the uterine artery at the base of the broad ligament half-way between the cervix and the pelvic wall. They then run parallel to the upper anterior vaginal wall and enter the bladder at the upper angle of the trigone. Through the bladder wall the ureters run obliquely forward and inward.

The course of the abdominal portion of the ureter, including that part running from the kidney to the brim of the pelvis, passes forward in a curved direction over the psoas muscle to the brim of the pelvis. The ovarian veins and artery join the ureter at a mid-point in its course through the abdomen. On the left side it lies behind the colon above and the sigmoid below ; on the right side it lies behind the caput coli and the ascending colon.

Physiology. The ureters are not merely passive in conveying the urine from the kidney to the bladder. A peristaltic wave travels from above downward two or three times each minute, imparting to the ureters a vermicular movement and forcing the urine onward.

Methods of Examination. Four methods of examining the ureters are in general use—palpation, inspection, catheterization, and sounding.

Palpation. It is possible to palpate the pelvic portion of the ureter through the vagina and rectum. The abdominal portion of the ureter cannot be palpated without making an incision into the abdomen or lumbar region.

In palpating the pelvic portion of the ureter the bladder and rectum must be empty, all clothing constricting the waist must be removed, and the patient placed in the lithotomy position.

The index finger is inserted high in the vaginal fornix near the side wall of the pelvis. Stroking the vaginal wall downward and backward, the ureter is felt as a slender cord which slips away from the finger. That portion leading from the base of the broad ligament to the bladder is most easily felt. The size, consistency, mobility, and direction of the ureter serve to identify it in a vaginal examination.

The tendinous arch of the levator must not be mistaken for the ureter, nor must the obturator vessels and nerve. Only when the abdominal walls are extremely thin can the ureter be palpated at the pelvic brim about one and one-quarter inches to the right or left of the promontory of the sacrum.

When the ureter is diseased the line of tenderness will serve as a guide.

Through the empty rectum and preferably under anæsthesia, the ureter can be traced through the pelvis, the left being more accessible than the right. Guided by the pulsations of the internal iliac artery beginning at the bifurcation of the common iliac and tracing downward, the finger detects a flat, yielding cord running downward and forward. The larger and more resisting the ureter, the more easily is it palpated.

A catheter or bougie placed within the ureter to serve as a guide will facilitate the outlining of the ureter.

Inspection. No portion of the ureter can be inspected without an incision except that portion lying in the bladder wall which is recognized through the cystoscope as the ureteral prominence. With the abdomen open the lower abdominal portion and the upper pelvic portion may be inspected by drawing the sigmoid toward the median line. It is possible to lay bare the abdominal portion of the ureter by a lateral incision, drawing the ascending or

descending colon to the median line. In this way the peritoneal cavity is not opened. The ureter is found lying upon the psoas muscle.

Catheterization. Both palpation and inspection are of minor importance as means of investigating the ureters. Little can be positively demonstrated by these methods. By the ureteral catheter we may diagnose to a certainty the patency of the ureter, the existence of ureteral calculi, foreign growths, strictures, hydro-ureter, pyo-ureter, and many of the lesions of the kidney to be considered later.

The urine from either kidney is collected without mixing with that of the opposite kidney or with the foreign elements in the bladder and urethra.

By the Nitze method the catheter is introduced through a canal in the instrument. The usual technic of a cystoscopic examination is carried out.

In the Kelly-Pawlik method and preferably in the elevated lithotomy position, as advised by Webster and Pryor, the catheter is directed through an endoscope after a thorough inspection of the bladder. In this method the instruments employed are a conical urethral dilator, obturators, specula ranging in size from 8 to 10, head mirror, natural or artificial light, an evacuator, searcher, long, curved mouse-toothed forceps, and a flexible ureteral catheter. For special purposes there may be added hard-rubber bougies, a metal ureteral catheter, and a series of dilating catheters. After thoroughly inspecting the bladder as advised by Kelly the ureteral orifices are located by what is called a searcher. When no difficulty is experienced in locating the ureteral orifice or prominence the searcher may be dispensed with and the catheter at once directed to the ureter. A metallic searcher is made to lightly impinge against the mucous membrane in the supposed location of the ureteral orifice. No force is to be used for fear of perforating the bladder.

The searcher separates the lips of the orifice, which now present a dark, rounded opening, and is allowed to drop into the ureter by its own weight. It serves as a guide to the catheter, which is directed to the ureteral orifice. As the catheter enters the ureter the searcher is withdrawn by an assistant.

A flexible catheter has many advantages over one made of metal or non-flexible rubber. It readily follows the course of the ureter

to the pelvis of the kidney, and there is little danger of injuring the ureter. When it is desired merely to catheterize the ureter without entering the pelvis of the kidney a shorter catheter may be employed, one measuring twelve inches, whereas, it would require a catheter twenty inches in length to extend to the kidney. It is essential that the catheter have a perfectly smooth surface and a blunt, rounded end with an oval eye near the tip. A wire stylet is required to give stiffness to the catheter as it is forced through the ureter.

Where the bladder can be inspected without an anæsthetic it is usually possible to introduce a catheter without causing great discomfort.

It is important to thoroughly sterilize the catheters both before and after using. All foreign particles must be removed from the lumen of the catheter. This can be done by means of a stylet and by forcibly injecting water through the catheter. They should always be kept straight, for when allowed to roll up the varnish cracks and chips off. When both ureters are to be catheterized the speculum is withdrawn and reinserted beside the first catheter. When one ureter is catheterized and there is difficulty in passing a catheter into the other ureter, a fairly accurate method of separately collecting the urine is found in completely emptying the bladder, after which a large catheter is placed in the urethra. All urine collecting in the bladder while the ureteral catheter is in place is assumed to come from the opposite kidney, and especially is this true when the separate collections differ in character.

When, on account of an infected bladder, it is inadvisable to pass a catheter into the ureters, Kelly advises collecting a few drops of urine directly from the ureteral openings. This amount will serve for a microscopic examination. When the ureter is tortuous or the calibre is constricted, it may be impossible to introduce a flexible catheter. Here a metal catheter will be of service, but must be used with caution for fear of injuring the ureter.

Bougies made of hard rubber, two millimetres in diameter and twenty inches in length, are of service in locating ureteral calculi and in dilating strictures in the pelvic portion of the ureter. It is possible to push the bougies into the pelvis of the kidney without inflicting injury. A bulbous enlargement is placed about seven millimetres back of the point. These bulbs vary in size from a little more than the diameter of the instrument to four millimetres.

Kelly has ingeniously devised a wax tip for the bougies, by which he is enabled to locate calculi in the ureter and pelvis of the kidney. Longitudinal grooves are made on the sides of the tip for the purpose of retaining the dental wax. A silk renal catheter tipped with wax will serve the purpose equally well. The scratch marks made by the calculi are seen under a low magnifying glass. Where the X-ray fails to detect the stone it is often possible to locate it by wax-tipped bougies.

Kelly gives the following summary in a recent article on "Scratch Marks on the Wax-tipped Catheter in the Diagnosis of Stone in the Kidney or Ureter:"

(*a*) The scratch marks afford a valuable confirmation of the findings of the X-ray plates.

(*b*) The wax-tipped catheter serves to distinguish phleboliths about the vault of the vagina and in the pelvic veins from ureteral calculi.

(*c*) In the cases of stout women, where the X-ray findings are unsatisfactory and the repeated use of the X-ray is dangerous.

(*d*) In cases of uric acid and uratic calculi, where the X-ray shadow is faint, leaving doubt as to the diagnosis.

(*e*) In extemporized, hurried investigations, when the X-ray apparatus is not conveniently accessible, and more especially in retrograde catheterization from the pelvis of the kidney downward in the course of a renal operation, to determine whether there are any calculi lodged in the ureter.

(*f*) In fibrous or old inflammatory thickenings about the renal pelvis, which give a shadow on the photographic plate exactly like a stone.

Examination of the Urine Collected from the Ureters. Following the suggestions of Kelly five things are inquired into in making a thorough examination of the urine collected directly from the ureter and kidney.

1. The amount of fluid escaping at once upon the introduction of the catheter.
2. The rate of flow during catheterization.
3. Physical properties, specific gravity.
4. Chemical properties.
5. Bacteriological condition.

The following points are observed in securing separated urines (Kelly):

1. The exact time of introduction of each catheter is noted.

2. The time of withdrawal is noted and also written on a card, giving the exact duration of the flow.

3. The exact amount of secretion collected in the test tube is noted.

4. It is well to compare the rate of secretion, determined by noting the amount of flow in a given unit of time, say from five to fifteen minutes or longer, with the entire amount passed in the twelve hours during which the examination is made. If the amount secured is too small or too large the error may be rectified in this way. A nervous patient, for example, will sometimes pass an excessive amount through the catheter.

5. An analysis of each urine is made, investigating its physical, chemical, microscopic, and bacteriological characters. Especial attention must be paid to the urea as the most important representative of the physiological activity of the kidney.

CONGENITAL ANOMALIES IN THE DEVELOPMENT OF THE URETERS.

1. Absence of one or both ureters.
2. Occlusion of part or all of the lumen.
3. Double ureter.
4. Ectopic ureteral orifice.
5. Dilatation of a partially occluded ureter.
6. Bending and twisting of the ureter.

1. **Absence of one or both ureters** is usually associated with an absence of the corresponding kidney.

2. **Occlusion of part or all of the lumen** of the ureter is associated with atrophy and cystic degeneration of the corresponding kidney.

3. **A double ureter**, while not often found, is the commonest of all congenital defects in the ureter. The ureter may be double in any portion of its course or may begin in separate and distinct pelves of the kidney and open separately into the bladder.

A double ureter may be unilateral or bilateral. The condition has no clinical significance. The clinical diagnosis is inferred by the discovery of two separate and distinct ureteral openings into the bladder and by the passage of bougies and catheters into each of the ureters.

4. **An ectopic ureteral orifice** presents at a point outside the bladder. Very often this is found in the urethra and vagina.

Incontinence of urine is the complaint of the patient. The diagnosis is based upon direct inspection first of the vulva, next of the vagina through a speculum, of the urethra through a urethroscope, and, finally, of the bladder through a cystoscope.

The opening will be recognized as ureteral by seeing an intermittent flow of urine pass from it.

To determine whether there is a second ureteral opening on the same side a cystoscopic examination is made. A catheter or bougie passed into the opening will be directed to the corresponding kidney.

5. **Dilatation of a partially occluded ureter** is a rare finding. The corresponding kidney becomes atrophied and cystic unless there is an additional outlet to the urine.

6. **Bending and twisting of the ureter** is associated with hydronephrosis, which, in time, may result in complete cystic degeneration of the kidney.

INFLAMMATION OF THE URETER.

Ureteritis rarely exists apart from a similar involvement of the bladder or kidney, and is usually secondary to these lesions.

The causes of ureteritis are :

1. Extension downward from the kidney.
2. Extension upward from the bladder.
3. Foreign bodies lying within the ureter.

Tuberculous urethritis is most often primary in the kidney, extending downward to the ureter and finally involving the bladder and urethra.

The streptococcus, staphylococcus, and gonococcus infections almost invariably begin in the urethra or bladder and extend upward to the ureter and kidney.

It is a matter of common observation that an infection may be conveyed from the bladder to the kidney without leaving an evident lesion in the ureters, and it is also observed that the secretions from the infected kidney may continuously bathe the mucosa of the ureters without infecting them, and yet infect the bladder.

The diagnosis of ureteritis as an independent lesion is seldom made ; the clinical picture is usually involved in a cystitis or pyelonephritis.

Pain and tenderness along the course of the ureter are the most characteristic clinical manifestations of ureteritis.

It is possible to outline the pelvic portion of the thickened, tender ureter by a vaginal examination. The fingers introduced to the anterolateral wall of the vagina will follow the cord as it passes to the vault of the vagina and on to the side of the cervix. It must not be mistaken for a thickened adherent tube or ovary. Through the rectum the ureter may be traced to a higher level.

Tenderness on pressure will serve as a guide to the course of the ureter through the abdomen.

In a cystoscopic examination the ureteral prominence is seen to be injected with bloodvessels radiating from the ureteral orifice. Cloudy and purulent urine may be seen to drip from the orifice into the bladder.

A ureteral catheter will serve to collect the urine from the affected ureter, and this can be compared with the urine from the other ureter.

Tuberculous ureteritis is almost never a primary infection, but is usually secondary to tuberculous pyelonephritis.

We may speak of an ascending tuberculous infection, when the ureter is involved secondary to the bladder ; of a descending tuberculous infection, when the kidney is primarily infected. The infection may descend on one side and subsequently ascend on the other side.

The walls of the ureter are greatly thickened and the lumen is narrowed from thickening and caseous degeneration of the mucosa. Healing of ulcerated surfaces may result in a cicatricial contraction and obliteration of the lumen ; the ureter may be further obstructed by a plug of caseous material. This obstruction leads to hydronephrosis, and, finally, to cystic degeneration of the kidneys. A tuberculous pyonephrosis will almost inevitably result from such obstruction.

In advanced cases blood is found in the urine. Pus is invariably present in the urine, and in it tubercle bacilli are occasionally found. A positive clinical diagnosis can only be made by finding the tubercle bacillus in the urine catheterized from the ureters. When found in the presence of a thickened, tender ureter, the diagnosis of tuberculous urethritis is established.

The smegma bacillus closely simulates the tubercle bacillus in its size, form, and staining qualities. It is found in the secretions of

the external genitals, and is not to be confounded with the tubercle bacillus. In a catheterized specimen no smegma bacilli will be found.

Inoculation experiments may be carried out on guinea-pigs and rabbits with promising results. Injections with tuberculin as a diagnostic measure have been made, with positive results.

The finding of tuberculosis in the bladder or kidney, associated with an irregularly thickened, tender cord, should establish the diagnosis of the tuberculous ureteritis to a high degree of probability.

OBSTRUCTION OF THE URETER.

The ureter is more frequently obstructed in women than in men—a fact to be explained by the pressure exerted upon the ureter by swellings of the uterus, tubes, and ovaries.

Causes. The following classification is from Kelly :

First, *causes acting from without and occluding the ureter by pressing upon it,* such as :

1. Ovarian tumors.
2. Uterine tumors.
3. Cancerous infiltration of the broad ligaments.
4. Cancer of the cæcum.
5. Retroperitoneal pelvic sarcoma.
6. Aneurism of the iliac artery.
7. Scar tissue in the broad ligament.
8. Perineuritis.
9. An omental adhesion to the pelvic brim.
10. Thickened bladder walls.
11. Sarcoma of the bladder.
12. Pedunculated tumor of the bladder.

Second, *foreign bodies lodged in the ureteral canal :*

1. Calculus.
2. Blood clot.
3. Echinococcus cyst.

Third, *affections of the ureteral walls themselves :*

1. Ureteritis bacilli coli communis.
2. Ureteritis gonorrhœica.
3. Ureteritis tuberculosa.
4. Valve formation in the ureteral wall.
5. Gumma in the wall.

6. Cancer of the ureter.
7. Psorospermial cysts.

The point of obstruction is most frequent in the pelvic portion of the ureter. Here the ureter is often engaged between the unyielding bony wall of the pelvis and various tumors and inflammatory swellings within the pelvis. One or both ureters may be involved.

The diagnosis involves not only the fact of obstruction to the ureter, but the determination of the cause of the obstruction, its location, the rapidity with which it has developed, and the extent of the obstruction.

The clinical manifestations are variable and unreliable. Pain in the region of the kidney and ureter is the most constant symptom, yet a moderate degree of obstruction may exist without causing symptoms. The more rapidly the obstruction develops the greater are the clinical disturbances.

Frequent painful urination suggests an inflammatory obstruction or a calculus. Symptoms are particularly unreliable as a guide to the diagnosis in a slowly developing obstruction. Where the ureter has been suddenly plugged with a calculus or blood clot, the intensity and location of the pain are so characteristic as to frequently serve for a diagnosis.

In making a diagnosis of obstruction of the ureter all causes above enumerated are to be sought for. All swellings of the pelvis are to be outlined in a bimanual examination. Where there is frequent, painful urination and the cause of the disorder cannot be located in the ureter or bladder, it becomes imperative to explore the ureters by bougies and catheter. An inflammatory swelling of the ureter palpated through the vaginal wall suggests a probable cause for the obstruction, but does not eliminate the possible existence of other causes.

The only positive means of locating an obstruction in the ureter is by the passage of a bougie or catheter. The instrument will meet with an obstruction at a point below the pelvis of the kidney, or after passing a given point with some resistance the constricted portion grasps the instrument so as to resist its withdrawal. Occasionally when passing a ureteral catheter no special resistance will be noticed until there appears a sudden discharge of an unusual amount of fluid which has accumulated behind the obstruction.

URETERAL CALCULUS.

Calculi may lodge at any point in the course of the ureter, but are most often found near the pelvis of the kidney, the floor of the pelvis, and the flexure at the pelvic brim. These calculi are elongated and cone-shaped. They are of rare occurrence.

The *diagnosis* is based upon the periodic recurrence of a colicky pain radiating from the kidney along the course of the ureter. Following these attacks of pain there may be a rise of temperature and the appearance of blood in the urine.

Occasionally the stone will act as a ball-valve in plugging the ureteral opening of the pelvis of the kidney. In such an event there will be a temporary hydronephrosis with intermittent discharge of the contents through the ureter. Under favorable conditions a stone may be palpated through the vaginal wall. In rare instances a stone has been seen through a cystoscope to project from the ureter into the bladder.

When the stone lies higher up in the ureter it is detected with absolute certainty by passing a catheter or sound. The device practised by Howard Kelly of tipping the catheter or sound with wax is of special service in these cases.

STRICTURE OF THE URETER.

Direct violence is seldom the cause of stricture of the ureter because of its deep-seated position. The passage of a stone may result in a stricture, as may also long-standing inflammatory lesions in and about the ureter.

HYDROURETER AND HYDRONEPHROSIS

develop when the passage of the urine is obstructed. Pyoureter and pyonephrosis may develop secondary to an obstruction in the ureter and are dependent upon a pyogenic infection. These conditions are diagnosed by the passage of a catheter beyond the point of obstruction and the emptying of the accumulated fluid. Abdominal palpation may detect a cystic swelling. Continuous pain or intermittent colic in the region of the kidney and ureter are highly suggestive of the condition, though no positive diagnosis can be made without an exploratory puncture through an incision in the back or catheterization of the ureter.

URETERAL FISTULA.

A fistulous communication may be established between the ureter and the abdominal wall or some part of the genital or alimentary tract. Part or all of the urine may be directed into these structures.

The majority of ureteral fistulæ are caused by direct injury in vaginal and abdominal operations and in labor. Other causes are ulcerations following tuberculosis, carcinoma, and foreign bodies of the ureter. Rarely are the fistulæ congenital.

The *diagnosis* does not involve great difficulties. When but a single ureter is involved the urine is being constantly lost, while at the same time the bladder is filled and emptied at natural intervals. Were there present a vesicovaginal or vesicouterine fistula, such an event would be impossible. A colored sterile fluid (milk, permanganate of potassium) may be injected into the bladder, and if the urine continues to return clear no vesicovaginal fistula is present; the fistula must necessarily be ureteral.

Positive evidence is obtained by exposing the ureteral opening by means of a cystoscope and passing a sound or catheter into the ureter.

PLATE XLIV.

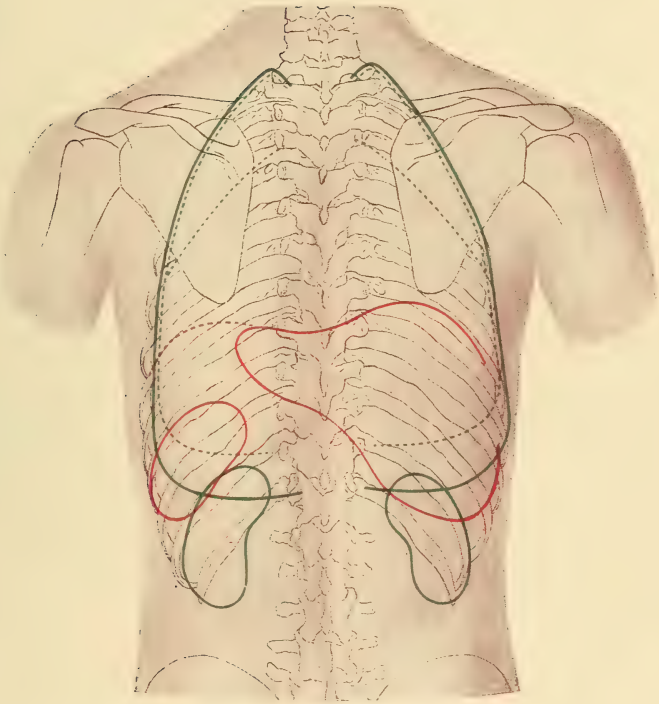

Situation of the viscera.

Outlines of heart and vessels—broad red lines. Margins of lungs and individual lobes—dotted green lines. Limits of pleural sacs—solid green lines. Liver—red shading. Stomach—green shading. (In part after His-Spalteholz and Luschka.

PLATE XLV.

Fig. 1.

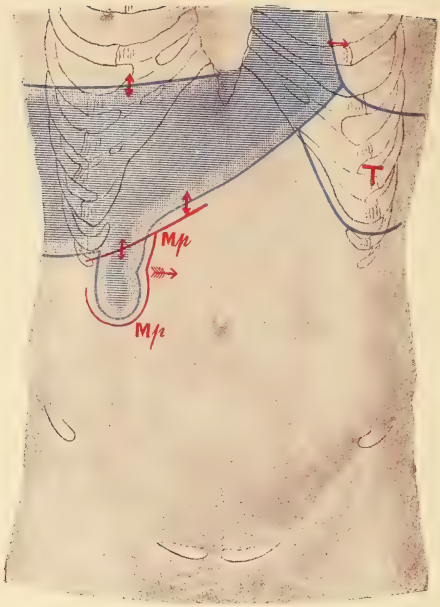

Movable kidney.

Fig. 2.

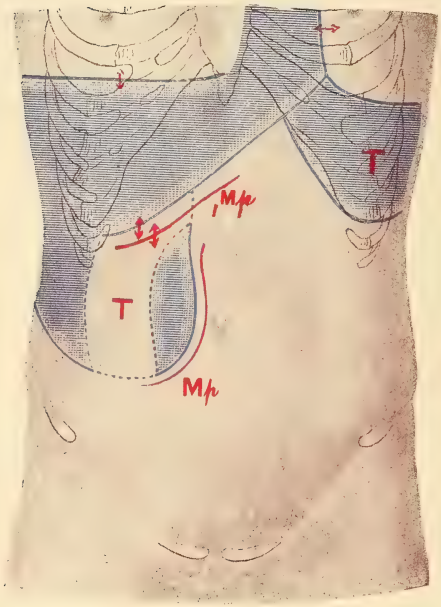

Sarcoma of the right kidney.

CHAPTER XXXIV.

THE DIAGNOSIS OF THE DISEASES OF THE KIDNEY.

Topography of the Kidneys. The kidneys are located in the lumbar region. They usually extend from the twelfth dorsal to the third lumbar vertebra ; the left lies at a little higher level than the right.

Methods of Examination. **Palpation** of the normal kidney is possible under favorable conditions. With the fingers of one hand supporting the lumbar muscles, and those of the other hand pressing deeply into the lumbar region from the front immediately below the costal arch, the abdominal muscles being thin and relaxed, the normal kidney may be felt.

When the kidney is enlarged or displaced palpation is usually not difficult.

A kidney that cannot be palpated with the patient in a recumbent position may be felt with ease by directing the patient to stand on her feet while supporting her body by her hands upon the seat of a chair. In this manner the abdominal walls are relaxed and the kidney falls downward and forward. It is important to observe the respiratory movements of the kidney.

Percussion of the normal kidney is very difficult because of its deep-seated position.

MOVABLE KIDNEY.

Under normal conditions the kidney is firmly embedded in fat, and is supported by the fat, the overlying peritoneum, and the renal bloodvessels.

A movable kidney may be a congenital lesion, but is almost invariably acquired. Küttner collected 667 cases, of which 584 were in women and 83 in men. The same author observed the right kidney movable in 553 cases, the left in 81, and both in 93. According to Edebohls, about 20 per cent. of gynecological cases have a movable kidney. Tight lacing and pregnancy account for

the greater frequency in women. Other exciting causes are heavy lifting, absorption of the perirenal fat, and an enlarged liver or spleen crowding the kidney out of place.

Three degrees of mobility are recognized : the *palpable kidney*, when the range of motion is limited, yet the kidney can be palpated ; *movable kidney*, when the range of motion is not below the level of the umbilicus, and *floating kidney*, when the kidney can be moved beyond the median line of the abdomen and below the level of the umbilicus. It is possible for the kidney to be at the brim of the pelvis.

The diagnosis is seldom difficult. The shape, consistency, position, and mobility of the kidney will usually suffice for a diagnosis. In very many cases there are no symptoms. A very movable kidney may give rise to no symptoms, while one with a limited range of motion may cause serious disturbances. A sense of dragging and discomfort in the side is the usual complaint. Various hysterical manifestations and gastric disturbances are chargeable to a movable kidney. Frequent painful urination is an occasional complaint.

Dietl's crisis is characterized by chills, fever, nausea, vomiting, severe abdominal pain, and collapse. The explanation for the paroxysms is not clear. Dietl believes them due to a kinking of the bloodvessels and ureter.

The abdominal walls are usually relaxed, and there is frequently a general visceraoptosis.

The kidney is identified by its bean-shape, general outline, consistency, and mobility, and by the fact that it can be replaced. The most common location is the midclavicular line just above the level of the umbilicus.

Movable kidney is to be differentiated from a distended gall-bladder and tumors of the pylorus and pelvis.

Distention of the gall-bladder is recognized by the clinical manifestations of a disease of the gall-ducts and by a lesser degree of mobility than is common to a movable kidney. A distended gall-bladder cannot be pushed downward. It remains in close proximity to the abdominal wall whatever the position of the patient, while a movable kidney changes with the change of position of the patient. It may be possible to feel the kidney in its normal position behind the distended gall-bladder.

Cancer of the pylorus is associated with the general signs of

malignancy, dilatation of the stomach, and vomiting. The kidney may be palpated distinct from the tumor mass.

ENLARGEMENT OF THE KIDNEY.

The lesions tending to enlarge the kidney are hydronephrosis, pyonephrosis, abscess, perinephric abscess, and new formations. Such enlargements may be detected by palpation and percussion. Comparison of the two kidneys will be of value in estimating the increase of size.

Hydronephrosis consists in a distention of the pelvis of the kidney with urine, and is caused by an obstruction of the ureter (see page 461). It is rarely congenital. The most frequent causes are renal calculi, pressure from surrounding tumors, and kinking of the ureter in a movable kidney. Malignant and inflammatory lesions in the bladder may obstruct the ureteral opening. The healing of ulcers in the ureter and about the ureteral prominence in the bladder is known to obliterate the lumen of the ureter.

Whatever the cause of obstruction to the urine in the ureter, there is an accumulation of urine in the pelvis and infundibulum. As the tension increases the papillæ atrophy, and, finally, the kidney becomes almost completely atrophied and replaced by cystic spaces.

However great the distention, there is nearly always some renal tissue to be found.

A strange observation is that hydronephrosis is most extreme where the obstruction is not complete and where the urine is discharged intermittently. Where the obstruction is complete the kidney usually atrophies and hydronephrosis may not develop. The distention may be enormous, filling the entire abdomen; this distention suggests the presence of an ascitic accumulation or an ovarian cyst.

The diagnosis is based wholly upon the physical findings. No symptoms may be present. When unilateral and of moderate size no serious difficulty is experienced.

On physical examination a tumor occupies the renal region. When in doubt as to the nature of the swelling, it should be aspirated. The fluid of hydronephrosis is clear or turbid, and there are present urea, uric acid, and some albumin. In cases of long standing the urinary elements may disappear, so that aspiration

can no more than identify the tumor as cystic. Nothing can be told of its origin from the aspirated fluid.

Intermittent hydronephrosis is sometimes associated with a movable kidney, and is explained in such cases by the occasional kinking of the ureter. The pelvis of the kidney distends and discharges at intervals, to again refill.

It is possible for the fluid to be evacuated and never refill. Suppuration may follow, converting a hydronephrosis into a pyonephrosis.

Pyonephrosis (pyelitis). A purulent secretion collects in the pelvis of the kidney. The suppurative process may extend to the kidney substance, giving rise to a pyelonephritis. The kidney substance atrophies, and little other than the capsule may remain to form the abscess sac. The lesion may involve one or both kidneys.

The *causes* of pyonephrosis are renal calculi, tuberculosis, acute and chronic infectious diseases, decomposed urine in a hydronephrosis, cystitis from various causes, and, finally, movable kidney.

Pyogenic organisms are essential to the development of pyonephrosis. These micro-organisms are chiefly the streptococcus pyogenes, staphylococcus pyogenes albus and aureus, colon bacillus, gonococcus, and tubercle bacillus.

The *diagnosis* is based upon the subjective symptoms of infection, upon the local findings in an external examination, catheterization of the ureters, and urinalysis. Chills, sweating, and an irregular fever may indicate a pus infection. The pain in the renal region would suggest the site of the infection. The patient becomes anæmic and loses flesh. A tumor mass is felt in one or both sides, which is tender to pressure and may assume large proportions.

The size of the tumor varies from time to time, and is in inverse proportion to the discharge of pus in the urine.

The urine always contains pus, usually casts and sometimes bits of renal tissue. It is acid in reaction unless decomposition takes place in the bladder. A positive diagnosis is made by an exploratory puncture or incision through the back or by a cystoscopic examination and catheterization of the ureter and pelvis. It is not only possible to withdraw the pus from the pelvis, but permanent cures have been effected by irrigating the pelvis of the kidney through a ureteral catheter.

By catheterizing the ureters it is possible to positively demonstrate the involved kidney and to exclude cystitis and ureteritis.

A bacteriological examination of the pus should be made. The presence of tubercle bacilli will identify a tuberculous pyonephrosis.

PERINEPHRIC ABSCESS.

An abscess about the kidney usually develops secondary to a pyonephrosis, but may be primary as a complication of infectious diseases and as a result of exposure to cold and direct injury.

The general symptoms are not unlike those of pyonephrosis. A swelling appears in the lumbar region which is at first hard and later fluctuating. The overlying skin is œdematous. The swelling is tender to pressure, and pain may radiate from the swelling to the thigh.

When the kidney is not involved there will be no pus in the urine. The two conditions likely to be confounded with a perinephritic abscess are coxitis and appendicitis. In the former are evidences of tuberculous infection in the vertebræ and possibly elsewhere ; in the latter is the history of a previous attack of appendicitis with its intestinal disturbances. It must be remembered that pus arising from either a coxitis or appendicitis may accumulate about the kidney.

NEW FORMATIONS OF THE KIDNEY.

Tumors of the kidney are benign or malignant. The benign tumors are fibroma, lipoma, angioma, lymphadenoma, aberrant adrenals, and adenoma. All these are exceedingly rare, with the exception of fibromata, which are frequently found as small nodules in the pyramids.

The malignant tumors are sarcoma, carcinoma, and hypernephroma.

Sarcoma is the most common of the new formations of the kidney. The growth may occur at any age, but it is peculiarly likely to appear in childhood. It is known to be congenital. Dr. William Roberts found twenty-five out of twenty-seven cases in children under ten years. They usually assume the alveolar form.

Carcinoma is less frequent, and is of the encephaloid variety. Both carcinoma and sarcoma may grow to an enormous size. Morris reported a sarcoma of the kidney weighing thirty-one pounds.

Their growth is rapid. In older individuals they are frequently preceded by calculus of the kidney.

HYPERNEPHROMA

has been imperfectly understood until recently. Formerly it was confounded with carcinoma, sarcoma, endothelioma, adenoma, lipoma, and angioma. Grawitz, in 1883, asserted that these rare tumors originate from adrenal tissue misplaced in the kidney substance during the process of development.

The growth is very soft, rarely invading the kidney, and is enveloped in a capsule. Hemorrhagic areas and cystic spaces are common. Metastasis to the lungs, liver, and bones are occasionally observed. Their growth is very rapid, and they are known to attain a large size. They are rarely seen in early life ; the time of election is between forty and fifty years of age. A beautiful illustration of a hypernephroma is seen in an article by C. P. Noble and W. W. Babcock in the July, 1902, number of the *American Gynecology.*

The diagnosis of malignant tumors of the kidney is based upon the appearance of blood in the urine, renal colic, general evidence of malignancy, and the local signs of a rapidly growing tumor of the kidney.

Hæmaturia may be the first indication. The blood in the urine may be fluid, but sometimes appears as casts of the ureter and pelvis of the kidney. Osler says he has never seen these casts in the urine except in cancer of the kidney. There is usually no blood in the urine in hypernephroma, because the tumor rarely invades the kidney substance.

Pain is not always present even in large tumors. It is located in the lumbar region and radiates down to the thigh and urethra. Colicky pain may be caused by clogging of the ureter with blood clots.

The general evidences of malignancy are emaciation and cachexia. The symptoms usually develop rapidly, though at times are very late in making their appearance.

A large abdominal tumor in an infant is either a sarcoma of the kidney or a retroperitoneal sarcoma of the lymph glands. The tumor is small or nodular, and is usually firmly fixed. The descending or ascending colon lies in front of the growth unless its enormous

size crowds the colon to one side. The soft, elastic character of the tumor may be mistaken for fluctuation. The percussion note is dull except in front, where the tumor is covered with the inflated colon.

The movable renal tumor may be confounded with a tumor of the ovary or a pedunculated fibroid of the uterus. A pelvic examination will demonstrate the connection of pelvic tumors with the uterus.

Enlargements of the liver and spleen are recognized by their outline, their immediate contact with the abdominal wall, the colon lying behind the swelling, and the absence of blood in the urine.

CYSTIC KIDNEYS.

Cystic spaces may occupy the kidney as a congenital or acquired defect. Any obstruction to the outlet of the urine may lead to hydronephrosis with cystic degeneration of the kidney. Echinococcus cysts of the kidney have been described.

RENAL CALCULI.

Kidney stones are formed by the deposition and agglutination of the normal and abnormal salts found in the urine.

The conditions predisposing to precipitation of the urine and the formation of stone are decomposition of the urine, supersaturation of the urine with salts, and the presence of abnormal constituents in the urine. It has been repeatedly emphasized that renal calculi very frequently form about a nucleus of desquamated epithelium, micro-organisms, and blood-coagulum. Harris has recently demonstrated the important rôle of micro-organisms in the formation of renal calculi. He substantiates his statement by the following facts: "Precipitation alone does not cause stone. Foreign bodies, such as exfoliated epithelial cells, blood clots, or those introduced experimentally from without, do not cause stone so long as they remain free from microbes. The kidneys frequently eliminate microbes with the urine without themselves becoming the seat of microbic invasion. These microbes may develop in the urine in the pelvis and cause the precipitation of certain salts. The character of the precipitate depends not entirely upon the composition of the urine, but also upon the kind of microbe present. The microbes in developing form zoöglœa masses, in and about which the

precipitate takes place. The agglutination of the particles by the zoöglœa mass forms the nucleus or starting-point of the stone. Such zoöglœa masses have been formed clinically in the urine. The microbe found most frequently in the urine is the colon bacillus. It grows in acid urine and under proper conditions causes precipitation of uric acid and acid urates. Microbes have been found in the centre of so-called primary stones. From the clinical side we find stones frequently preceded by a history of acute or chronic intestinal disorders ; of suppurative lesions of the skin ; of acute infectious diseases, as influenza, pneumonia, typhoid fever. Women very commonly date the beginning of their trouble from a confinement or imperfect puerperium. These conditions are all such as readily account for the presence of microbes in the urine." From these facts Harris is led to believe that almost all renal stones are of microbic origin.

Certain *chemical forms* of calculi are recognized. These are :

1. *Uric acid calculi*, which are the most common form, and range in size from sand-like particles to stones the size of a man's fist.

2. *Oxalate of lime calculi*, which take the form of a mulberry and rarely attain large proportions.

3. *Phosphatic calculi*, composed of the triple phosphates. They are not common as compared with stones of similar composition in the bladder.

4. Cystine, xanthine, indigo, and carbonate of lime which very rarely form renal calculi.

Renal calculi may be passed with little discomfort, and may remain in the kidney without the knowledge of the patient. The passage of a single stone may end the difficulty or repeated attacks of colic may be followed by the passage of a great number of stones. So long as the stone remains buried in the kidney substance there will be no renal colic ; but when it engages in the ureter and will not readily pass, a cramping, lancinating pain radiates downward from the kidney. Nausea and vomiting may accompany these attacks of renal colic, a chill may precede the outbreak, and the temperature often rises to 103° F. An initial chill may precede the attack. The following quotation is from Montaigue, who suffered for years from stone in the kidney : " Thou art seen to sweat with pain, to look pale and red, to tremble, to vomit well-nigh to blood, to suffer strange contortions and convulsions, by starts to let tears drop from thine eyes, to urine thick, black, and

frightful water, or to have it suppressed by some sharp and craggy stone that cruelly pricks and tears thee."

The pain may be referred to the opposite kidney. The blood in the urine is seldom excessive, and may appear only after exertion. As a rule, it no more than makes the urine smoky. Pyelitis may develop. This is ushered in by a chill and rise of temperature, pain and tenderness will be more or less constant in the region of the kidney, and pus will appear in the urine.

From the above clinical manifestations a diagnosis may often be established to a high degree of certainty. A positive diagnosis is made by the X-ray, and occasionally by sounding the pelvis of the kidney with a wax-tipped ureteral bougie or catheter.

Renal colic may be confounded with hepatic and intestinal colic. The location of the pain, its disposition to radiate to the end of the urethra, the appearance of the urine, the X-ray, and, finally, the sounding of the ureter and pelvis will determine the diagnosis. A renal calculus is distinguished from stone in the bladder by a cystoscopic examination and by the sound.

CHAPTER XXXV.

THE DIAGNOSIS OF THE CAUSES OF TOO FREQUENT AND PAINFUL MICTURITION.

Almost all conditions which cause pain in urinating also cause frequent urination. The two disorders are therefore best considered together. A distinction is clearly made between too frequent urination and incontinence of urine. The former implies an ability to retain the urine for a limited time, while in the latter condition the urine is voided as fast as it enters the bladder.

Either of these disorders may be congenital or acquired. They may be continuous or interrupted by intervals of complete relief.

Causes. 1. **Pregnancy.** During the first trimester and in the last month of pregnancy the patient urinates more frequently, though seldom with pain. The explanation lies in the position of the enlarged uterus.

2. **Nervous diseases,** both functional and organic. Pain is rarely present. A hyperæsthetic condition of the bladder is the explanation.

Nocturnal enuresis is a functional disorder attributable to an irritable spinal centre. The urinary organs are in a normal state. The condition rarely lasts after puberty.

3. **Hypersecretion of urine,** as in diabetes and hysteria, will demand frequent evacuation of the bladder.

4. **Overdistention of the bladder** from an atonic condition of the bladder wall or obstruction to the outflow of urine as from stricture may cause a frequent desire to urinate and the voiding of but a small quantity of urine. That which is voided is merely the overflow. Following upon an overdistention of the bladder there may be a frequent desire to urinate due to the irritation of the bladder and sphincter urethræ. In young women who through false modesty urinate at long intervals the inability to long retain the urine is frequently acquired. Such a condition may be incurable. The author recalls the case of a young woman who habitually retained her urine for twenty-four hours, and gave as her reason that

she did not like to go to stool. Such practices cannot fail to result disastrously.

5. **Displacements of the uterus** and the encroachment of pelvic tumors and exudates not seldom cause a frequent desire to urinate, and if these encroaching structures are tender to pressure urination will be painful. In forward displacements of the uterus the fundus presses upon the bladder and lessens its capacity. In retroversion of the uterus the cervix may cause frequent urination by impinging against the urethra and base of the bladder. One of the earliest evidences of cancerous invasion of the bladder from the cervix is frequent, painful urination, together with the appearance of blood in the urine.

6. **Dislocation and diseases of the urethra** tend to cause frequent and, many of them, painful urination. The reader is referred to the discussion of these subjects.

7. **All inflammatory diseases and new formations** of the bladder, ureters, and kidneys cause frequent and often painful urination.

The new-growth which causes most intense pain in urinating and is the most frequent cause of painful urination is caruncle. The pain thus caused is described as "shooting," "cutting," and "scalding."

8. **Foreign bodies**, notably stone, in any portion of the urinary tract cause frequent painful urination.

9. Highly concentrated urine may cause frequent and slightly painful urination; these symptoms disappear upon drinking large quantities of water.

CHAPTER XXXVI.

THE DIAGNOSIS OF THE CAUSES OF INCONTINENCE AND RETENTION OF URINE.

I. **Incontinence of Urine.** No urine is retained in the bladder, but escapes as fast as it is conveyed through the ureters. This disorder may be congenital or acquired. As a *congenital* lesion we find defect in the development of the urethra and bladder. The bladder may be congenitally small, or there may be a lack of development in the sphincter urethræ.

Acquired incontinence is most often due to fistulæ leading from some portion of the urinary tract to the exterior by way of the vagina, cervix, uterine body, bowel, or abdominal wall.

Overstretching of the urethra in the passage of instruments and the finger into the bladder may result in temporary and sometimes permanent incontinence of urine.

As a complication of many of the nervous disorders incontinence of the urine is frequently observed.

II. **Retention of Urine.** 1. **Hysteria** as a cause of retention of urine is little recognized. Too often the catheter is inserted without recognizing the hysterical element in the case. Tabes dorsalis is often associated with retention of the urine.

2. **Pressure upon the urethra, bladder, and ureters** by a displaced uterus and by new formations and inflammatory exudates in the pelvis and abdomen.

The cervix in a retroversion, and especially when the uterine body is enlarged through pregnancy or tumor formation, may press upon the urethra and obstruct the passage of the urine.

New-growths, particularly fibroids of the uterus, occasionally compress the urethra and cause retention of the urine.

3. **Obstruction of the urethra, bladder, and ureters** by new-growths and calculi occupying the interior of these structures.

4. **Spasmodic retention** due to a spasm of the urethra. This disorder is much rarer in women than in men. It has been improperly called a spasmodic stricture.

5. **Atony of the bladder** due to overdistention and as a complication of certain nervous and wasting diseases.

INDEX OF AUTHORS.

Abel, 298, 365
Ætius von Ameda, 142, 409
Bandl, 403
Bandler, 366, 367
Baumgart, 144
Baumgarten, 357
Bayea, 297
Bebkiser, 295
Beckmann, 187
Benoit, 334
Birch-Hirschfeld, 243
Bloom, Agnes, 216
Bowen, 203
Bowin, 142
Bouchard, 334
Boucher, 450
Braün, 439
Bulius, 356
Casper, 415
Charries, 321
Chiari, 206, 243, 316, 320
Chrobak, 371
Cohnheim, 306
Coupland, 364
Croom, 126
Cullen, 92, 265, 288, 295
Cullingworth, 137
Cushing, 394
Davidson, 230
Dechamps, 206
Deciderius, 369
Demure, 206
Dietrich, 31
Döderlein, 244
Donhoff, 330, 334
Doran, 335, 358
Downes, 430
Dudley, E. C., 163
Dudley, Palmer, 345
Duges, 203
Duncan, Matthews, 235
Edebohls, 465
Ellinger, 79
Engelmann, 24
Engstrom, 256
Eppinger, 243
Everett, 267
Farre, 338
Fehling, 263
Fisher, 215
Fraenkel, 144, 148, 160
Frank, 357
Freund, 172
Friedländer, 227
Fritsch, 143, 410
Frommel, 321
Gebhard, 26, 226, 244, 264, 266, 294, 295
Gottschalk, 157, 257, 264
Graham, D. W., 279
Granger, 334
Grawitz, 470
Guillemain, 356
Gurlt, 306
Gusserow, 306
Guthrie, 313
Hammerstan, 362
Harris, M. L., 430, 471, 472
Hart, Berry, 152, 264, 306
Hegar, 78, 350, 377
Herman, 31, 244
Hertz, 264
Herxheimer, 31, 32
Herzog, 28
Hippocrates, 142, 267
Hofmeier, 295
Homans, 358, 370
Hugenberger, 440
Irion, 24
von Kahlden, 31, 32
Kaltenbach, 144
Kaufman, 295
Kehrer, 187
Kelly, 256, 409, 412, 415, 417, 418, 421, 424, 442, 446, 455, 456, 457, 461, 463
Klebs, 243
Klein, 234, 440
Kleinwächter, 257
Klobs, 256, 350
Kossman, 142, 264
Koster, 148
Kreutzmann, 148
Krussen, 329
Korzysz-Kowski, 151
Kuhn, 130
Kundrat, 26, 330
Küster, 31, 203
Küttner, 465
Kworostansky, 152
Ladinski, 154
Landau, 244

Landel, 243
Lecorché, 357
Le Count, 244, 335
Leopold, 39, 280, 361, 371
Lépine, 334
Lorey, 264
Majer, 143
Marchand, 144, 148, 149, 160, 371
Martin, 31, 314, 321, 329, 330, 341, 343, 346, 356, 358, 364
Menge, 206, 295, 351, 357, 394
Meyer, W., 330
Möricke, 26
Morris, 469
Mosler, 357
Mueller, 215, 220, 230, 256
Muer, 334
Nägel, 205
Neumann, 148, 151, 153, 156
Nitze, 409, 415, 417, 418
Nobel, 265
Noeggerath, 313
Ochsner, 329
Olshausen, 188, 239, 244, 358, 359, 365, 391
Orth, 243, 346, 370
Orthmann, 369
Pagel, 450
Palmer, 80
Pantz, 154
Pawlik, 409, 415, 417, 418, 421, 455
Peckham, 213
Peters, 149, 160
Petrow, 243
Pfannenstiel, 307, 346, 359, 370
Philips, 439
Pick, 152, 278, 295, 370
Pierce, Frank, 234
Ponfick, 243
Popoff, 31, 32, 350
Poten, 152, 155, 156
Pozzi, 244, 335
Preuschen, 230
Prochowick, 321
Pryor, 455
Quain, 341
Recklinghausen, 264, 335
Reed, 197
Reinecke, 31
Richet, 357
Richie, 335
Ries, 295
Rindfleisch, 243
Robb, Hunter, 215
Roberts, William, 469
Rösger, 257
Rosthorn, 330
Ruge, 244, 249, 250, 264, 279
Rumler, 148
Runge, 144
Russel, 371
Sänger, 160, 218, 334, 335, 336, 341
Schatz, 346, 350
Schauta, 316, 320, 321
Schmidt, 50, 234
Schroeder, 142, 198, 394
Schramm, 330
Schwarz, 214, 215
Shenck, 371
Shultze, 172, 196, 236, 346
Simon, 415, 429
Simpson, Sir James Y., 82
Skene, 410
Smith, Richard R., 231
Spencer, 359
Spiegelberg, 303
Stewart, 334
Storch, 147
Stratz, 350
Suchanek, 434
Sutton, Bland, 317, 335, 356, 364, 372
Tait, Lawson, 383
Tamesvary, 370, 371
Thoma, 243
Thornton, 386
Ulmann, 341
Van der Hoeven, 143, 148, 151
Van Heukelom, 243
Vassmer, 152
Vedeler, 257
Veit, 152, 250
Velpeau, 142
Virchow, 142, 144, 147, 258, 439, 445
Voigt, 157
Waldeyer, 338, 359
Webster, J. C., 27, 122, 126, 147, 148, 152, 178, 179, 215, 218, 288
Weichselbaum, 243
Welsh, 280
Wenkel, 206, 214, 220, 330, 341, 409, 440
Wenkler, 295
Werth, 295
Wertheim, 313, 321, 394
Westphalen, 26
Williams, Bristol, 231
Williams, Roger, 306
Williams, Whitridge, 26, 233, 256, 306, 334, 350, 357
Winter, 114, 296, 374
Wolf, 356
Zangemeister, 370
Zeller, 295
Zemann, 334
Ziegler, 350

INDEX.

ABDOMEN, auscultation of, 56
in ectopic pregnancy, 133
in pregnancy, 109.
inspection of, 51
mensuration of, 56
palpation of, 52
in ectopic pregnancy, 133
percussion of, 55
Abdominal examination, external, 51
wall, phantom tumors of, 378
Abdomino-vaginal examination, 62
Abdomino-vagino-rectal examination, 69
Abortion, diagnosis of, 115
tubal, 127
Abscess formation in tubal pregnancy, 128
of ovary, 351, 353
pericæcal, 376
tubo-ovarian, 351
Actinomycosis of Fallopian tube, 334
of ovary, 358
Adenocarcinoma uteri, 293
Adenofibromyoma uteri, 264
Adhesions, diagnosis of, 174
Adipocere, 129
Alcohol as a fixing agent, 95
Alcoholism, cause of sterility, 40
Allantoic cyst, 384.
differentiated from ovarian tumors, 384
Amenorrhœa, 34
absolute, 34
catching cold a cause of, 35
causes of, general, 34
local, 35
changes in environment a cause of, 35
debilitating disease a cause of, 34
diseases of genital organs causing, 35
hypoplasia and atrophy causing, 35
mental shock and anxiety causing, 35
relative, 34
Ampullar tubal pregnancy, 123
Amyloid degeneration of uterine fibroids, 268
Anæmia causing sterility, 40
uterine hemorrhage, 29
Anatomy of bladder, 409
of ovary, 338
of peritoneum, 393
of urethra, 409
Angioma of vulva, 209
Anteflexion differentiated from retroversio-flexion of uterus, 202
of uterus, 194, 202
Anteposition of uterus, 173
Anteversion of uterus, 193
Apoplexia uteri, 32
Appendicitis differentiated from salpingitis, 328
Arterio-sclerosis of uterus, 31
Ascites differentiated from ovarian tumors, 379
free, 379
Atresia of urethra, 432
of vagina, 221
of vulva, 204
Atrophy of ovary, 345
congenital, 341
of uterine fibroids, 365
of vulva, 211

BALLOTTEMENT, 107
Bardeen CO_2 freezing microtome 93
Bartholinean gland, cysts of, 215
Benign non-infectious peritonitis, 394
Bicornate uterus, 168
pregnant, 140
Bladder, anatomy of 409.
catheter in examination of, 415
digital examination of, 69
distended, differentiated from ovarian tumors, 378
examination of, methods of, 413
catheter and sound, 415
cystoscopy, 415
inspection, 415
Kelly-Pawlik, 421
Nitze, 417
palpation, 414
percussion, 413
segregator, 403
urethroscopy, 415
hemispheres of, 413
inspection of, 415
irritable, in pregnancy, 104

Bladder, landmarks in, 412
normal, cystoscopic appearance of, 419
palpation of, 413
percussion of, 413
physiology of, 409
quadrants of, 413
topography of, 411
Blasenmole, 142
Bozeman's specula, 72
Broad ligament fibroids of uterus, 273

CALCAREOUS degeneration of uterine fibroids, 266
Cancerous degeneration of uterine fibroids, 268
ulcers of cervix, 254
Carcinoma, 214
of cervix, 279, 283, 287, 292, 298
cauliflower, 281
differentiated from endocervicitis, 254
of corpus uteri 279, 299, 284, 287, 293
of Fallopian tube, 336
infiltrating, of vaginal portion of cervix, 281
of ovary, 364
squamous-cell, of body of uterus, 295
syncytiale, 160
of urethra, 436
uteri, classification of, topographical, 279
recurrence in, 304
of uterus, 279
bimanual palpation in, 289
cachexia in, 286
diagnosis of, clinical, 285
anatomical, 281
differential, 296
extension of, 301
microscopic, 289
recurrence of, 304
etiology of, 279
exploration of uterine cavity in, 289
hemorrhage in, 285
heredity in, 279
leucorrhœa in, 286
pain in, 286
squamous-cell, 295
symptoms, miscellaneous, in, 286
topographical classification, 279
of vagina, 231
differentiated from decubitus ulcers, 233
from syphilitic ulcers, 233
from tuberculous ulcers, 233
Carcinoma of vaginal portion of cervix, 279, 281, 286, 289, 296
of vulva, 214
Carcinomatous peritonitis, 395
Caruncle, 435
Case record, form of, 19
Catarrh of cervix, 249
Catarrhal endometritis, 236
salpingitis, 319
vaginitis, 226
Catheter in examining bladder, 415
Cauliflower carcinoma of cervix, 281
Celloidin sections, 77
Cellulitis, pelvic, 402
acute, 403
chronic, 404
classification of, 402
definition of, 402
diagnosis of, differential, 406
differentiated from malignant disease of pelvis, 407
from paratyphlitis, 406
from pelvic hæmatoma, 406
peritonitis, 406
from psoas abscess, 407
from retro-uterine perimetritis, 406
from subserous fibroid, 407
exudate in, consistency of, 405
form of, 405
mobility of, 405
position of, 404
relation of, to neighboring organs, 405
tenderness of, 405
Cervical catarrh, 249
endometritis, 249
Cervix, carcinoma of, 279, 283, 287, 292 298
cauliflower, 281
differentiated from endocervicitis, 254
vaginal portion of, 279, 281, 286, 289, 296
catarrh of, 249
ectropion of, differentiated from endocervicitis, 254
erosions of, 250, 297
classification of, 250
diagnosis of, differential, 253
follicular, 251
healing of complete, 252
incomplete, 252
papillary, 250,
simple, 250
fibroids of, 261, 273
interstitial, 298
follicular degeneration of, 298
hemorrhage from, 24
laceration of, 112

Cervix, mucous membrane of, eversion of, 296
patch on, 250
sarcoma of, 298, 307
technic of excising piece of, for microscopic examination, 289
test excision of, 92
tuberculosis of, 254
ulcers of, 254
cancerous, 254
decubitus, 254
syphilitic, 298
tuberculous, 254, 297
vaginal portion of, infiltrating carcinoma of, 281
Chorio-epithelioma malignum, 160
diagnosis of, 161
etiology of, 161
following hydatiform mole, 146
macroscopic appearance of, 162
of vagina, 234
Chorion, hydatiform degeneration of, 142
Chorionic villi in hydatiform mole, 146
Chylous cysts, differentiated from ovarian tumors, 383
of mesentery, 383
Colpitis, 225
emphysematous, 227
Conception, conditions essential to, 39
retained products of, diagnosed by curette, 87
Condylomatous vaginitis, 228
Confinement, date of, 112
Congestion of ovary, 354
Connective tissue tumors of ovary, 369
Corpus luteum cysts, 355
uteri, carcinoma of, 279, 284, 287, 293, 299
Currier's speculum, 75
Cusco's speculum, 73, 74
Cystadenoma pseudomucinosum, 362
serosum, 364
Cystic degeneration of ovary, 350, 375
differentiated from ovarian tumors, 375
mole, 142
new formations of Fallopian tube, 337
Cystoscope, Nitze, 417
Cystoscopic appearance of normal bladder, 419
Cystoscopy, 415
Cysts, allantoic, differentiated from ovarian tumors, 384
of Bartholinean gland, 215
chylous, differentiated from ovarian tumors, 383
of mesentery, 383
corpus luteum, 355
dermoid, of Fallopian tube, 335
Cysts, dermoid, of ovary, 365
echinococcus, differentiated from ovarian tumors, 378
hydatid, of Morgagni, 337
of hymen, 220
of labia minora, 216
ovarian, 330
degeneration of, malignant, 389
differentiated from peritonitis, 401
from salpingitis, 330
exploratory puncture and incision of, 391
fate of, 391
hemorrhage into, 388
leakage of, 388
malignant degeneration of, 389
rupture of, 388
suppuration of, 389
torsion of pedicle of, 385
pancreatic, 382
differentiated from ovarian tumors, 378, 382, 385
from salpingitis, 330
parovarian, 330, 371, 378, 385
of pelvis, echinococcus, 378
sebaceous, of vulva, 213
simple, of ovary, 355
tubo-ovarian, 318, 355
of Fallopian tube, 318
of vagina, 187, 229
differentiated from prolapsus uteri, 187
of vulva, 215
dermoid, 214, 218.

DECIDUA, discharge of, in ectopic pregnancy, 134
of ectopic pregnancy, 301
removal of, by curette, 89
serotina, 146
vera in hydatiform mole, 146
Decidual endometritis, 238
Deciduoma malignum, 160
Decubitus ulcers of cervix, 254
of vagina, 227, 233
Degeneration of uterine fibroids, 265
Dermoid cysts of Fallopian tube, 335
of ovary, 365
of vulva, 214, 218
Descensus ovarii, 343
Diagnosis of abortion, 115
of adhesions, 174
causing uterine displacements, 174
anatomical, of carcinoma of uterus, 281
of pregnancy, 116
of chorio-epithelioma malignum, 161

Diagnosis, clinical, of carcinoma of uterus, 285
of diseases of vagina, 228
of ectopic pregnancy, 132
of new formations of ovary, 373
of salpingitis of Fallopian tube, 319, 325
differential, of carcinoma of uterus, 296
of ectopic pregnancy, 139
of erosions of cervix, 253
of peritonitis, 400
of purulent salpingitis of Fallopian tube, 328
early, a plea for, 17
of life and death of fœtus, 111
microscopic, of cancer of uterus, 289
of carcinoma of uterus, 289
of multiparity, 112
of sactosalpinx, 327
of scrapings in endometritis, 249
of uterine pregnancy, 101
of variety of ovarian cysts, 390
Digital examination of bladder, 69
of internal genitals, 57
of rectum, 66
of vagina, 57
Dilatation of urethra, 432
Dilating urethral orifice, 427
Diphtheritic ulcers of vagina, 227
Dislocations of urethra, 433
Divulsion, instruments of, 80
Double uterus, 169
vagina, 204, 224
Dropsy of villi, 142
Dysmenorrhœa, 36
inflammatory diseases causing, 38
maldevelopments causing, 37
malpositions causing, 37, 38
new formations causing, 38
Dysmenorrhœal endometritis, 237
Dyspareunia, cause of sterility, 41

ECHINOCOCCUS cyst, differentiated from ovarian tumors, 378
of pelvis, 378
Ectopic pregnancy, 122
active fœtal movements in, 133
advanced, 377
anatomical changes in, 130
auscultation of abdomen in, 133
bimanual examination in, 137
classification of, 123
decidua of, 301
discharge of, in, 134
diagnosis of, clinical, 132
by curette, 87
differential, 139
Ectopic pregnancy, diagnosis of, differentiated from fibromyoma uteri, 141
from malignant disease of pelvis, 141
from ovarian tumors, 140
from pelvic exudate, 139
hæmatoma and hæmatocele, 141
from pregnancy in a bicornate uterus, 140
in a retroverted uterus, 138
in a rudimentary horn, 140
from uterine pregnancy complicated with tubal or ovarian swelling, 138
etiology of, 122
genetic reaction in, 122
palpation of abdomen in, 133
retrogressive changes in, 129
suppuration in, 126
Ectropion of cervix differentiated from endocervicitis, 254
Elephantiasis of vulva, 209
Emmet's tenaculum, 72
Emphysematous vaginæ, 227
colpitis, 227
Enchondroma of vulva, 213
Endocervicitis, 249
differentiated from carcinoma of cervix, 254
from ectropion of cervix, 254
Endometritis, 299
acute, 235
catarrhal, 236
causing uterine hemorrhage, 30
cervicalis, 249
chronic, 236
classification of, anatomical, 240
clinical, 235
decidual, 238
diagnosed by the curette, 86
diagnosis of scrapings in, 249
dysmenorrhœic, 237
exfoliative, 239
forms of macroscopic, 240
microscopic, 241
fungous, 239, 240
glandular, 242
gonorrhœal, 237
hemorrhagic, 236
hypertrophic, 240
interstitial, 247
acute, 248
chronic, 248
membranous dysmenorrhœa, 239
polypoid, 241
postabortive, 239
in pregnancy, 114
pseudodiphtheritic, 241
puerperal, 238

Endometritis, senile, 239
acute, 248
tuberculous, 237, 300
ulcerative, 241
villous, 240
Endothelioma ovarii, 371
uteri, 304
of vagina, 234
Epispadias, 205, 432
of vulva, 215
Epithelial new formations of ovary, 359
Erosions. See Endocervicitis, 253
carcinoma, 292
of cervix, 250, 297
classification of, 250
diagnosis of, differential, 253
follicular, 251
healing of, 252
complete, 252
incomplete, 252
papillary, 250
simple, 250
Erysipelatous vulvitis, 208
Eversion of mucous membrane of cervix, 296
Examining table, Schmidt, 49
Exfoliative endometritis, 239
Extra-uterine pregnancy, 122
Exudates, parametric, 329, 354
differentiated from salpingitis, 329
paratyphlitic, 406
pelvic, 139
perimetric, serous, 375
peritoneal, 398

FALLOPIAN tube, actinomycosis of, 334
anomalies in structure of, 310
carcinoma of, 336
changes in position of, 311
circulatory disturbances of, 312
cystic new formations of, 337
dermoid cysts of, 335
development of, anomalies in, 310
examination of, methods of, 310
fibroma of, 335
fibromyxoma cystoma of the fimbriæ of, 336
gonorrhœal infection of, 328
hæmatosalpinx of, 318
hydrosalpinx of, 316
infectious granuloma of, 313
inflammations of, 313
lipoma of, 335
in menstruation, 28
myoma of, 335
new formations of, 330, 334
papilloma of, 334
Fallopian tube, parasites of, 334
polyps of, 335
pyosalpinx of, 324
sactosalpinx of, contents of, 328
diagnosis of, 327
salpingitis of, catarrhal, 314
chronic, 315
diagnosis of, clinical, 319
classification of, 314
purulent diagnosis of clinical, 325
diagnosis of, differential, 328
tuberculous, 330
sarcoma of, 336
syphilis of, 334
tumors of, 334
tubo-ovarian cysts of, 318
Fibroid, birth of, 270
Fibroids of cervix, 261, 273
interstitial, 260
of cervix, 298
of uterus, 260
intraligamentary, of uterus, 273
intramural, of uterus, 260
retro-uterine, 202
differentiated from retroversio-flexion of uterus, 202
submucous, 259, 300
subserous, 261, 329, 407
differentiated from pelvic cellulitis, 407
from salpingitis, 329
uterine, amyloid degeneration of, 268
atrophy of, 365
calcareous degeneration of, 266
cancerous degeneration of, 268
clinical characteristics of, 268
degeneration of, 265
fatty degeneration of, 267
gangrene of, 268
hemorrhage in, 269
myxomatous degeneration of, 267
pressure and traction from, 270
of uterus, 256
differentiated from chronic metritis, 275
from hæmatocele, 277
from hæmatoma, 277
from uterine pregnancy, 276
submucous, 259
subserous, 261
suppuration of, 268
telangiectatic, 268
Fibroma of Fallopian tube, 335
of ovary, 369

Fibroma of urethra, 436
of vulva, 213
Fibromyoma, sarcomatous degeneration of, early recognition of, 309
uteri, 141, 256
atrophy of, 265
changes in endometrium, 268
characteristics of, clinical, 268
degeneration of, 265
amyloid, 268
calcareous, 266
cancerous, 268
fatty, 267
myxomatous, 267
sarcomatous, 268
diagnosis of, anatomical, 258
clinical, 269
differential, 275
microscopic, 262
differentiated from ectopic pregnancy, 141
etiology of, 256
gangrene of, 268
hemorrhage in, 269
histogenesis of, 257
intraligamentary, 273
objective signs of, 272
palpation and adnexæ and round ligament in, 275
pressure and traction from, 270
suppuration of, 268
telangiectatic, 268
of vagina, 231
Fibromyxoma cystoma of the fimbriæ, 336
Fissures, congenital, of vulva, 204
Fistulæ of urethra, 436
Fixing of specimens, 95
Fœtal heart tones, 109
movements, 107
active, in ectopic pregnancy, 133
souffle, 109
uterus, 164
Fœtus, life and death of, diagnosis of, 111
Follicular degeneration of cervix, 298
erosions, 251
of cervix, 251
Formalin, 95
Fungous endometritis, 239, 240
Furunculosis of vulva, 206

GALL-BLADDER, distended, 383
differentiated from ovarian tumors, 383
Gangrene of uterine fibroids, 268
of vulva, 205, 209
Genital organs, normal secretions of, 45
tract, hemorrhage from, 23
Genitals, external, examination of, 57
Genitals, internal, digital examination of, 57
Gestation, subperitoneo-abdominal, 124
tubo-ovarian, 126
Glands of pregnancy, 300
Glandular endometritis, 242
Gonorrhœal endometritis, 237
infection of Fallopian tube, 328
peritonitis, 394
Graafian follicles, 339
Granuloma, infectious, of Fallopian tube, 313
Granulomata, infectious, of ovary, 356

HÆMATOCELE differentiated from fibroids of uterus, 277
pelvic, 406
retro-uterine, 202, 376
differentiated from peritonitis, 400
Hæmatocolpos from atresia vaginæ, 222, 223
Hæmatoma, 125, 277
differentiated from fibroids of uterus, 277
intraligamentary, 376
of the ovary, 346, 347
pelvic, 141, 406
differentiated from pelvic cellulitis, 406
retro-uterine, 202
of vulva, 209
Hæmatometra from atresia vaginæ, 222
Hæmatosalpinx, 318
from atresia vaginæ, 222
of Fallopian tube, 318
Hæmatotrachelos from atresia vaginæ, 222
Hardening and embedding in celloidin, 95
in paraffin, 96
Hemorrhage in carcinoma of uterus, 285
caused by the curette, 88
by sound, 85
from cervix, 28
during pregnancy, 113
in fibromyoma uteri, 269
from genital tract, 23
in uterine fibroids, 269
into ovarian cysts, 388
intraperitoneal, 135
uterine, anæmia a cause of, 29
endometritis causing, 30
local causes of, 29
passive congestion causing, 29
plethora causing, 29
purpuric conditions causing, 29
specific infectious diseases causing, 29
subinvolution causing, 29

Hemorrhage, uterine, systemic causes of, 29
from vagina, 24
from vulva, 24
Hemorrhagic endometritis, 236
metritis of menopause, 32
Hermaphroditism, 205
Hernia of ovary, 344
of uterus, 203
Hydatid cysts of Morgagni, 337
mole, 142
Hydatids, uterine, 142
Hydatiform degeneration of chorion, 142
mole, chorio-epithelioma malignum following, 146
chorionic villi in, 146
decidua serotina in, 146
vera in, 146
degeneration of, malignant, 150
diagnosis of, 154
examination of, microscopic, 146
history of, 142
syncytioma malignum following, 151
Hydronephrosis, 384
differentiated from ovarian tumors, 384
Hydrops tubæ profluens, 317
Hydrosalpinx, 316
of Fallopian tube, 316
Hymen, 220
cysts of, 220
rupture of, in labor, 112
Hypertrophic endometritis, 240
Hypertrophy, congenital, of ovary, 342
of ovary, 345
of vulva, 209
Hypoplasia and atrophy causing amenorrhea, 35
Hypospadias, 205, 432
of vulva, 205
Hysterocele, 203

INFANTILE vulva, 204
Infectious granulomata of Fallopian tube, 313
granulomata of ovary, 356
Infiltrating carcinoma of vaginal portion of cervix, 281
Inflammations of Fallopian tube, 313
of ovary, 348
of urethra, 433
Inflammatory diseases causing dysmenorrhœa, 38
sterility, 43
Infundibular tubal pregnancy, 129
Interstitial endometritis, 247
acute, 248
chronic, 248
Interstitial fibroid of cervix, 298
fibroids of uterus, 260
tubal pregnancy, 129
Interureteric ligament, 412
Intraligamentary development of ovarian tumors, 384
fibroids of uterus, 273
hæmatoma, 376
Intramural fibroids of uterus, 260
Intraperitoneal hemorrhage, 135
Inversion of the uterus, 187
differentiated from partially divided uterus with a depression in the fundus, 192
from pedunculated fibroid or polyp lying within the vagina, 192
from prolapsus uteri, 192
from submucous fibroid lying within the cavity of the uterus, 192
from submucous fibroid with partial inversion, 192

KELLY-PAWLIK method of cystoscopy, 421
Knee-chest position, 60
Kraurosis vulvæ, 211

LABIA minora, cysts of, 216
Labor, spurious, 134
Laceration of cervix, 112
Lateroposition of uterus, 174
Leprosy of ovary, 358
Leucorrhœa, 45
in cancer of uterus, 286
in infants, 45
in old women, 46
in pregnancy, 106
in sexual maturity, 46
in virgins, 45
Lipoma of Fallopian tube, 335
of vulva, 213
Lithopedion, 129
Lithotomy position, 60
Liver, tumors of, 383
differentiated from ovarian tumors, 383

MALDEVELOPMENTS causing dysmenorrhœa, 37
sterility, 41
of ovary, 341
of vagina, 221
Malformations causing sterility, 41
congenital, of urethra, 432
of urethra, acquired, 432

Malformations of uterus, 163
accessorius, 169
bicornis, 168
unicellis, 170
deficiens, 163
didelphys (uterus duplex, uterus separatus), 169
fœtalis, 164
membranaceous, 163
rudimentarius, 163
septus (bilocularis), 168
duplex, 167
unicornis, 166
of vagina, 221
Malignant growth diagnosed by the curette, 87
Malpositions causing dysmenorrhea, 38
sterility, 42
of uterus, 171
anteflexion, 194
anteposition, 173
anteversion, 193
elevatio-uteri, 176
hernia, 203
inversion, 187
lateroposition, 174
pathological fixation, 171
mobility, 171
primary descent, 181
prolapsus, 178
uteri with atresia, 186
retroposition, 173
retroversio-flexion, 195
secondary descent, 181
torsion, 177
Mammary glands, changes of, in pregnancy, 104, 113
changes in, in tubal pregnancy, 133
Marriage of near relatives a cause of sterility, 40
Membranaceous uterus, 163
Menopause, 44
clinical manifestations of, 44
effect of climate on, 44
heredity on, 44
race on, 44
social state on, 44
hemorrhagic, metritis of, 32
Menorrhagia, 28
Menses, retention of, 35
Menstruation, 24
anatomy of, 26
cessation of, 101
effects of ovariotomy on, 35
Fallopian tube in, 28
menstrual molimena, 36
pain during, 36
physiological absence of, 34
in tubal pregnancy, 133
Mesentery, chylous cysts of, 383
Metastasis in carcinoma uteri, 303
Metritis, chronic, 255, 275
differentiated from fibroids of uterus, 275
coli, 298
hemorrhagic, of menopause, 32
Metrorrhagia, 28
Microtome, Bardeen CO_2 freezing, 93
student, 96
Miscarriages, number of children and, 22
Mole, cystic, 142
formation in tubal pregnancy, 128
hydatid, 142
hydatiform, chorio-epithelioma malignum following, 146
chorionic villi in, 146
decidua vera in, 146
history of, 142
ulcus of vulva, 208
Morgagni, hydatid cysts of, 337
Morning sickness, 103
in tubal pregnancy, 133
Mucous patch on cervix, 250
polyps, 301
Multiparity, diagnosis of, 112
Mummification, 129
Myoma of Fallopian tube, 335
ovarii, 370
uteri, 256
Myxoma chorii, 142
Myxomatous degeneration of uterine fibroids, 267

NARCOSIS, examination under, 66
Nervous phenomena in pregnancy, 104
in tubal pregnancy, 133
Neuroma of vulva, 213
Nitze cystoscope, 417

OBESITY, 384
cause of sterility, 40
Œdema of vulva, 209
Omentum, fatty tumors of, 283, 378
Oophoritis, 348
Ovarian cyst, degeneration of, malignant, 389
diagnosis of variety of, 390
differentiated from peritonitis, 401
from salpingitis, 330
exploratory puncture and incision of, 391
fate of, 391
hemorrhage in, 388
leakage of, 388
malignant degeneration of, 389
rupture of, 388
suppuration of, 389

Ovarian cyst, torsion of pedicle of, 385
tumors, 140, 358
bilateral, 384
complicating pregnancy, 390
development of, intraligamentary, 384
differentiated from allantoic cysts, 384
from ascites, 379
from chylous cysts, 383
from cystic degeneration of ovaries, 375
from distended bladder, 378
from distended gall-bladder, 383
from echinococcus cyst, 378
from ectopic pregnancy, 140
from fatty tumors, 383
from hydronephrosis, 384
from pancreatic cysts, 382
from parovarian cysts, 378, 385
from phantom tumors, 378
from splenic tumors, 383
from tumors of liver, 383
fate of, 391
intraligamentary, development of, 384
Ovariotomy, effect on menstruation, 36
Ovaritis, 348
acute, 348
chronic, 349, 352
diagnosis of, clinical, 352
differentiated from congestion of ovary 354
from new-growth of ovary, 354
from parametric exudates, 354
from perityphlitis, 354
salpingitis, 354
tuberculous, 356
Ovary, abscess of, 351, 353
acute, 351
chronic, 351
absence of, 341
actinomycosis of, 358
anatomy of, 338
atrophy of, 345
congenital, 341
carcinoma of, 314
changes in position of, 342
circulatory disturbances of, 346
congestion of, 354
differentiated from ovaritis, 354
corpus luteum cysts of, 355
cystic degeneration of, 350, 375
Ovary, cystic degeneration of, differentiated from ovarian tumors, 375
cysts of, dermoid, 365
simple, 355
degeneration of, cystic, 350
development of, anomalies in, 341
endothelioma of, 371
examination of, methods of, 340
fibroma of, 369
foreign bodies in, 346
granulomata of, infectious, 356
hæmatoma of, 346
hernia of, 344
histology of, 338
hypertrophy of, 345
congenital, 342
inflammation of, 348
leprosy of, 358
maldevelopments of, 341
myoma of, 370
new formations of, 358
clinical diagnosis of, 373
epithelial, 359
growths of, 354
differentiated from ovaritis, 354
parasites of, 346
sarcoma of, 370
supernumerary, 341
syphilis of, 357
torsion of pedicle of, 385
tuberculosis of, 356
tumors of, 358
adherent, 385
connective tissue, 369

PANCREATIC cysts, 382
differentiated from ovarian tumors, 382
Papillary erosions, 250
Papilloma of Fallopian tube, 334
Paraffin sections, 98
Parametric exudates, 329, 354, 376
differentiated from ovaritis, 354
from salpingitis, 329
Parametritis. See Pelvic cellulitis, 402
acute, 403
chronic, 404
retro-uterine, 406
Parasites of Fallopian tube, 334
and foreign bodies of the ovary, 346
Paratyphlitic exudate, 406
Paratyphlitis differentiated from pelvic cellulitis, 406
Paravaginitis, 229
Parovarian cysts, 330, 371, 378, 385
differentiated from ovarian tumors, 378, 385
from salpingitis, 330

Pawlik method of cystoscopy, 421
Péan's speculum, 74
Pedunculated fibroids and polyps lying within the vagina, 192
Pelvic cellulitis, 402
acute, 403
chronic, 404
classification of, 402
definition of, 402
diagnosis of, differential, 406
differentiated from malignant disease of pelvis, 407
from paratyphlitis, 406
from pelvic hæmatoma, 406
peritonitis, 406
from psoas abscess, 407
from retro-uterine perimetritis, 406
from subserous fibroid, 407
exudate in, consistency of, 405
form of, 405
mobility of, 405
position of, 404
relation of, to neighboring organs, 405
tenderness of, 405
exudate, 139
differentiated from ectopic pregnancy, 139
hæmatocele differentiated from etopic pregnancy, 141
hæmatoma, 406
differentiated from pelvic cellulitis, 406
and hæmatocele, 141
inflammation, acute and subacute, a contraindication to curettage, 88
caused by the sound, 85
peritonitis, 395, 406
acute, 397
adhesions in, peritoneal, 398
chronic, 397
definition of, 395
diagnosis of, clinical, 399
differential, 400
differentiated from pelvic cellulitis, 406
etiology of, 397
exudates in, peritoneal, 398
Pelvimetry, 70
Pelvis, cysts of, echinococcus, 378
malignant disease of, 141, 407
differentiated from ectopic pregnancy, 141
from pelvic cellulitis, 407
Pericæcal abscess, 376
Perimetric exudates, serous, 375
Perimetric exudates, retro-uterine, differentiated from pelvic cellulitis, 406.
Perineum, rupture of, in labor, 112
Periovaritis, tuberculous, 356
Peritoneal adhesions, 398
exudates, 398
Peritoneum, anatomy of, 393
Peritonitis, 393
benign, non-infectious, 394
carcinomatous, 395
diagnosis of, differential, 400
differentiated from ovarian cyst, 401
from retroflexed gravid uterus, 400
from retro-uterine hæmatocele, 400
general, 393
gonorrhœal, 394
pelvic, 395, 406
acute, 397
adhesions in, peritoneal, 398
chronic, 397
definition of, 395
diagnosis of, clinical, 399
differential, 400
differentiated from pelvic cellulitis, 406
etiology of, 397
exudates in, peritoneal, 398
putrid, saprophytic, 394
retro-uterine, 406
septic, 394
tuberculous, 395
Perityphlitis, 354
differentiated from ovaritis, 354
Placenta prævia, 114
premature detachment of, 115
Placental souffle, 109
tissue, retained, 300
Plethora causing uterine hemorrhage, 29
Polypoid endometritis, 241
Polyps of Fallopian tube, 335
Postabortive endometritis, 239
Pozzi's tenaculum forceps, 76
Pregnancy, auscultation of abdomen in, 109
in bicornate uterus, 140
in a bicornate uterus differentiated from ectopic pregnancy, 140
changes in mammary glands in, 104, 113
complicated by ovarian tumors, 390
complicating tubal or ovarian swelling, 139
contraindications to curettage after, 88
diagnosis of, anatomical, 116
discoloration of vagina in, 104

Pregnancy, ectopic, 122
active fœtal movements in, 133
advanced, 377
anatomical changes in, 130
auscultation of abdomen in, 133
bimanual examination in, 137
classification of, 123
decidua of, 301
discharge of, in, 134
diagnosis of, clinical, 132
by curette, 87
differential, 139
differentiated from fibromyoma uteri, 141
from malignant disease of pelvis, 141
from ovarian tumors, 140
from pelvic exudate, 139
hæmatoma and hæmatocele, 141
from pregnancy in a bicornate uterus, 140
in a retroverted uterus, 138
in a rudimentary horn, 140
from uterine pregnancy complicated with tubal or ovarian swelling, 138
discoloration of vagina in, 133
etiology of, 122
genetic reaction in, 122
palpation of abdomen in, 133
retrogressive changes in, 129
suppuration in, 126
endometritis in, 114
extra-uterine, 122
glands of, 300
hemorrhage during, 113
interstitial tubal, 129
irritable bladder in, 104
leucorrhœa in, 106
multiple diagnosis of, 113
nervous phenomena in, 104
ovarian tumors complicating, 390
position of uterus in, 110
in retroverted uterus, 138, 139
retroverted uterus complicating, 138
in a retroverted uterus differentiated from ectopic pregnancy, 138
in rudimentary horn, 140
in a rudimentary horn differentiated from ectopic pregnancy, 140
tubal, 122
abscess formation in, 128
ampullar, 123
Pregnancy, tubal, changes in mammary glands in, 133
infundibular, 129
menstruation in, 133
mole formation in, 128
morning sickness in, 133
nervous phenomena in, 133
pain in, 133
uterine, 276
complicated with tubal and ovarian swellings, 138
diagnosis of, 101
differentiated from fibroids of uterus, 276
Prolapse of urethra, 433
of uterus, 178, 192
of vagina, 180
Prolapsus uteri, 192
with atresia, 186
differentiated from inversion of uterus, 186
from cyst of vagina, 187
Pruritus, 217
Pseudodiphtheritic endometritis, 241
Psoas abscess, 407
differentiated from pelvic cellulitis, 407
Puerperal endometritis, 238
ulcers of vagina, 226
vaginitis, 226
vulvitis, 208
Purpuric conditions causing uterine hemorrhage, 29
Purulent salpingitis, 321, 322
Pus tube, 324
Putrid saprophytic peritonitis, 394
Pyosalpinx, 324

QUADRANTS of bladder, 413

RECTUM, abdomino-rectal, 68
digital examination of, 66
simple rectal touch, 66
traction on uterus in rectal examinations, 69
Retroflexed pregnant uterus, 376
Retroposition of uterus, 173
Retro-uterine fibroids, 202
differentiated from retroversio-flexion of uterus, 203
hæmatocele, 376
hæmatoma and hæmatocele, 202
parametritis, 406
perimetritis differentiated from pelvic cellulitis, 406
peritonitis, 406
Retroversio-flexion of uterus, 195
of uterus differentiated from anteflexion, 202

Retroversio-flexion of uterus, from retro-uterine fibroids, 203
from swellings of tubes and ovaries, 202
Retroverted uterus complicating pregnancy, 138
Rodent ulcers of vulva, 217
Rudimentary uterus, 163

SACTOSALPINX, contents of, 328
diagnosis of, 327
of Fallopian tube, contents of, 328
diagnosis of, 327
purulenta, 324
Salivation, 103
Salpingitis, 354
catarrhal, 319
acute, 315, 319
chronic, 315, 319
of Fallopian tube, 314
chronic, 315
classification of, 314
differentiated from appendicitis, 328
from new formation of tubes, 330
from ovarian cysts, 330
from ovarian tumors, 354
from parametric exudates, 329
from parovarian cysts, 330
from subserous fibroids, 329
of Fallopian tube, diagnosis of, clinical, 319
isthmica nodosa, 316
puerperal, 321, 322
purulent, of Fallopian tube, diagnosis of, clinical, 325
differential, 328
tuberculous, 330
of Fallopian tube, 330
Sarcoma of body of uterus, 307
of cervix, 298, 307
of uterus, 307
vaginal portion, 306
of Fallopian tube, 336
ovarii, 370
of urethra, 436
of uterus, 306, 307
diagnosis of, anatomical, 306
clinical, 308
microscopic, 307
etiology of, 306
of vagina, 231
of vulva, 215
Sarcoma-chorio-cellulare, 160
Sarcomatous degeneration of a fibromyoma, early recognition of, 309
Sebaceous cysts of vulva, 213
Secondary descent and prolapse of uterus, 181
Segregator, 430
Senile endometritis, 32, 239
acute, 248
Septic peritonitis, 394
Sexual excess a cause of sterility, 41
incompatibility a cause of sterility, 41
instinct, its influence upon sterility, 40
Simon's speculum, 73
Sims' duck-bill speculum, 71
position, 63
vaginal depressor, 71
Soft chancre, 208
Sound in examining urethra and bladder, 415
use of, in uterine fibroids, 273
Specimens, mounting of, method of, 97
staining of, method of, 97
Speculum, urethral, introduction of, 429
vaginal, 71
Bozeman's, 72
Curco's, 73, 74
Currier's, 75
Péan's, 74
Simon's, 73
Sims' duck-bill, 71
tubular, 74, 75
Spiegelberg's sign, 303
Splenic tumors, 383
Spurious labor, 134
Squamous-cell carcinoma of uterus, 295
Sterility, 38
alcoholism a cause of, 40
anæmia a cause of, 40
causes of, 40
dyspareunia a cause of, 41
inflammatory diseases causing, 43
influence of sexual instinct on, 40
maldevelopments causing, 41
malformations causing, 41
malpositions causing, 42
new formations causing, 43
obesity a cause of, 40
primary, 39
secondary, 39
sexual excess a cause of, 41
incompatibility a cause of, 41
traumatisms causing, 42
Streptococcus infection of Fallopian tube, 328
Striæ gravidarum, 113
Stricture of urethra, 432
Subinvolution causing uterine hemorrhage, 29
Submucous fibroids, 259
partial inversion, 192
of uterus, 259
and interstitial fibroids, 300
polyps and fibroids in cavity of uterus, 192

Subperitoneal fibroids of uterus, 261
Subperitoneo-abdominal gestation, 124
Subserous fibroid, 261, 329
fibroids of uterus, 261
Supernumerary ovary, 341
Syncytioma malignum following hydatiform mole, 151
of vagina, 234
Syphilis of Fallopian tube, 334
of ovary, 357
Syphilitic ulcers, 216, 217
of cervix, 298
differentiated from carcinoma of vagina, 233
of vagina, 227
vulvitis, 208

TELANGIECTATIC fibroids of uterus, 268
Tents, 80
sea-tangle, 80
sponge, 80
tupelo, 80
Torsion of pedicle of ovarian cysts, 385
of uterus, 177
Traumatisms causing sterility, 42
Trigone, 412
Tubal abortion, 127
pregnancy, 122
abscess formation in, 128
ampullar, 123
infundibular, 129
interstitial, 129
menstruation in, 133
mole formation in, 128
morning sickness in, 133
nervous phenomena in, 133
pain in, 133
Tuberculosis of cervix, 254
of ovary, 356
Tuberculous endometritis, 356
ovaritis, 356
periovaritis, 356
salpingitis, 330
ulcers differentiated from carcinoma of vagina, 233
of cervix, 254, 297
of vagina, 227
of vulva, 217
vaginitis, 227, 233
vulvitis, 208
Tubo-cysts, 318, 355
Tubo-disease, 328
Tubo-ovarian abscess, 351
Tubo-peritoneal gestation, 126
Tumors, adherent, of ovary, 385
connective tissue, of ovary, 369
of Fallopian tube, 334
fatty, differentiated from ovarian tumors, 383
of omentum, 283
of liver, 383
Tumors of liver differentiated from ovarian tumors, 383
of omentum, 378
ovarian, 140, 358
bilateral, 384
complicating pregnancy, 390
development of, intraligamentary, 384
differentiated from allantoic cysts, 384
from ascites, 379
from chylous cysts, 383
from cystic degeneration of ovaries, 375
from distended bladder, 378
from distended gall-bladder, 383
from echinococcus cyst, 378
from ectopic pregnancy, 140
from fatty tumors, 383
from hydronephrosis, 384
from pancreatic cysts, 382
from parovarian cysts, 378, 385
from phantom tumors, 378
from splenic tumors, 383
from tumors of liver, 383
fate of, 391
intraligamentary development of, 384
of ovary, 358
adherent, 385
phantom, of abdominal wall, 378
differentiated from ovarian tumors, 378
splenic, 383
differentiated from ovarian tumors, 383
of urethra, 435
of vulva, 213

ULCERATIVE endometritis, 241
vaginitis, 226
Ulcers, cancerous, of cervix, 254
of cervix, 254
tuberculous, 254, 297
decubitus, 254
syphilitic, 216, 217
of cervix, 298
differentiated from carcinoma of vagina, 233
of vagina, 227
tuberculous, 254
differentiated from carcinoma of vagina, 233
of vagina, decubitus, 227-233
diphtheritic, 227

Ulcers of vagina, puerperal, 226
tuberculous, 227
of vulva, 217
rodent, 217
tuberculous, 217
Ulcus molle of vulva, 208
Unicornate uterus, 166
Urachus cysts, 384
Ureteral orifices, 412
Urethra, absence of, 432
anatomy of 409,
atresia of, 432
carcinoma of, 436
dilatation of, 432
dislocation of, 433
displacements of, 432
examination of, methods of, 413
catheter and sound, 415
cystoscopy, 415
inspection, 415
Kelly-Pawlik, 421
Nitze, 417
palpation, 414
percussion, 413
segregator, 430
urethroscopy, 415
fibroma of, 436
fistulæ of, 436
foreign bodies in, 437
inflammation of, 433
inspection of, 415
malformations of, 432
acquired, 432
congenital, 432
new-growths of, 435
palpation of, 413
partial or complete absence of, 432
physiology of, 409
prolapse of, 433
sarcoma of, 436
stricture of, 432
tumors of, 435
Urethral caruncle, 211
fistulæ, 436
folds, 412
speculum, introduction of, 429
Urethritis, 433
acute, 434
chronic, 435
Urethroscopy, 415
Uterine cavity exposed, 98
contractions, intermittent, 108
curette, 86
contraindications for, 88
dangers involved in, 88
in diagnosis, 86
dilators, 78
Ellinger's 79
Goodell's, 79
Hegar's, 78
displacements, diagnosis of adhesions causing, 174
Uterine fibroids, 375
amyloid degeneration of, 268
atrophy of, 365
calcareous degeneration of, 266
cancerous degeneration of, 268
clinical characteristics of, 268
degeneration of, 265
fatty degeneration of, 267
gangrene of, 268
hemorrhage in, 269
myxomatous degeneration of, 267
pressure and traction from, 270
hemorrhage, anæmia a cause of, 29
endometritis causing, 30
passive congestion causing, 29
plethora causing, 29
purpuric conditions causing, 29
specific infectious diseases causing, 29
subinvolution causing, 29
hydatids, 142
pregnancy, 276
complicated with a tubal and ovarian swelling, 138
diagnosis of, 101
differentiated from fibroids of uterus, 276
segment, lower, softening and compressibility in pregnancy, 106
sound, 83
dangers involved in the use of, 84
indications for the use of, 83
preliminary procedures, 83
tissue, removal of, for diagnostic purposes, 91
Uterus, absence of, 163
accessory, 169
anteflexion of, 194, 202
anteposition of, 173
anteversion of, 193
arterio-sclerosis of, 31
body of, sarcoma of, 307
squamous-cell carcinoma of, 295
broad ligament fibroids of, 273
cancer of, leucorrhœa in, 286
carcinoma of, 279
bimanual palpation in, 289
cachexia in, 286
diagnosis of, anatomical, 281
clinical, 285
differential, 296
extension of, 301
microscopic, 289
recurrence of, 304

Uterus carcinoma of, etiology of, 279
exploration of uterine cavity in, 289
extension of, 301
hemorrhage in, 285
heredity in, 279
leucorrhœa in, 286
pain in, 286
squamous-cell, 295
symptoms, miscellaneous, in, 286
topographical classification, 279
cervix of, sarcoma of, 307
vaginal portion, sarcoma of, 306
descent of, 178
double, 169
elevation of, 176
endothelioma of, 304
fibroids of, 256
differentiated from chronic metritis, 275
from hæmatocele, 277
from hæmatoma, 277
from uterine pregnancy, 276
interstitial, 260
intraligamentary, 273
intramural, 260
submucous, 259
subperitoneal, 261
subserous, 261
suppuration of, 268
telangiectatic, 268
fixation of, pathological, 171
hemorrhage from, 28
hernia of, 203
inspection of, after removal, 99
inversion of, 187
differentiated from prolapsus uteri, 186
lateroposition of, 174
malformation of, 163
malpositions of, 171
membranes expelled from, 120
membranous, 163
mobility of, pathological, 171
perforation of, by curette, 88
by sound, 85
position of, in pregnancy, 110
primary descent and prolapse of, 181
prolapse of, 178
retroflexed gravid, differentiated from peritonitis, 400
retroposition of, 173
retroversio-flexion of, 195
differentiated from anteflexion, 202
from retro-uterine fibroid, 203
Uterus, retroversio-flexion differentiated from swellings of tubes and ovaries, 202
retroverted, complicating pregnancy, 138
rudimentary, 163
sarcoma of, 306, 307
diagnosis of, anatomical, 306
clinical, 308
microscopic, 307
etiology of, 306
test curettage of, 92
torsion of, 177

VAGINA, absence of, 221
atresia of, 221
carcinoma of, 231
chorio-epithelioma malignum of, 234
cysts of, 187, 229
differentiated from prolapsus uteri, 187
decubitus ulcers of, 227, 233
descent of, 180
diagnosis, clinical, of diseases of, 228
digital examination of, 57
discoloration of, in ectopic pregnancy, 133
in pregnancy, 104
displacement of, 179
double, 204, 224
emphysematous, 227
endothelioma of, 234
fibroma of, 231
hæmatocolpos of, 222
hæmatometra of, 222
hæmatosalpinx of, 222
hemorrhage from, 24
laceration of, in labor, 113
maldevelopments of, 221
malformations of, 221
new formations of, 229
prolapse of, 180
sarcoma of, 231
stenosis of, 221
syncytioma of, 234
ulcers of, decubitus, 227–233
diphtheritic, 227
puerperal, 226
syphilitic, 227
tuberculous, 227
Vaginal examination, choice of hand in 59
combined, 59
Vaginitis, 225
catarrhal, 226
condylomatous, 228
puerperal, 226
tuberculous, 227, 233
ulcerative, 226

Villi, dropsy of, 142
Villous endometritis, 240
Vulva, absence of, 204
angioma of, 209
atresia of, 204
atrophy of, 211
cancer of, 214
carcinoma of, 214
circulatory disturbances of, 208
condylomata acuminata of, 209
congenital fissures of, 204
cysts of, 215
dermoid, 214
development of, anomalies in, 204
double, 204
elephantiasis of, 209
enchondroma of, 213
epispadias of, 215
fibroma of, 213
fissures of, congenital, 204
furunculosis of, 206
gangrene of, 205, 209
hæmatoma of, 209
hemorrhage from, 24
Vulva, hypertrophy of, 219
hypospadias of, 205
infantile types of, 204
lipoma of, 213
neuroma of, 213
new formations of, 213
œdema of, 209
sarcoma of, 215
sebaceous cysts of, 213
tumors of, 213
ulcers of, 217
rodent, 217
tuberculous, 217
ulcus molle of, 208
Vulvitis, 206
erysipelatous, 208
furunculosis, 206
puerperal, 208
syphilitic, 208
tuberculous, 208

ZENKER'S fluid, 95

THE LIBRARY OF CONGRESS

THE LIBRARY OF CONGRESS

LIBRARY OF CONGRESS
0 022 216 219 1